

Impact of Different Operative Techniques for Patients With Adolescent Idiopathic Scoliosis on Frontal Curve Correction and Sagittal Balance

Max Prost, Philip Denz, Joachim Windolf and Markus Rafael Konieczny

Int J Spine Surg 2024, 18 (3) 322-328

doi: <https://doi.org/10.14444/8602>

<https://www.ijssurgery.com/content/18/3/322>

This information is current as of July 27, 2024.

Email Alerts Receive free email-alerts when new articles cite this article. Sign up at:
<http://ijssurgery.com/alerts>

Impact of Different Operative Techniques for Patients With Adolescent Idiopathic Scoliosis on Frontal Curve Correction and Sagittal Balance

MAX PROST, MD¹; PHILIP DENZ, MD¹; JOACHIM WINDOLF, Prof.¹; AND MARKUS RAFAEL KONIECZNY, MD^{1,2}

¹Department of Orthopedic and Trauma Surgery, Medical Faculty and University Hospital Düsseldorf, Heinrich-Heine-University Düsseldorf, Düsseldorf, Germany;

²Department of Spine Surgery, Volmarstein Orthopedic Clinic, Volmarstein, Germany

ABSTRACT

Background: Surgical correction of adolescent idiopathic scoliosis from the posterior approach can be performed by the “all screws” technique; hybrid technique with screws and hooks; hybrid technique or with screws, hooks, and tapes; or selective fusion (SF) or nonselective fusion (NSF). The aim of the present investigation was to analyze the influence from different operative techniques on frontal curve correction and sagittal profile in patients with adolescent idiopathic scoliosis.

Methods: We conducted a retrospective analysis on 55 consecutive patients with scoliosis who had been treated by posterior instrumented fusion. We collected demographic data and analyzed pre- and postoperative radiographs. Statistical analysis was performed using SPSS version 25. Because data showed normal distribution, *t* tests were performed.

Results: Twenty-two patients were treated using the hybrid technique with screws and hooks; 25 were treated using the hybrid technique with screws, hooks, and tape; and 8 were treated using the all screws technique. An SF was performed in 32 patients and NSF in 23 patients. There was no significant difference with regard to curve correction of the main curve between the different techniques. Correction of the minor curve was significantly higher in NSF than in SF patients. In SF, there was a correction of the minor curve of 43.9%. Impact on sagittal balance showed no significant differences between NSF and SF.

Conclusion: The different operative techniques did not show a difference with regard to the correction of the main curve. NSF showed a significantly higher degree of correction of the minor curve than SF. However, we still found a correction of 43.9% of the noninstrumented minor curve in SF. Thus, SF and hybrid techniques do not lead to inferior radiographic outcome.

Clinical Relevance: SF and hybrid techniques are safe and effective techniques that could be used as an alternative to NSF and all screw fixation in the operative treatment for scoliosis.

Level of Evidence: 3.

Biomechanics

Keywords: Scoliosis, Selective Fusion, Treatment Strategies, frontal profile, sagittal profile

INTRODUCTION

Adolescent idiopathic scoliosis (AIS) is a deformity of the spine with an incidence of 5%.¹ Depending on the degree of the deformity assessed by the Cobb angle, conservative or operative therapy is recommended.² According to the Lenke classification, scoliotic curves can be classified as structural or nonstructural.^{3,4} Based on this knowledge, the concept of selective fusion (SF) in the surgical treatment of AIS first explained by King et al was refined.⁵ The premise of SF is that after fixation of the primary structural curve, there is spontaneous coronal correction of the unfused nonstructural curve.⁶

The existing data on the correction potential of the unfused nonstructural curve vary widely.⁷ Saramuzzo et al described the stability of the correction and the improvement of clinical outcome scores over a 10-year

follow-up for patients who underwent SF.⁸ Furthermore, investigations have shown that patients who underwent SF show a higher level of postoperative flexibility and movement compared with those who underwent nonselective fusion (NSF).⁹

However, other investigations showed that SF compared with NSF led to a minor correction of the nonstructural curves.^{10,11} According to the subjective perception of the patients, Bizzoca et al showed that although the SF provides better functional outcomes, female patients receiving SF reported a worse perceived body image compared with patients treated with NSF.¹²

Surgical correction from the posterior can be performed by an all screws technique (AS), hybrid technique with screws and hooks (HTH), or hybrid technique with screws, hooks, and tapes (HTHT).^{13–19}

Current data on the correction potential of the different techniques vary widely and are inconclusive. Some

investigations showed that hybrid techniques (HTs) are superior compared with AS techniques with regard to the correction of the frontal and sagittal profile.¹⁴ Other authors reported that the AS technique is better than HT with regard to the correction of the frontal and sagittal profile.^{16,17} Other investigations showed that AS was superior with regard to the correction of the frontal profile and that HT was superior with regard to the correction of the sagittal profile.^{15,18,19} Considering these inconclusive data on SF vs NSF and on AS vs HT, we performed an investigation with a focus on the impact of these operative techniques on frontal curve correction and sagittal balance in patients with AIS.

MATERIALS AND METHODS

The present study was designed as a retrospective single-center data analysis. We identified consecutive patients who were treated surgically for scoliosis in our department between January 2005 and January 2020, in the clinical documentation system by diagnostic code.

We included patients with AIS who underwent surgical treatment by posterior instrumented fusion and had a complete set of data including full spine x-rays in posterior-anterior and lateral view before and after the surgery, at the end of the follow-up, and at a follow-up of at least 24 months. We excluded patients with other types of scoliosis than AIS and those who underwent previous treatment with a growing rod system. Patients with an incomplete set of data or a follow-up of less than 24 months were also excluded. Inclusion and exclusion criteria are summarized in Table 1.

We recorded demographic information data such as sex and age and documented the Lenke classification of the included patients. We assessed if the correction spondylodesis was performed as SF or NSF. Furthermore, we analyzed the performed surgical techniques: AS, HTH, and HTHT. The number of implants for each patient was recorded, and implant density was

calculated. When every pedicle, for example, lamina, was equipped with an implant, the implant density was given as 1.

Only polyaxial screws and lamina hooks were used. When used in the most cranial level, the hooks were always implanted from the cranial approach in the uppermost level on the convex side and from the caudal approach on all other levels. When hooks were used, they were only used in the 2 or up to 4 most cranial segments of the instrumented part of the spine, never at the lowest instrumented vertebra. Sublaminar tapes were only used in the region of the apex of the addressed part of the deformity. Tapes have mostly been applied at the concave side of the deformity, but in some cases (16%; 4/25), they were applied at the convex part as well. Examples of pre- and postoperative full-spine radiographs from patients treated with the different techniques are shown in Figures 1 and 2.

We analyzed the full-spine standing and bending radiographs with the IDS 7-PACS-System (Sectra, Linköping, Sweden).

The Cobb angles of the main curve and of the upper and lower minor curves were measured. We also analyzed the trunk shift in the frontal plane by measuring the distance between the proc spinous of C7 to the central sacral vertical line. End vertebra, stable vertebra, and lowest instrumented vertebra were recorded. The thoracic kyphosis (TK), lumbar lordosis, and pelvic incidence were measured. Some of the performed measurements are shown in Figures 3–5.

Statistical analysis was performed by SPSS 25 (IBM, Armonk, USA). Descriptive data are given as means and SEMs. We tested all continuous variables for normal distribution by Kolmogorov-Smirnov tests. All variables showed normal distribution. Thus, we performed 1-way analysis of variance and *t* tests.

This study was approved by the local ethics committee (Register number 4948) and was conducted according to the revised Declaration of Helsinki.

Table 1. Inclusion and exclusion criteria.

| Criteria | Inclusion | Exclusion |
|----------------|---|--|
| Treatment | Surgical treatment by posterior instrumented fusion | Additional anterior surgical procedure or previous treatment with a growing rod system |
| Scoliosis type | Adolescent idiopathic scoliosis | Nonidiopathic scoliosis (ie, early-onset or neuromuscular) |
| Data set | Complete set of data including full spine x-rays in posterior-anterior and lateral views before and after surgery and at end of follow-up | Incomplete set of data |
| Follow-up | ≥24 months | <24 months |

RESULTS

We identified 241 consecutive patients who were treated surgically for AIS in our institution between January 2002 and January 2020 by diagnostic code. After applying the inclusion and exclusion criteria, we enrolled 55 patients in our investigation. Forty-seven patients were women (85.5%) and 8 were men (14.5%). The mean age at the time of surgery was 14.71 (1.04) years. The curve types of the included patients according to the Lenke classification are shown in Table 2.

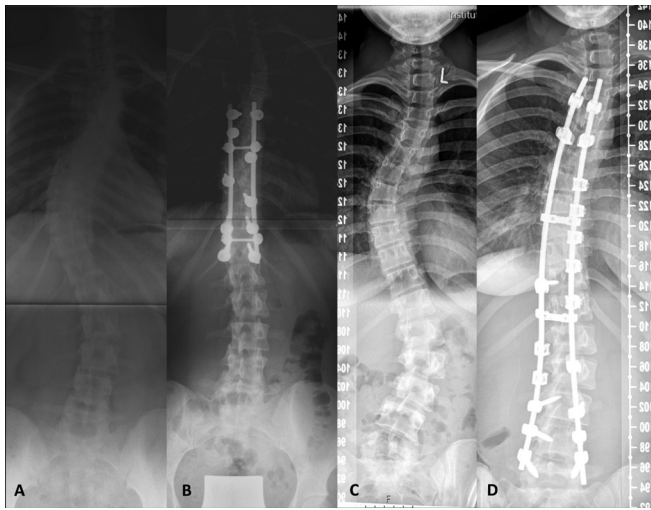


Figure 1. Example full-spine radiographs of a patient treated with selective fusion (A, presurgery and B, postsurgery) and a patient treated with nonselective fusion (C, presurgery and D, postsurgery).

Twenty-two (40.0%) patients were treated by HTH, 25 (45.5%) patients were treated by HTHT, and 8 (14.5%) patients were treated by AS. In 32 patients (58.2%), an SF was performed, and in 23 patients (41.8%), an NSF was performed. Of the 8 patients who underwent AS, 6 were SF cases and 2 were NSF.

The implant density in patients treated by AS technique was 0.90 (0.10), by HTH technique was 0.69 (0.13), and by HTHT technique was 0.80 (0.09). Only the difference in implant density between the AS

technique and the HTH technique showed significance ($P < 0.05$).

Table 3 shows the Cobb angles of the main and minor curves in the pre- and postoperative radiographs as well as the correction of the Cobb angle that was achieved by the different techniques.

The difference with regard to the correction of the main curve between HTH, HTHT, and AS as well as for NSF and SF was not significant ($P > 0.05$). Correction of the minor curve was significantly higher in NSF than in SF ($P < 0.05$). In SF, there was a correction of the (noninstrumented) minor curve of 15.1° (1.60°), which means a correction of 43.9% on average.

Table 4 shows the difference between lumbar lordosis and pelvic incidence before and after surgery for the different techniques. The correction of the sagittal balance showed no significant differences between NSF and SF ($P > 0.05$).

The average difference between the Cobb angle of the main curve in the preoperative radiographs and the preoperative bending was 24.06° (10.63°) and between the Cobb angle of the main curve in the pre and postoperative radiographs was 30.33° (10.76°). This difference showed a highly significant correlation ($P < 0.001$; correlation coefficient 0.484).

There were no significant changes of these parameters during the median follow-up of 36.61 (5.19) months. During this follow-up, none of the patients in the SF or NSF subgroups had a documented case of proximal or

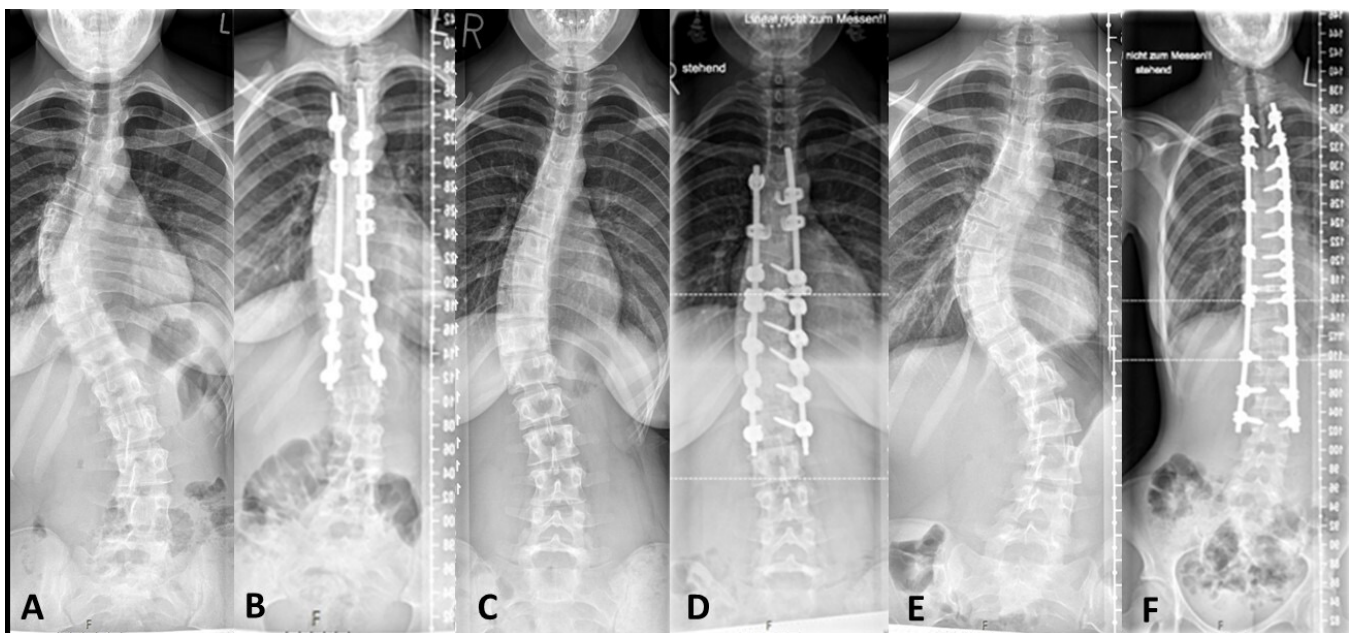


Figure 2. Example full-spine radiographs of a patient treated with hybrid-technique with screws, hooks, and tapes (A, presurgery and B, postsurgery); a patient treated with hybrid-technique with screws and hooks (C, presurgery and D, postsurgery); and a patient treated with all-screw technique (E, presurgery and F, postsurgery).

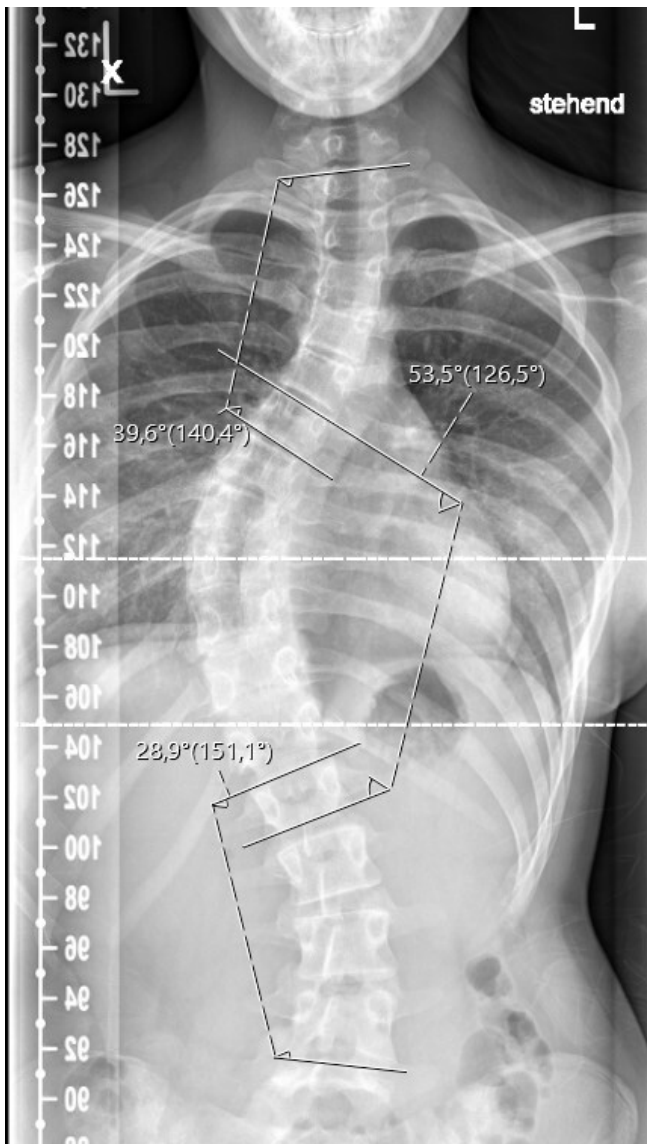


Figure 3. Measurement of the Cobb angle from the main curve and the upper and lower minor curve in a posterior-anterior view of a full-spine radiograph.

distal junction kyphosis. No patient required revision surgery.

DISCUSSION

In this investigation, we analyzed the data of 55 patients to investigate the impact of SF and NSF as well as AS, HTH, and HTHT techniques on frontal curve correction and sagittal balance in patients with AIS.

The demographic data of our group of patients with an average age of 14.71 years and a female predominance, as well as the average preoperative Cobb angles and curve types, are comparable to data reported in other recent investigations.⁸⁻¹⁹ This seems to indicate that our study population may be representative.

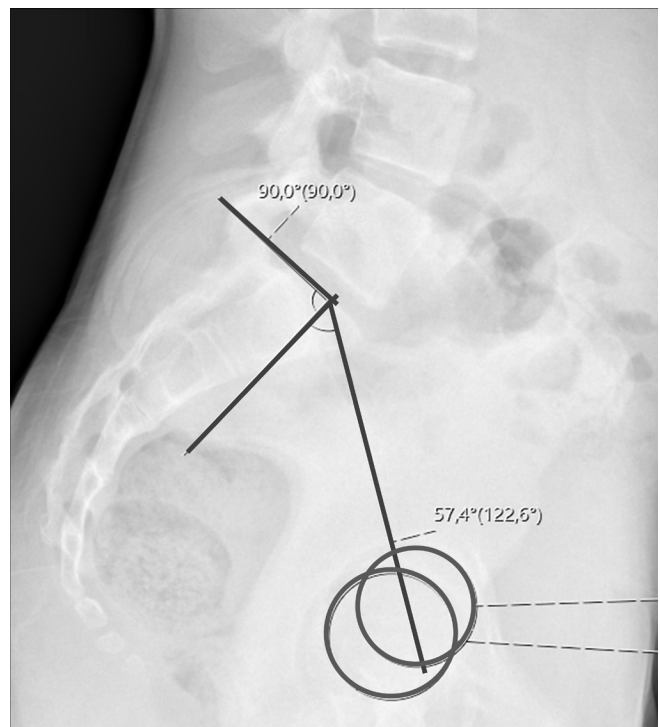


Figure 4. Measurement of the pelvic incidence in a lateral lumbar spine radiograph.

In our group of patients, the HT and the AS techniques did not show a difference that was significant with regard to the correction of the main curve. This result is comparable to the results from Tsirikos and McMillan, who reported that HT leads to comparable results with regard to the correction of the frontal profile and a superior correction of TK and of the sagittal balance than the AS technique.¹⁴ An advantage of our investigation over the results of Tsirikos and McMillan is that we analyzed the impact of the different techniques on patients with different curve types according to the Lenke classification.

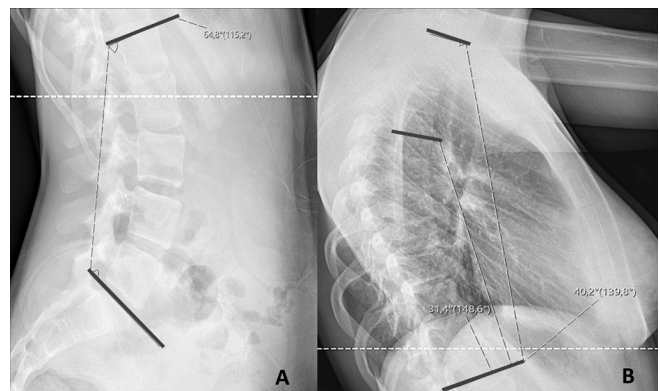


Figure 5. Measurement of parameters from the sagittal profile. (A) Measurement of the lumbar lordosis between L1 and S1 in a lateral lumbar spine radiograph. (B) Measurement of the thoracic kyphosis between T1 and T12 as well as between T5 and Th12 in a lateral thoracic spine radiograph.

Table 2. Lenke classification of included patients (N = 55).

| Type of Curve | n | % |
|---------------|----|------|
| 1 | 21 | 38.2 |
| 2 | 21 | 38.2 |
| 3 | 2 | 3.6 |
| 4 | 3 | 5.5 |
| 5 | 7 | 12.7 |
| 6 | 1 | 1.8 |

However, there are also recent investigations that show different results compared with our investigation. Ruiz et al showed in their retrospective analysis that in their group of patients, HT led to less curve correction in the frontal than AS.¹⁶ However, they included patients who underwent all hooks instrumentation without any screw instrumentation. There are already data that show that the hooks-only technique leads to a poorer outcome than the modern HT or AS techniques.^{20,21}

Luo et al stated that compared with HT, AS provides better coronal correction but less TK restoration, with a decreased incidence of overall complications and reoperations in AIS patients.¹⁸ In our group of patients, we did not observe the reported higher rate of complications and reoperations in patients who were treated with HT instead of AS.

A further parameter that has to be mentioned is that the AS technique leads to a higher cost per fused level and per degree of correction compared with HT.²² This fact may have been caused by the higher implant density in cases treated with AS technique compared with the HT technique. Comparable to existent data, in our group of patients, the NSF showed a significantly higher correction of the minor curve than SF.¹⁰ However, we still

Table 4. Difference between preoperative and postoperative LL and PI for the different techniques.

| Technique | Preoperative | Postoperative | Pre- and Postoperative |
|-----------|--------------|---------------|------------------------|
| All | | | |
| Mean | 5.8073 | 4.1262 | 1.3875 |
| SEM | 1.94256 | 2.39210 | 2.46151 |
| NSF | | | |
| Mean | 6.54 | 0.36 | 6.18 |
| SEM | 3.25 | 3.78 | 3.34 |
| SF | | | |
| Mean | 5.47 | 5.81 | -0.92 |
| SEM | 1.83 | 2.39 | 2.56 |

Abbreviations: LL, lumbar lordosis; PI, pelvic incidence.

found a correction of 43.9% of the noninstrumented minor curve in SF. Furthermore, the impact on sagittal balance showed no significant differences between NSF and SF in our group of patients. Considering SF does lead to a lower rate of complications because less segments are instrumented, we believe that SF is a good and safe alternative for selected patients.

A correction of the Cobb angle in the frontal plane that exceeds the degree of correction that is achieved by bending radiographs may lead to loss of balance and negative impact on the not instrumented minor curves.²³ In our group of patients, we found a significant correlation between the preoperative bending radiographs and the surgically achieved correction.

A limitation of our investigation is that we performed a retrospective data analysis. However, due to standard operating procedures in our department for the surgical treatment of AIS, the treatment of the patients is comparable.

Table 3. Cobb angles of the main and minor curve in the pre- and postoperative radiographs and the perioperative correction of the Cobb angle by the different techniques.

| Technique | Preoperative Cobb Angle, ° | | Postoperative Cobb Angle, ° | | Correction of Cobb Angle, ° (%) | |
|-----------|----------------------------|-------------|-----------------------------|-------------|---------------------------------|--------------|
| | Main Curve | Minor Curve | Main Curve | Minor Curve | Main Curve | Minor Curve |
| All | | | | | | |
| Mean | 57.26 | 42.23 | 27.95 | 22.20 | 30.33 (52.9) | 20.03 (47.4) |
| SEM | 1.81 | 1.81 | 1.60 | 1.49 | 1.45 | 1.74 |
| SF | | | | | | |
| Mean | 55.50 | 34.36 | 27.43 | 22.93 | 27.53 (49.6) | 15.10 (43.9) |
| SEM | 2.15 | 1.50 | 1.83 | 1.90 | 1.61 | 1.60 |
| NSF | | | | | | |
| Mean | 59.72 | 43.99 | 28.37 | 21.18 | 31.35 (52.3) | 26.90 (61.2) |
| SEM | 3.00 | 3.47 | 2.68 | 2.34 | 2.36 | 2.92 |
| HTH | | | | | | |
| Mean | 61.57 | 44.00 | 28.57 | 20.12 | 33.00 (53.6) | 25.94 (59.0) |
| SEM | 3.18 | 3.55 | 2.87 | 2.38 | 2.41 | 3.36 |
| HTHT | | | | | | |
| Mean | 53.37 | 33.52 | 26.46 | 22.63 | 26.22 (48.9) | 16.58 (49.5) |
| SEM | 1.86 | 1.83 | 1.72 | 1.87 | 1.66 | 1.65 |
| AS | | | | | | |
| Mean | 57.59 | 38.15 | 30.05 | 26.58 | 27.54 (47.8) | 14.58 (38.2) |
| SEM | 5.46 | 2.62 | 4.48 | 4.74 | 3.36 | 2.89 |

Abbreviations: AS, all screws technique; HTH, hybrid technique with screws and hooks; HTHT, hybrid technique with screws, hooks, and tapes; NSF, nonselective fusion; SF, selective fusion.

CONCLUSION

The HTs and AS did not show a difference that was significant with regard to the correction of the main curve in our group of patients. NSF showed a significantly higher degree of correction of the minor curve than SF. However, we still found a correction of 43.9% of the noninstrumented minor curve in SF. This seems to show that SF and HTs do not lead to worse radiographic outcomes than NSF and AS in carefully selected patients.

ACKNOWLEDGMENTS

The included patients were treated in different departments of the university hospital Duesseldorf inter alia from 2002 up to July 2019 in the Department for Orthopedic Surgery (Dr. Krauspe) and since August 2019 in the Department of Orthopedic and Trauma Surgery (Dr. Windolf). Some of the results published in this work were part of the PhD thesis from Philip Denz. In partial fulfillment of the requirements for a PhD thesis for Philip Denz.

REFERENCES

- Konieczny MR, Senyurt H, Krauspe R. Epidemiology of adolescent idiopathic scoliosis. *J Child Orthop*. 2013;7(1):3–9. doi:10.1007/s11832-012-0457-4
- Trobisch P, Suess O, Schwab F. Idiopathic scoliosis. *Dtsch Arztebl Int*. 2010;107(49):875–883. doi:10.3238/arztebl.2010.0875
- Lenke LG, Betz RR, Haheer TR, et al. Multisurgeon assessment of surgical decision-making in adolescent idiopathic scoliosis: curve classification, operative approach, and fusion levels. *Spine*. 2001;26(21):2347–2353. doi:10.1097/00007632-200111010-00011
- Lenke LG, Betz RR, Harms J, et al. Adolescent idiopathic scoliosis: a new classification to determine extent of spinal arthrodesis. *J Bone Joint Surg Am*. 2001;83(8):1169–1181.
- King HA, Moe JH, Bradford DS, Winter RB. The selection of fusion levels in thoracic idiopathic scoliosis. *J Bone Joint Surg Am*. 1983;65(9):1302–1313.
- Lenke LG, Betz RR, Bridwell KH, Harms J, Clements DH, Lowe TG. Spontaneous lumbar curve coronal correction after selective anterior or posterior thoracic fusion in adolescent idiopathic scoliosis. *Spine*. 1999;24(16):1663–1671. doi:10.1097/00007632-199908150-00007
- Eardley-Harris N, Munn Z, Cundy PJ, Gieroba TJ. The effectiveness of selective thoracic fusion for treating adolescent idiopathic scoliosis: a systematic review protocol. *JBI Database System Rev Implement Rep*. 2015;13(11):4–16. doi:10.11124/jbisrir-2015-2338
- Scaramuzzo L, Giudici F, Bongetta D, Caboni E, Minoia L, Zagra A. Thoraco-lumbar selective fusion in adolescent idiopathic scoliosis with lenke C modifier curves: clinical and radiographic analysis at 10-year follow-up. *Eur Spine J*. 2017;26(Suppl 4):514–523. doi:10.1007/s00586-017-5152-1
- Lark RK, Yaszay B, Bastrom TP, Newton PO. Adding thoracic fusion levels in lenke 5 curves: risks and benefits. *Spine*. 2013;38(2):195–200. doi:10.1097/BRS.0b013e3182634c85
- Boniello AJ, Hasan S, Yang S, Jalai CM, Worley N, Passias PG. Selective versus nonselective thoracic fusion in lenke 1C curves: a meta-analysis of baseline characteristics and postoperative outcomes. *J Neurosurg Spine*. 2015;23(6):721–730. doi:10.3171/2015.1.SPINE141020
- Demura S, Yaszay B, Bastrom TP, Carreau J, Newton PO. Is decompression preoperatively a risk in lenke 1C curves? *Spine*. 2013;38(11):E649–E655. doi:10.1097/BRS.0b013e31828cb2a3
- Bizzoca D, Piazzolla A, Solarino G, Moretti L, Moretti B. Subjective perception of spinal deformity after selective versus non-selective fusion of lenke 1C curves. *Spine Deform*. 2022;10(4):855–863. doi:10.1007/s43390-022-00479-8
- Yaman O, Dalbayrak S. Idiopathic scoliosis. *Turk Neurosurg*. 2014;24(5):646–657. doi:10.5137/1019-5149.JTN.8838-13.0
- Tsirikos AI, McMillan TE. All Pedicle screw versus hybrid hook-screw instrumentation in the treatment of thoracic adolescent idiopathic scoliosis (AIS): a prospective comparative cohort study. *Healthcare*. 2022;10(8):1455. doi:10.3390/healthcare10081455
- Di Silvestre M, Bakaloudis G, Lolli F, Vommaro F, Martikos K, Parisini P. Posterior fusion only for thoracic adolescent idiopathic scoliosis of more than 80 degrees: pedicle screws versus hybrid instrumentation. *Eur Spine J*. 2008;17(10):1336–1349. doi:10.1007/s00586-008-0731-9
- Ruiz JNM, Kandwal P, Lau LL, Liu GKP, Thambiah J, Wong HK. Selective thoracic fusion for idiopathic scoliosis: a comparison of three surgical techniques with minimum 5-year follow-up. *Spine*. 2022;47(7):E272–E282. doi:10.1097/BRS.0000000000004250
- Kim YJ, Lenke LG, Kim J, et al. Comparative analysis of pedicle screw versus hybrid instrumentation in posterior spinal fusion of adolescent idiopathic scoliosis. *Spine*. 2006;31(3):291–298. doi:10.1097/01.brs.0000197865.20803.d4
- Luo M, Li N, Shen M, Xia L. Pedicle screw versus hybrid instrumentation in adolescent idiopathic scoliosis: a systematic review and meta-analysis with emphasis on complications and Reoperations. *Medicine*. 2017;96(27):e7337. doi:10.1097/MD.00000000000007337
- Crawford AH, Lykissas MG, Gao X, Eismann E, Anadio J. All-pedicle screw versus hybrid instrumentation in adolescent idiopathic scoliosis surgery: a comparative radiographical study with a minimum 2-year follow-up. *Spine*. 2013;38(14):1199–1208. doi:10.1097/BRS.0b013e31828ce597
- Bullmann V, Liljenqvist UR, Schmidt C, Schulte TL. Dorsale operative korrektur der idiopathischen skoliose: stellenwert von pedikelschrauben vs. haken. *Orthopade*. 2009;38(2):198–200. doi:10.1007/s00132-008-1370-x
- Yilmaz G, Borkhuu B, Dhawale AA, et al. Comparative analysis of hook, hybrid, and pedicle screw instrumentation in the posterior treatment of adolescent idiopathic scoliosis. *J Pediatr Orthop*. 2012;32(5):490–499. doi:10.1097/BPO.0b013e318250c629
- Jaquith BP, Chase A, Flinn P, et al. Screws versus hooks: implant cost and deformity correction in adolescent idiopathic scoliosis. *J Child Orthop*. 2012;6(2):137–143. doi:10.1007/s11832-012-0400-8
- Dobbs MB, Lenke LG, Walton T, et al. Can we predict the ultimate lumbar curve in adolescent idiopathic scoliosis patients undergoing a selective fusion with undercorrection of the thoracic curve. *Spine*. 2004;29(3):277–285. doi:10.1097/01.brs.0000106488.51299.75

Funding: No benefits in any form have been received or will be received from a commercial party related directly or indirectly to the subject of this article.

Declaration of Conflicting Interests: M.R.K. reports paid lectures for Globus Medical and Depuy Synthes. The other authors declare no conflict of interest relevant to this work.

Ethics Approval: This study was approved by the local ethics committee (Register number 4948) and was conducted according to the revised Declaration of Helsinki.

Data availability statement: The data sets generated during and/or analyzed during the current study are not publicly available due data protection

but are available from the corresponding author upon reasonable request.

Corresponding Author: Max Prost, Department of Orthopedic and Trauma Surgery, University Hospital Duesseldorf, Moorenstraße 5, 40225 Duesseldorf, Moorenstraße, Germany; Max.prost@med.uni-duesseldorf.de

Published 05 June 2024

This manuscript is generously published free of charge by ISASS, the International Society for the Advancement of Spine Surgery. Copyright © 2024 ISASS. To see more or order reprints or permissions, see <http://ijssurgery.com>.