

Management of Spinal Langerhans Cell Histiocytosis in Children: A Systematic Review

Macherla Haribabu Subramaniam, Victor Moirangthem and Muralidharan Venkatesan

Int J Spine Surg 2024, 18 (6) 769-780

doi: <https://doi.org/10.14444/8662>

<https://www.ijssurgery.com/content/18/6/769>

This information is current as of January 2, 2025.

Email Alerts Receive free email-alerts when new articles cite this article. Sign up at:
<http://ijssurgery.com/alerts>

Management of Spinal Langerhans Cell Histiocytosis in Children: A Systematic Review

MACHERLA HARIBABU SUBRAMANIAM, DNB¹; VICTOR MOIRANGTHEM, MS²; AND
MURALIDHARAN VENKATESAN, MCH¹

¹Department of Spine Surgery, Apollo Speciality Hospital, Perungudi, Chennai, Tamil Nadu, India; ²Department of Orthopaedics, Regional Institute of Medical Sciences, Imphal, Manipur, India

 MHS, 0000-0002-6524-7659

ABSTRACT

Background: Spinal Langerhans cell histiocytosis can manifest as solitary site unifocal form or as systemic form in children. The management options for solitary spinal site unifocal form are many. They include spontaneous resolution of the lesion and supervised treatment, steroid injection of the lesion, systemic chemotherapy, radiation therapy and surgery. Multiple options create a decision-making dilemma for the treating specialist. The authors sought to formulate a management algorithm of spinal Langerhans cell histiocytosis based on Garg's grading of radiographic vertebral body collapse.

Materials and Methods: The Preferred Reporting Items for Systematic Reviews and Meta-Analyses-2020 guidelines were followed in conducting the review and studies were filtered from established medical databases. Articles published between 2003 and 2022 were included after applying strict inclusion and exclusion criteria. The first and second authors reviewed the abstracts of filtered studies before including them. The study was registered with Prospero. The bias assessment of included studies was assessed using the MINOR's criteria.

Results: Eight retrospective case series were analyzed. Within these studies, a total of 116 children (mean age 7.4 years) had undergone treatment. The mean follow-up period was 52.1 months. Among these patients, there were 37 tumors in the cervical spine, 40 in the thoracic spine, 25 in the lumbar spine, and a single tumor in the sacrum. Systemic chemotherapy has been found to reduce the risk of radiographic vertebral body collapse ($p < 0.05$). Surgery provides optimal outcomes in patients with Garg's grade IB, II spinal tumors and restores vertebral body height ($p < 0.05$). No case series were found pertaining to grade III. Reconstitution of vertebral body height, an important radiological parameter indicating the endpoint or healing of the lesion, was early achieved with surgery followed by systemic chemotherapy, bracing, and supervised management.

Conclusion: Observation can be preferred in Garg's grade IA. Grade IB and II tumors respond well to surgery. Treatment for grade III tumors needs to be tailored on an individual basis.

Grade of Recommendation: C.

Article

Keywords: back pain, spine, children, spinal tumor, histiocytosis X

KEY POINTS

- Pediatric spinal LCH can be managed following Garg's classification of radiographic vertebral body collapse.
- Symptomatic Garg's grade IA spinal LCH may respond to observation. Surgery is ideal in symptomatic Garg's grading IB and II lesions. Management needs to be tailored according to the individual patient in Garg's grade III.
- Biopsy-proven asymptomatic vertebral body collapse of spinal LCH can be managed with observation and proper follow-up.
- Systemic chemotherapy has been found to reduce the risk of progressive radiographic vertebral body collapse in spinal LCH ($P < 0.05$).

INTRODUCTION

The incidence and prevalence of Langerhans cell histiocytosis (LCH) in children are reported to be approximately 4.4 and 9.9 per million children.¹ LCH can occur as a unifocal form at a single spinal site or as a part of a systemic form in children. The systemic form of LCH predominates in infants while the solitary-unifocal form predominates in children older than 1 year. Bone and skin are the commonly involved unifocal sites in children at the time of diagnosis.² The progression of these lesions can vary from spontaneous resolution to a fulminant course with multiple organ dysfunctions. The mortality rate of patients with LCH and organ dysfunction has been reported to be 20% and the disease re-activation rate to be 30% following proper first-line treatment.³

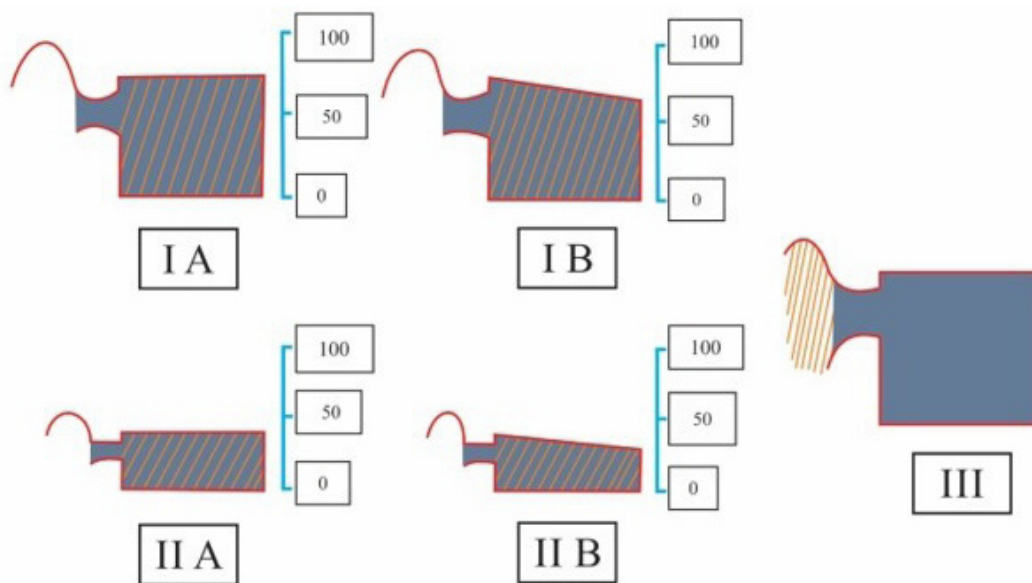


Figure 1. Garg's grading of radiographic collapse of the vertebral body.

Management guidelines of spinal LCH in children clearly recommend local treatment for the solitary-unifocal form and systemic chemotherapy for the systemic form of the disease.⁴ The management goals of solitary-unifocal spinal LCH in children are to relieve symptoms, maintain spinal stability, improve neurological symptoms, prevent secondary deformity and shorten the disease course.⁵ Standard care includes the wait-and-watch approach for spontaneous resolution of the lesion, steroid injection of the lesion, radiation therapy, chemotherapy and surgery.⁵⁻⁷ When to use these modalities in children of growing age is imprecise and obscure to the treating specialist; when to switch over from one treatment modality to the other and when to intervene surgically if required are unclear as the management includes multi-interdisciplinary care involving pediatric-neonatologist, medical oncologist, and a spine surgeon.⁶

Garg et al⁷ had classified radiographic collapse of the vertebral body in his study of pediatric spinal LCH into 3 grades. Grade I is 0% to 50% and grade II is 51% to 100% of vertebral body collapse. Grade I and II are further subdivided into "A" as symmetrical collapse and "B" as asymmetrical collapse. Grade III is assigned if there is involvement of posterior elements of the spine (Figure 1).

We hypothesized that we can identify an ideal option of treatment modality based on Garg's grading of radiographic vertebral body collapse and formulate a management algorithm for solitary-unifocal spinal LCH in children younger than 15 years to aid in treatment planning by the managing specialist.

MATERIALS AND METHODS

Search Strategy and Inclusion Criteria

The medical databases PubMed, Ovid Medline, and Science Direct were searched using the keywords "spine" and "histiocytosis," "spine" and "eosinophilic granuloma," "spine" and "Letterer-Siwe disease" and their combination MeSH terms. The systematic review was carried out following Preferred Reporting Items for Systematic Reviews and Meta-Analyses-2020⁸ guidelines. Articles published in English over the past 20 years, from 2003 to 2022 were included. Systematic reviews, meta-analyses, case reports, expert comments, non-spine studies, studies involving children older than 15 years, studies involving adults, studies with fewer than 5 children and studies with a follow-up period of less than a year were excluded. The study was registered with Prospero (reference number: CRD42023424328) and an institutional review board approval waiver was obtained. The first and second authors (M.H.S. and V.M.) reviewed the abstracts of all identified studies before including them in the systematic review. There was no disagreement between the 2 authors in the inclusion of the studies (Figure 2).

Extraction of Data

All the included studies were evaluated for the first author, the country where the study was conducted, the type of study, the number of children in the series, the mean age of the included children, spinal location of LCH, clinicoradiological presentation of the patients,

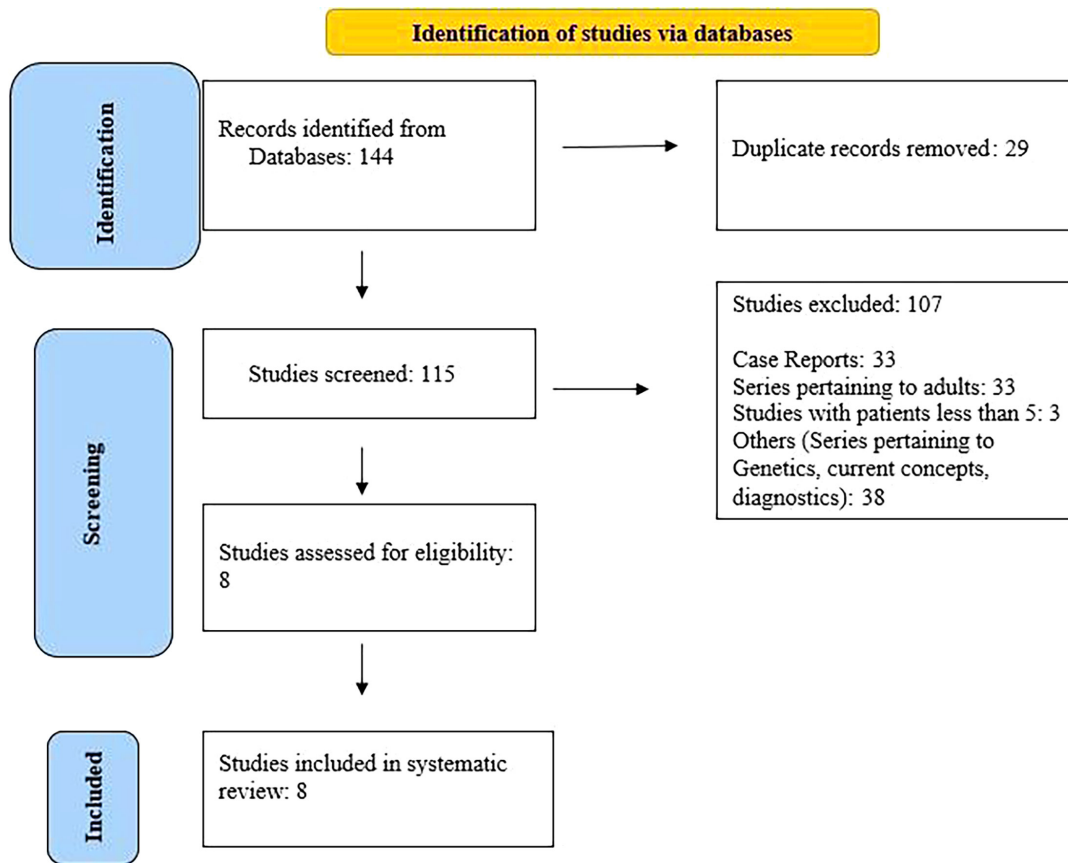


Figure 2. Literature search as per Preferred Reporting Items for Systematic Reviews and Meta-Analyses-2020 guidelines.

Garg’s grading of LCH, the treatment modalities documented in the series, the mean years of follow-up, the conclusion and the salient findings documented in the series. All of the data were entered into a Microsoft Excel sheet (Microsoft Corporation, USA).

Assessment of Quality of Included Studies

The assessment bias of the included studies was assessed using the MINORS (methodological index for non-randomized studies⁹) criteria (Table 1).

Table 1. Assessment of bias among included studies—MINORS’ criteria.

Items	Peng et al, 2009 ¹⁰	Jiang et al, 2011 ¹¹	Abdelaal et al, 2020 ¹²	Nakamura et al, 2019 ¹³	Zhou et al, 2017 ¹⁴	Zheng et al, 2022 ¹⁵	Zheng et al, 2022 ¹⁶	Zhong et al, 2016 ¹⁷
A clearly stated aim	2	2	2	2	2	2	2	2
Inclusion of consecutive patients	2	2	2	2	2	2	2	2
Prospective collection of data	2	2	2	2	2	2	2	2
Endpoints appropriate to the aim of the study	2	2	2	2	2	2	2	2
Unbiased assessment of the study endpoint	2	1	2	2	2	2	2	2
Follow-up period appropriate to the aim of the study	2	1	2	2	2	2	2	2
Loss of follow-up less than 5%	2	2	2	2	2	2	2	2
Prospective calculation of study size	0	0	0	0	0	0	0	0
An adequate control group	0	0	0	0	0	2	0	0
Contemporary groups	0	0	0	0	0	0	0	0
Baseline equivalence of groups	0	0	0	0	0	0	0	0
Adequate statistical analysis	1	1	1	1	1	2	2	1
Total	15	13	15	15	13	18	16	15
Risk	Low	Low	Low	Low	Low	Low	Low	Low

Abbreviation: MINORS, methodological index for non-randomized studies.
 Note: 2 (green) is considered good, 1 (yellow) is considered moderate, and 0 (red) is no score.

Table 2. The demographic characteristics of the patient population of the included studies.

Authors	No. of Patients	Mean Age	Mean Follow-Up	Site of Involvement	Clinical and Radiological Presentation
Peng et al ¹⁰	9	7.7 y	30.3 mo	Cervical—2 Thoracic—5 Lumbar—1 Sacral—1	8 patients (88.9%) patients had neurological symptoms
Jiang et al ¹¹	5	18 y	7.2 y	Multiple sites	Neck pain and low back pain 2 patients had neurological symptoms
Abdelaal et al ¹²	12—solitary site 3—multifocal sites	Not provided	49 mo	Cervical—5 Thoracic—8 Lumbar—4	Anterior wedging: 2 Vertebra plana picture:13
Nakamura et al ¹³	5—solitary site 8—multifocal sites	3.6 y	10.2 y	Cervical—3 Thoracic—3 T-L junction—2 Lumbar—5	Not provided
Zhou et al ¹⁴	31 (23 —solitary spinal site; 8—multifocal skeletal sites)	8.8 ± 2.8 y	2.9 ± 1.1 y	Cervical—8 Thoracic—11 Lumbar—4	Back pain or neck pain according to the location of the tumor Neurological symptoms: 8 patients Local kyphosis: 4 patients Vertebral collapse more than 50%
Zheng et al ¹⁵	9 patients	66.7 mo	26.7 mo	Thoracic—4 Lumbar—5	Vertebral collapse more than 50%
Zheng et al ¹⁶	15 patients	74.3 ± 38.8 mo	2.9 y	Thoracic—9 Lumbar—6	1. Vertebral collapse more than 50% 2. Asymmetrical destruction of vertebral body with collapse less than 50%
Zhong et al ¹⁷	19 patients	9.9 ± 3.1 y	36.4 ± 13.7 mo	C1—C2: 7 patients C3—C7: 12 patients	1. Neck movements restriction 2. Neck pain 3. Neurological symptoms 4. Torticollis

RESULTS

Of the 144 studies identified, 8 studies were eligible for analysis. All 8 studies were retrospective. Among them, 7 were from Asia and 1 was from African continent. Within these 8 studies, 116 children had undergone treatment. The mean age of the patients was 7.4 years in the group (one study¹² was excluded because age was not mentioned). The mean follow-up period was 52.1 months. A single study¹¹ had focused on pediatric LCH at multiple spinal sites (multifocal involvement), and the remaining 7 studies^{10,12–17} were pertained to the solitary spinal-unifocal pediatric LCH. There were 37 tumors in the cervical spine, 40 tumors in the thoracic spine, 25 tumors in the lumbar spine, and a single tumor in the sacrum among the included children. Twenty-four children had multiple spinal sites involved in the group. All the children in the 8 studies had biopsy-proven LCH. The demographic characteristics of the patient populations are provided in Table 2.

The treatment modalities used in the studies relevant to Garg's classification and salient findings of the studies are reported in Table 3.

The systematic review revealed that the treatment modalities nonoperative treatment—supervised management with bracing, systemic chemotherapy,

radiation treatment and surgery to have definite roles in the management of spinal LCH in children.

Nonoperative Treatment— Supervised Management With Bracing

In their series, Abdelaal et al¹² treated 15 children with spinal LCH using supervised management and bracing. The authors reported that partial restoration of vertebral body height of up to 50% was accomplished in 10 of their patients (66.6%) at a mean follow-up of 49 months. Two of the patients in their series had died from the disease at a mean follow-up of 27 months; these 2 children had persistent collapse of the vertebral body at their last follow-up without much improvement. Nakamura et al,¹³ in a series of 13 patients, evaluated the reconstitution of vertebral body height (ROVE) following nonoperative treatment of spinal LCH in their series. The authors suggested that the vertebral body remains in the collapse phase for up to 2 years from the time of presentation and the reconstitution phase starts with an increase in the height of the anterior vertebral wall by a mean period of 2 years. However, the entire vertebral body height was not restored completely by a mean period of 7 years of follow-up in all the children who had undergone nonoperative treatment in the series,

Table 3. The treatment modalities used in the studies relevant to Garg's classification and salient findings of the studies.

Authors	Garg's Classification	Treatment Modality	Assessed Outcome Parameters	Conclusion and Salient Findings
Peng et al ¹⁰	Unclear about grades I or II; A: 3 patients; B: 5 patients; III: 1 patient	Chemotherapy: 8 patients; Chemotherapy + surgery: 1 patient	At last follow-up, MRI images revealed disappearance of soft tissue shadow.	Chemotherapy is safe and effective. Surgery is indicated for spinal instability or with severe neurological deficit.
Jiang L et al ¹¹	Not provided	Chemotherapy + local radiotherapy: 1 (case 1) Radiotherapy: 2 (cases 2 and 5) Surgery: 1 (case 3) radiotherapy + surgery: 1 (case 4)	Clinical symptoms resolved at last follow-up.	Chemotherapy is highly effective. Surgery in lesions causing neurology which are not amenable to chemotherapy or radiotherapy.
Abdelaal et al ¹²	Unclear	Nonoperative treatment: 11 Surgery: 2 Died: 2 (by mean 27 months on nonoperative treatment)	Vertebral body height restoration.	Nonoperative treatment yields results. Surgery is indicated when the lesion is in cervical spine.
Nakamura et al ¹³	Not provided	Brace: 9 patients, of which 8 patients had systemic chemotherapy + brace Supervised management: 4 patients	Anterior, posterior vertebral wall height restoration.	Vertebral body height restoration occurs eventually with treatment. It can be assessed by measuring the height of anterior, posterior vertebral body wall height.
Zhou et al ¹⁴	Not provided	Surgery only: 6 Surgery + radiation therapy: 9 Surgery + chemotherapy: 4 Surgery + radiotherapy + chemotherapy: 4 Radiotherapy: 5 Chemotherapy: 1 Radiotherapy + chemotherapy: 2	Local pain relief and neurological improvement following surgery.	Surgery followed by postoperative low-dose radiation therapy or chemotherapy provides prompt local pain relief and early neurological improvement when compared with isolated radiation therapy or chemotherapy alone.
Zheng et al ¹⁵	Grade II	Transpedicular curettage + short segment posterior instrumentation, balloon kyphoplasty, calcium sulfate cement injection	Better vertebral height restoration by 2-y follow-up when compared with historical cohort.	Active surgical treatment is recommended in patients with grade II lesions.
Zheng et al ¹⁶	Grade IB and II	Transpedicular curettage + short segment posterior instrumentation, Instrumentation removal by 2 y	Better vertebral body height restoration by 1-y follow-up when compared with reference vertebral body height.	Active surgical treatment is recommended in patients with grade IB, II lesions to restore vertebral body height and spinal stability.
Zhong et al ¹⁷	Not provided	C1–C2: Anterior resection of lesion and posterior instrumentation C3–C7: Vertebral body lesion: anterior excision, corpectomy, and fusion Posterior column lesion: posterior excision and instrumentation	Improvement in neurology and clinical symptoms.	Surgery can significantly improve neurological symptoms. However, it must be tailored according to the individual location of the lesion in cervical spine.

Abbreviation: MRI, magnetic resonance imaging.

with or without bracing. Both series^{12,13} did not mention Garg's classification in their articles.

Systemic Chemotherapy

In the report by Nakamura et al,¹³ 8 children received systemic chemotherapy with or without bracing. They compared the ROVE in children who underwent systemic chemotherapy with or without bracing and supervised management alone. The authors concluded that patients who had systemic chemotherapy with or without brace treatment had statistically significant lower rates of radiographic vertebral body collapse ($P < 0.05$) when compared with children managed with supervised management alone. All 8 patients who had systemic chemotherapy

in their series attained faster ROVE by a mean of 5-year follow-up when compared with children managed with supervised management alone. The authors further added that there was no statistical difference between children who were managed with supervised management (without brace) and with brace alone. Both the groups had taken a mean of 7 years to attain ROVE. All the children in the series were younger than 8 years.

Peng et al¹⁰ evaluated the role of systemic chemotherapy in solitary spinal lesions of LCH with obvious soft tissue extension into the spinal and paravertebral region. The Oucher scale of pain at the local spinal site and radicular pain had improved from a mean of 4.8 and 5.8 respectively, to a mean

of 0.2 and almost nil by 3 months after systemic chemotherapy. All patients exhibited a disappearance of soft tissue shadow by a mean period of 30.3 months. Eight patients in their series had neurological symptoms and all of them except 1 had improved with systemic chemotherapy alone (87.5%). The unimproved single patient required surgery due to the presence of severe neurological symptoms (Frankel grade B).

Jiang et al¹¹ concluded that systemic chemotherapy is justified for children who have LCH at multiple spinal sites. Zhou et al¹⁴ recommended systemic chemotherapy in their study of children with spinal LCH of multifocal or systemic involvement and as an effective adjuvant therapy following surgery or radiation therapy.

Radiation Therapy

Among the included patients, 23 underwent radiation therapy, of whom 14 had radiation therapy in combination with surgery, 2 had radiation therapy in combination with chemotherapy and 7 had radiation therapy alone.^{11,14} Zhou et al¹⁴ had used low-dose radiation therapy alone as the management option. The authors used high-energy x-rays and/or Co60 in their management and limited the dosage to 7.5 Gy for each child in their treatment. All children who had radiation treatment showed improvement in their final follow-up. The authors^{11,14} have not mentioned Garg's grading of the lesions in their series.

Surgery

There were 4 case series¹⁴⁻¹⁷ about surgery as the treatment modality in solitary-unifocal spinal LCH in children. Zheng et al^{15,16} had studied 24 children (13 lesions in the thoracic spine and 11 in the lumbar spine) for a mean follow-up of 70.5 months. LCH of grade IB,¹⁶ IIA and IIB^{15,16} (Garg's classification) was included in their series. The surgical principles followed in both case series included short-segment posterior pedicle screw instrumentation, transpedicular route vertebral endplate preserving curettage of the lesion and removal of posterior instrumentation by 2-year follow-up. The author¹⁶ named the surgical procedure as growth-preserving posterior spinal column reconstruction surgery (GPPSCR). In the series,¹⁵ the authors have used calcium sulfate as the void-filling material following curettage through the transpedicular route as an added measure. Zhou et al¹⁴ used autogenous iliac bone graft or allograft as void filling material (23 patients) in their series following curettage of the lesion.

The surgical indications^{15,16} of the included patients were Garg's grade IB, IIA and IIB; worsening symptoms or radiographic evidence of failure of nonoperative treatment by 3 months; and severe neurological symptoms. Zheng et al¹⁵ concluded that the mean percentage of diseased vertebral body height had increased to 86% of reference vertebral body height by 2-year follow-up ($P = 0.027$). In series,¹⁶ the author reported that the mean vertebral body height had improved by 71.2% following surgery at 1-year follow-up ($P = 0.001$). The authors¹⁶ had initiated the DAL-HX90 chemotherapeutic regimen (initial treatment with prednisone, vinblastine and etoposide followed with mercaptopurine) by 2 weeks following surgery in all of their patients. Both case series advocated for active surgical treatment in Garg's classification of grade II lesions.

Zhou et al¹⁴ found that surgery improved neurological symptoms within 48 hours and relieved pain by 2 weeks when compared with other treatment modalities such as systemic chemotherapy or radiotherapy as the initial modality of choice. The authors documented that LCH involves the vertebral body rather than vertebral end plates in children. Hence, a transpedicular endplates-preserving (sparing osteoepiphysis) curettage helps in debulking the tumor and restores the vertebral body height as the child grows.

A single case series by Zhong et al¹⁷ evaluated the surgical strategy of LCH in the cervical spine among children. Seven children at the C1 to C2 level and 12 children at the C3 to C7 level had undergone surgery with a mean follow-up of 36.4 months. Sixteen children (84.2%) in the series had neurological symptoms. Children with lesions at the C1 to C2 level had undergone anterior resection of the lesion, biopsy and posterior instrumentation. Children with lesions at the C3 to C7 level had undergone anterior corpectomy and fusion for vertebral body lesion (WBB¹⁸ [Weinstein-Boriani-Biagini] zones 4–9), posterior excision and instrumentation for lesions involving the posterior column of the cervical spine (WBB zones 5–10). The Oucher scale for pain improved from a mean of 8.1 to 0.3 at the final follow-up. Children in the series received adjuvant therapy—oral prednisolone, following surgery. The authors concluded that surgery on the cervical spine should be individually tailored according to the location of the lesion.

ROVE is an important radiological parameter indicating the endpoint or healing of the lesion and

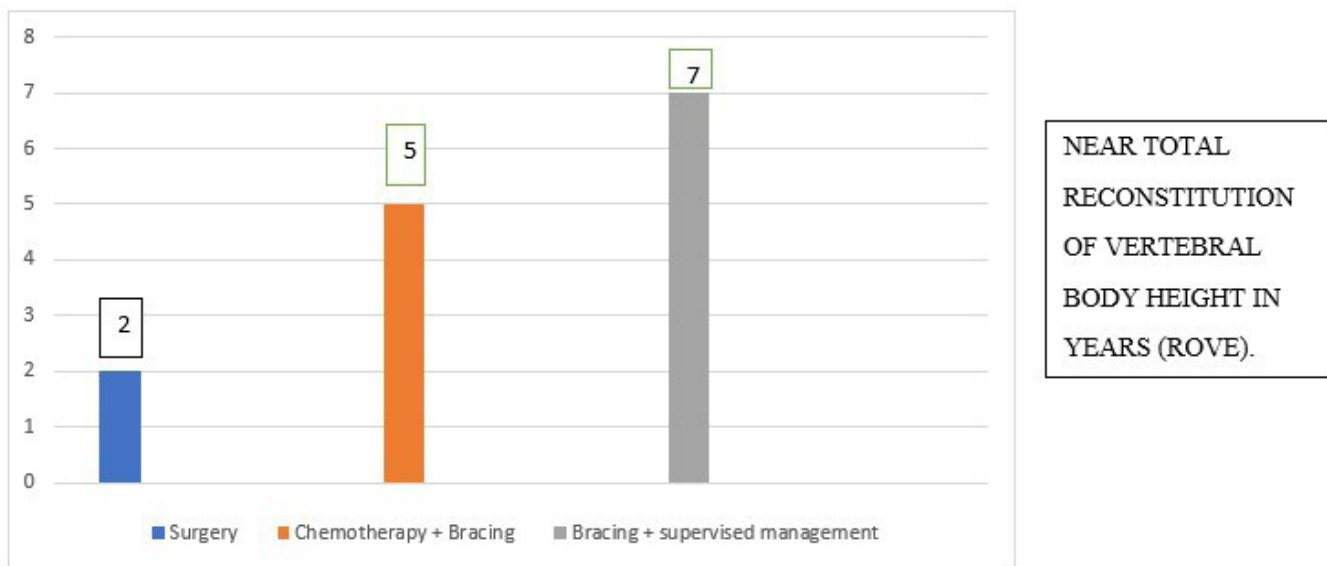

Figure 3. Mean time taken by various treatment modalities to completely restore vertebral body height. ROVE, reconstitution of vertebral body height.

was earlier achieved with surgery (mean period of 2 years),^{15,16} followed by systemic chemotherapy with bracing (mean period of 5 years)¹³ and supervised management with bracing (mean period of 7 years)¹³ among the studied children (Figure 3).

There were 25 patients (6 patients¹⁵ + 3 patients¹⁶ + 16 patients¹⁷; the series by Zhou et al¹⁴ was excluded because it was unclear about postoperative improvement) in the group who had undergone surgery with preoperative neurological symptoms (Frankel grade C and D), and all 25 patients (100%) had complete recovery of their neurological symptoms (Frankel grade E) following surgery by a mean postoperative week 4 without further deterioration at final follow-up (Figure 4).

DISCUSSION

LCH is an uncommon disease that typically presents in infants or children between the ages of 3 and 10 years as a solitary painful lesion in a single flat bone.¹⁹ Finzi was the first surgeon to present a case of eosinophilic granuloma of the spine in 1929. Jaffe and Lichtenstein described the histopathologic picture of eosinophilic granuloma in 1940. In 1953, Lichtenstein coined the term histiocytosis X to combine the disorders: Eosinophilic granuloma, Hand-Schuller-Christian disease, and Letterer-Siwe disease due to the involvement of common Langerhans cell in all these 3 disorders.^{20,21}

The basic principles of the review which we have used to propose our algorithm include the following:

1. Systemic chemotherapy works well in decreasing the risk of vertebral body collapse. It prevents the progression of vertebral body collapse.¹³ It provides good results and optimal outcomes in biopsy-proven solitary spinal LCH presenting with spinal or paravertebral soft tissue involvement or with mild-to-moderate neurological symptoms.¹⁰
2. Surgery has a definite role in solitary spinal LCH presenting with severe neurological symptoms (Frankel grade A/B),^{10,14-16} in the presence of spinal instability,¹⁴ poor response to nonoperative treatment,^{15,16} and in unstable situations involving cervical spine.¹⁷ It has a definite role in Garg's grade IB, II spinal LCH.^{15,16}
3. Radiotherapy or chemotherapy works well as an adjuvant modality following surgery.¹⁴
4. Systemic chemotherapy has an established role in multilevel spinal involvement of LCH.¹¹

We the authors have used the above 4 basic principles in proposing the management algorithm for spinal LCH in children aged 15 years or younger (Figure 5).

In the present systematic review, we found definite evidence that Garg's grade IB and II lesions would benefit from surgery.^{15,16} Supervised management is appropriate for Garg's grade IA. However, the chance of possible mortality with this treatment modality cannot be ignored.¹² Systemic chemotherapy with bracing was found to reduce radiographic vertebral body collapse when compared with supervised management with brace alone.¹³ Garg's grade III needs to be tailored on

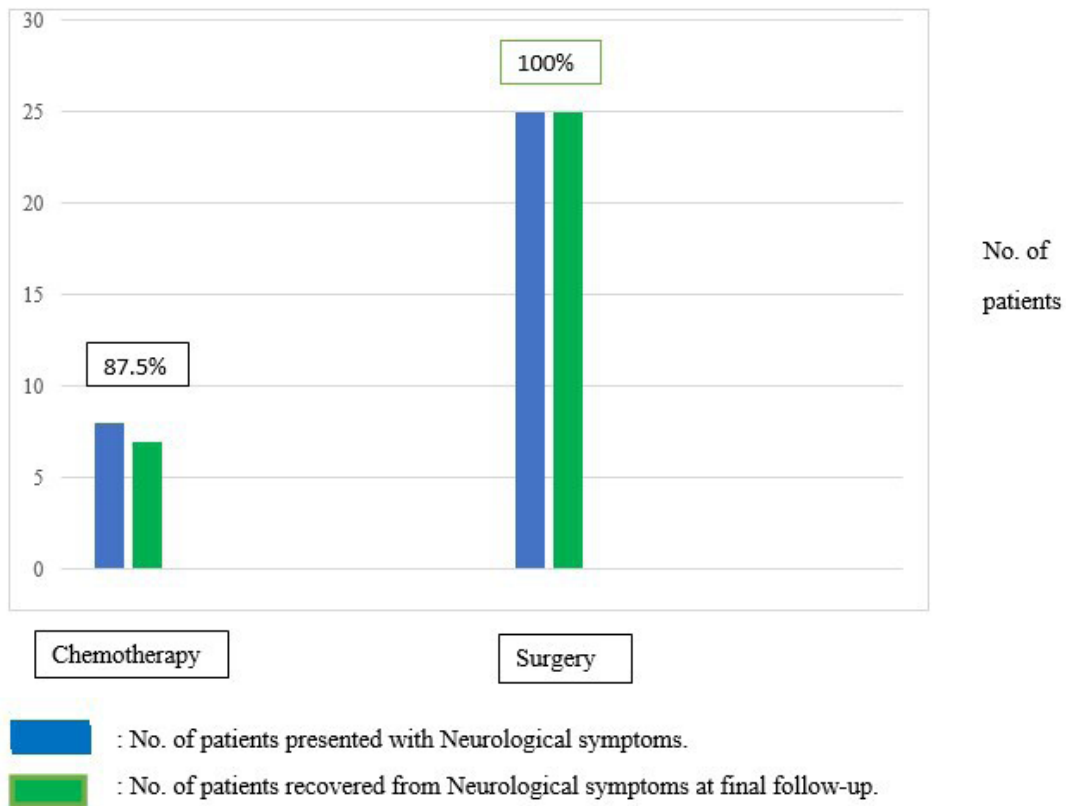


Figure 4. Comparison between the treatment modalities of systemic chemotherapy and surgery in children presenting with neurological symptoms.

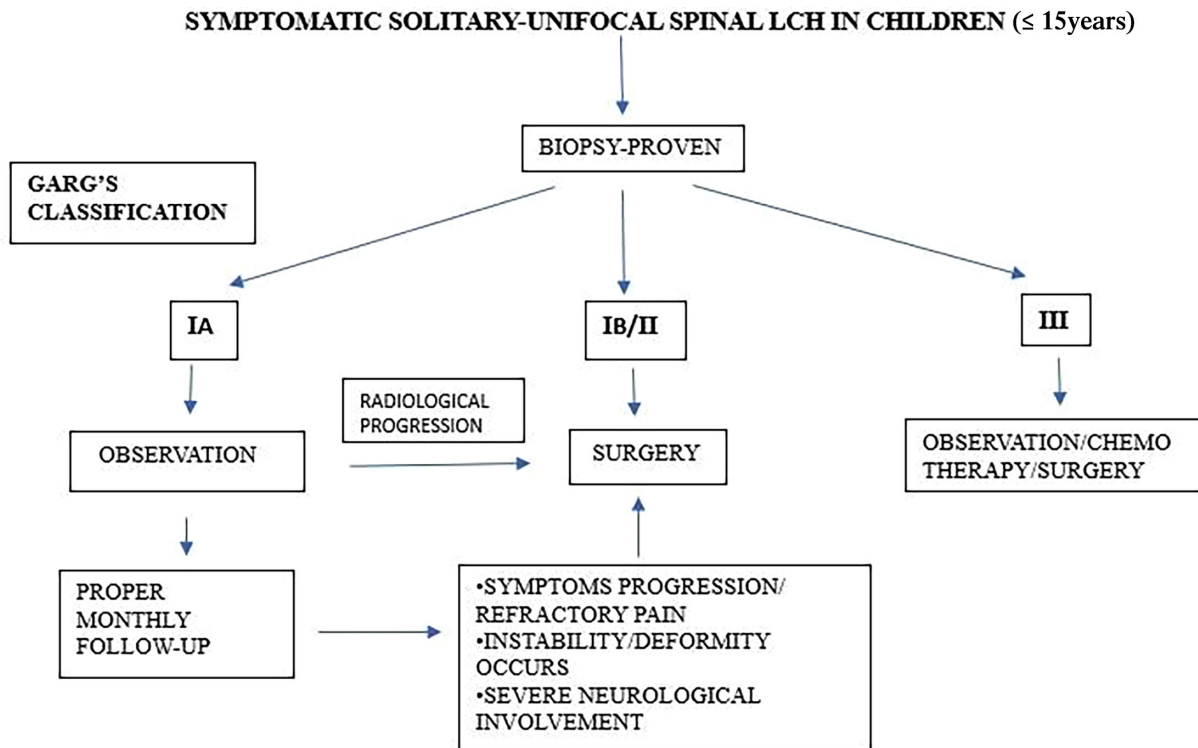


Figure 5. The proposed management algorithm for spinal Langerhans cell histiocytosis (LCH) in children aged 15 years or younger.

an individual patient basis as we found no case series pertaining to it.

The fundamental basis of Garg's classification is based on the morphology and radiographic height of the involved vertebral body correlating to the severity of the disease.⁷ Management of spinal LCH based on Garg's grading of radiographic vertebral body collapse helps the treating specialist in decision-making. Our management algorithm is based on the clinicoradiological presentation of the patient. If the child presents with biopsy-proven symptomatic Garg's grade IA spinal LCH, the child can be managed using the option of observation with brace. Systemic chemotherapy can be offered in consultation with pediatric oncologist, if he/she agrees. Observation can be continued with supervised monthly follow-up of the child if the symptoms do not worsen or the radiological grading of the lesion does not deteriorate. If the radiological grading of the lesion deteriorates to Garg's grade IB/ grade II, if the child's symptoms worsen, if the spinal stability gets compromised, or if the neurological symptoms progress to a severe state (Frankel grade A/B), then the child needs to be considered for surgery.

If the child presents with solitary spinal Garg's grade IB or II lesions, surgery is the management of choice. Short-segment posterior instrumentation, transpedicular route vertebral endplate preserving curettage with void-filler (Calcium sulfate/autograft/allograft) and follow-up with chemotherapy DAL-HX90 protocol by 2 weeks are the key steps in surgery. Management of grade III lesions needs to be tailored on an individual patient basis (as no case series is available). In cervical spinal sites, either an anterior or anteroposterior approach surgery is chosen based on the location of the lesion in the cervical spine. If the child presents with biopsy-proven LCH at multiple spinal sites, systemic chemotherapy is the treatment modality of choice.

In the year 2011, Jiang et al¹¹ documented a management algorithm for pediatric spinal LCH. In the study, the authors recommended that the management of solitary spinal LCH be divided into patients presenting with and without neurological symptoms. Patients with solitary spinal LCH and who are neurologically intact are further subdivided into 2 categories of mild and severe based on the osteolysis of the vertebral body. A vertebral body with mild osteolysis should undergo immobilization and close follow-up. A vertebral body with severe osteolysis should undergo low-dose radiation therapy. Patients with neurological symptoms are to be divided based on their severity. Patients with LCH and mild or moderate neurological symptoms should

undergo radiation treatment, while patients with severe neurological symptoms should undergo surgery. The author has advised systemic chemotherapy in patients with systemic or multifocal spinal LCH. The author has not given clear-cut guidelines for grading vertebral osteolysis into mild and severe in neurologically intact patients. Our management algorithm is based on Garg's grading of radiographic vertebral body collapse, and we suggest observation for Garg's classification grade IA and surgery in Garg's grades IB and II. We have avoided radiation therapy in our algorithm because it has been postulated to cause secondary malignancy and vertebral growth disturbances in children.^{20,22}

Each of the studied treatment modalities has its advantages and disadvantages. Supervised management with or without bracing is the traditional and earliest treatment modality and has been followed by spine specialists in the treatment of pediatric spinal LCH since the 20th century.²³ The usage period of brace has been a controversy in the literature. Few authors^{23,24} recommend them to be used for a mean period of 3 to 5 years, and a few others⁷ recommend them to be used only during the acute painful phase for a mean period of 8 to 12 weeks. Garg et al⁷ have emphasized to consider this modality in all the children presenting with asymptomatic radiographic vertebral collapse (no intractable pain or neurological deficit) in biopsy-proven spinal LCH as they have shown in their study, the severity of radiographic collapse was not associated with subsequent spinal deformity and only proper follow-up is required to monitor their recovery. The major drawback of this treatment modality is the unforeseen mortality of the patients due to the invasive nature of the disease. Abdelaal et al¹² attributed a mortality rate of 13.3% with this treatment modality. The other limitation of this treatment approach is that near total ROVE takes longer when compared with other treatment modalities.

Systemic chemotherapy has been the game changer in the management of symptomatic pediatric spinal LCH since its advent in the early 21st century. It can be used in pediatric spinal LCH presenting with spinal or paravertebral soft tissue involvement and spinal LCH presenting with mild-to-moderate neurological symptoms. The major advantage of systemic chemotherapy is that it has the potential to reduce the risk of vertebral body height collapse.¹³ The scenario where chemotherapy fails is in situations of spinal LCH presenting with severe neurological symptoms (Frankel grades A and B).¹⁰ In pediatric spinal LCH, vincristine; methotrexate; prednisone and 6-mercaptopurine are the combination of drugs used in systemic chemotherapy.^{10,25}

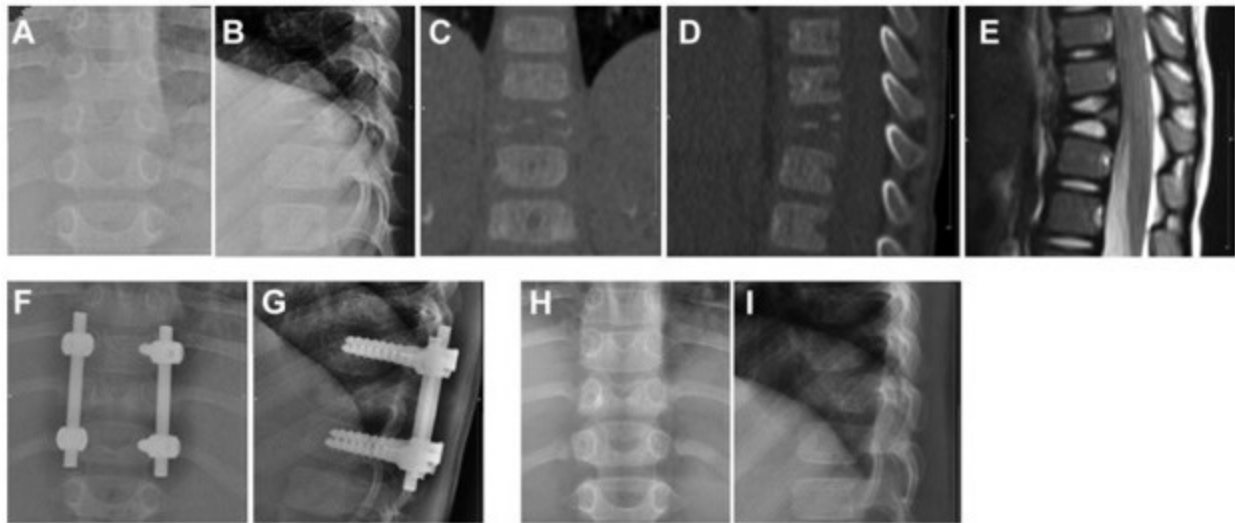


Figure 6. Two-year-old boy with grade IIB spinal T11 Langerhans cell histiocytosis. (A and B) Radiographic picture. (C and D) CT images. (E) T2-weighted magnetic resonance imaging. (F and G) One-year follow-up following surgery. (H and I) Three years following surgery, 1 year following implant removal. Complete remodeling of vertebral body and near-total restoration of vertebral body height is seen. Reprinted with permission from Zheng et al.¹⁶

Low-dose radiation therapy has a curative effect in the management of symptomatic spinal LCH in children because of the radiosensitive nature of LCH.^{14,26} However, it is mirrored by controversies in literature due to ill effects such as secondary malignancy²⁷ and damage to vertebral body bony end plates.²⁸ A few authors^{14,29} recommend them either alone or as adjuvant therapy following surgery or systemic chemotherapy in the management of spinal LCH in children despite the emphasis on the ill effects of radiation therapy in literature.

Surgery is the spearhead among all the treatment modalities and is the modality of choice in symptomatic Garg's grading of IB and II of pediatric spinal LCH (Figure 6).¹⁴⁻¹⁶ It has a significant role to play when the child presents with severe neurological symptoms (Frankel grades A and B). The main advantage of surgery is that it relieves neurological symptoms early, provides pain relief, stabilizes the spine and shortens the course of the disease.^{14,15} Other modalities, such as radiation therapy and chemotherapy can work as a perfect adjuvant to surgery if the surgeon believes that a near-total curettage of the lesion was not done intra-operatively.¹⁴ The role of surgery in cervical spinal solitary site LCH in children is well documented in spinal literature.^{6,17}

We accept the fact that the load burden of the disease to the children increases in spinal LCH with the involvement at multiple spinal sites and in systemic LCH when compared with the solitary spinal LCH. Hence, the use of systemic chemotherapy as the modality of choice is justified in such scenarios.

Limitations

Pediatric spinal LCH is an uncommon problem seen by spine specialists, and no randomized control study exists in the literature regarding its management. All the included series in the review were retrospective, and the absence of a randomized control study among the included studies can compromise the arrived conclusion. The included case series have not documented the complications of the studied treatment modalities, and few have included children with multifocal LCH along with solitary-unifocal LCH which can bias the results. The differing ethnicity of the studied children also needs to be considered. However, our review has certainly shown light at the end of the dark tunnel to practicing spine specialists in this uncommon scenario.

Grade of Recommendation: Grade C—Optional

The included case series were of level IV evidence in the hierarchy of evidence pyramid. The grade of recommendation is C- optional.³⁰ We authors recommend using the management algorithm as an option by treating specialists along with their clinical expertise balancing the options of observation, systemic chemotherapy with bracing and surgery in the management of spinal LCH in children.

CONCLUSION

Pediatric spinal LCH can be managed following Garg's classification of radiographic vertebral body

collapse. Garg's grade IA can be managed with observation. In Garg's grade IB, II spinal LCH surgery is the treatment of choice. Grade III LCH management should be tailored on an individual patient basis.

REFERENCES

- Liu H, Stiller CA, Crooks CJ, et al. Incidence, prevalence and survival in patients with langerhans cell histiocytosis: a national registry study from england, 2013-2019. *Br J Haematol*. 2022;199(5):728–738. doi:10.1111/bjh.18459
- Guyot-Goubin A, Donadieu J, Barkaoui M, Bellec S, Thomas C, Clavel J. Descriptive epidemiology of childhood langerhans cell histiocytosis in france, 2000–2004. *Pediatr Blood Cancer*. 2008;51(1):71–75. doi:10.1002/pbc.21498
- Rodriguez-Galindo C, Allen CE. Langerhans cell histiocytosis. *Blood*. 2020;135(16):1319–1331. doi:10.1182/blood.2019000934
- Allen CE, Merad M, McClain KL. Langerhans-cell histiocytosis. *N Engl J Med*. 2018;379(9):856–868. doi:10.1056/NEJMra1607548
- Zheng W, Wu J, Wu Z, Xiao J. Atlantoaxial instability secondary to eosinophilic granuloma of the axis in adults: long-term follow-up in six cases. *Spine J*. 2014;14(11):2701–2709. doi:10.1016/j.spinee.2014.03.013
- Moyano CA, Remondino RG, Tello CA, et al. Histiocytosis in the pediatric spine: a clinical and radiographic analysis of 50 patients. *Spine Deform*. 2021;9(3):823–831. doi:10.1007/s43390-020-00261-8
- Garg S, Mehta S, Dormans JP. Langerhans cell histiocytosis of the spine in children. long-term follow-up. *J Bone Joint Surg Am*. 2004;86(8):1740–1750. doi:10.2106/00004623-200408000-00019
- Page MJ, McKenzie JE, Bossuyt PM, et al. The PRISMA 2020 statement: an updated guideline for reporting systematic reviews. *BMJ*. 2021;372. doi:10.1136/bmj.n71
- Slim K, Nini E, Forestier D, Kwiatkowski F, Panis Y, Chipponi J. Methodological index for non-randomized studies (minors): development and validation of a new instrument. *ANZ J Surg*. 2003;73(9):712–716. doi:10.1046/j.1445-2197.2003.02748.x
- Peng X-S, Pan T, Chen L-Y, Huang G, Wang J. Langerhans' cell histiocytosis of the spine in children with soft tissue extension and chemotherapy. *Int Orthop*. 2009;33(3):731–736. doi:10.1007/s00264-008-0529-8
- Jiang L, Liu XG, Zhong WQ, et al. Langerhans cell histiocytosis with multiple spinal involvement. *Eur Spine J*. 2011;20(11):1961–1969. doi:10.1007/s00586-010-1390-1
- Abdelaal AHK, Sedky M, Gohar S, et al. Skeletal involvement in children with langerhans cell histiocytosis: healing, complications, and functional outcome. *SICOT J*. 2020;6. doi:10.1051/sicotj/2020024
- Nakamura N, Inaba Y, Aota Y, Machida J, Saito T. Characteristic reconstitution of the spinal langerhans cell histiocytosis in young children. *J Pediatr Orthop*. 2019;39(4):e308–e311. doi:10.1097/BPO.0000000000001283
- Zhou Z, Zhang H, Guo C, Yu H, Wang L, Guo Q. Management of eosinophilic granuloma in pediatric patients: surgical intervention and surgery combined with postoperative radiotherapy and/or chemotherapy. *Childs Nerv Syst*. 2017;33(4):583–593. doi:10.1007/s00381-017-3363-8
- Zheng Y, Zhang Z, Wang D. Better vertebrae remodeling in pediatric spinal eosinophilic granuloma patients treated with kyphoplasty and short-term posterior instrumentation: a minimal two-year follow-up with historical controls. *Front Pediatr*. 2022;10. doi:10.3389/fped.2022.922844
- Zheng Y, Ning B, Wu C, Qian C, Meng J, Wang D. Posterior focal curettage and spine stability reconstruction by temporary pedicle screw fixation in children with collapsed vertebrae due to eosinophilic granuloma. *Glob Spine J*. 2022;12(8):1745–1750. doi:10.1177/2192568220988269
- Zhong N, Xu W, Meng T, Yang X, Yan W, Xiao J. The surgical strategy for eosinophilic granuloma of the pediatric cervical spine complicated with neurologic deficit and/or spinal instability. *World J Surg Oncol*. 2016;14(1). doi:10.1186/s12957-016-1063-6
- Boriani S, Weinstein JN, Biagini R. Primary bone tumors of the spine. *Spine*. 1997;22(9):1036–1044. doi:10.1097/00007632-199705010-00020
- Whyte MP. Infiltrative disorders of bone. In: *Primer on the Metabolic Bone Diseases and Disorders of Mineral Metabolism*. Washington, DC, USA: American Society for Bone and Mineral Research; 1990:247–248.
- Levine SE, Dormans JP, Meyer JS, Corcoran TA. Langerhans' cell histiocytosis of the spine in children. *Clin Orthop Relat Res*. 1996;323:288–293. doi:10.1097/00003086-199602000-00040
- Sholl LM, Hornick JL, Pinkus JL, Pinkus GS, Padera RF. Immunohistochemical analysis of langerin in langerhans cell histiocytosis and pulmonary inflammatory and infectious diseases. *Am J Surg Pathol*. 2007;31(6):947–952. doi:10.1097/01.pas.0000249443.82971.bb
- Bertram C, Madert J, Eggers C. Eosinophilic granuloma of the cervical spine. *Spine*. 2002;27(13):1408–1413. doi:10.1097/00007632-200207010-00007
- Mammano S, Candiotti S, Balsano M. Cast and brace treatment of eosinophilic granuloma of the spine: long-term follow-up. *J Pediatr Orthop*. 1997;17(6):821–827.
- Raab P, Hohmann F, Kühl J, Krauspe R. Vertebral remodeling in eosinophilic granuloma of the spine. *Spine*. 1998;23(12):1351–1354. doi:10.1097/00007632-199806150-00011
- Cantu MA, Lupo PJ, Bilgi M, Hicks MJ, Allen CE, McClain KL. Optimal therapy for adults with langerhans cell histiocytosis bone lesions. *PLOS ONE*. 2012;7(8). doi:10.1371/journal.pone.0043257
- Hung Y-C, Chang F-C, Chen Y-W, et al. Langerhans' cell histiocytosis in the pediatric spine: therapeutic dynamic change of spinal deformity. *Childs Nerv Syst*. 2012;28(8):1243–1250. doi:10.1007/s00381-012-1764-2
- Greenberger JS, Crocker AC, Vawter G, Jaffe N, Cassady JR. Results of treatment of 127 patients with systemic histiocytosis. *Medicine*. 1981;60(5):311–338. doi:10.1097/00005792-198109000-00001
- Tan H-Q, Li M-H, Wu C-G, Gu Y-F, Zhang H, Fang C. Percutaneous vertebroplasty for eosinophilic granuloma of the cervical spine in a child. *Pediatr Radiol*. 2007;37(10):1053–1057. doi:10.1007/s00247-007-0575-1
- Stringham DR, Hadjipavlou A, Dzioba RB, Lander P. Percutaneous transpedicular biops of the spine. *Spine*. 1994;19(17):1985–1991. doi:10.1097/00007632-199409000-00021
- Wright JG, Einhorn TA, Heckman JD. Grades of recommendation. *J Bone Joint Surg*. 2005;87(9):1909–1910. doi:10.2106/JBJS.8709.edit

Funding: The authors received no financial support for the research, authorship, and/or publication of this article.

Declaration of Conflicting Interests: The authors report no conflicts of interest in this work.

Author Contributions: Made substantial contributions to the conception or design of the work: M.H.S. Acquisition, analysis, or interpretation of data or the creation of new software used in the work: M.H.S. and V.M. Drafted the work or revised it critically for important intellectual content: M.H.S. and M.V. Approved the version to be published and agree to be accountable for all aspects of the work in ensuring that questions related to the accuracy or integrity of any part of the work are

appropriately investigated and resolved: M.H.S., V.M., and M.V.

Ethics Approval: An IRB official waiver of ethical approval was granted from the IRB of Apollo Hospitals.

Corresponding Author: Macherla Haribabu Subramaniam, Apollo Specialty Hospital, Rajiv Gandhi Salai, Perungudi, Chennai -600 096, Tamil Nadu, India; orthdrmh@gmail.com

Published 19 November 2024

This manuscript is generously published free of charge by ISASS, the International Society for the Advancement of Spine Surgery. Copyright © 2024 ISASS. To see more or order reprints or permissions, see <http://ijssurgery.com>.