

## Surgical Outcomes of Minimally Invasive Transforaminal Lumbar Interbody Fusion Using Surgical Microscope vs Surgical Loupes: A Comparative Study

Weerasak Singhatanadgige, Hathaiphoom Chamadol, Teerachat Tanasansomboon, Daniel G. Kang, Wicharn Yingsakmongkol and Worawat Limthongkul

*Int J Spine Surg* published online 14 July 2022  
<https://www.ijssurgery.com/content/early/2022/07/13/8303>

This information is current as of October 9, 2024.

---

**Email Alerts** Receive free email-alerts when new articles cite this article. Sign up at:  
<http://ijssurgery.com/alerts>

# Surgical Outcomes of Minimally Invasive Transforaminal Lumbar Interbody Fusion Using Surgical Microscope vs Surgical Loupes: A Comparative Study

WEERASAK SINGHATANADGIGE, MD, MS<sup>1,2</sup>; HATHAIPHOOM CHAMADOL, MD<sup>1</sup>;  
TEERACHAT TANASANSOMBOON, MD<sup>1,2</sup>; DANIEL G. KANG, MD<sup>3</sup>; WICHARN YINGSAKMONGKOL, MD<sup>1,2</sup>; AND  
WORAWAT LIMTHONGKUL, MD<sup>1,2</sup>

<sup>1</sup>Department of Orthopedics, Faculty of Medicine, Chulalongkorn University and King Chulalongkorn Memorial Hospital, Bangkok, Thailand; <sup>2</sup>Center of Excellence in Biomechanics and Innovative Spine Surgery, Chulalongkorn University, Bangkok, Thailand; <sup>3</sup>Department of Orthopaedic Surgery, Madigan Army Medical Center, Washington, USA

## ABSTRACT

**Background:** Minimally invasive transforaminal interbody fusion (MIS-TLIF) is an effective procedure for lumbar spine diseases. The procedure can be done using a surgical microscope (SM) or surgical loupes (SL) magnification. However, there are no studies that compared outcomes between using these 2 magnifying devices in the MIS-TLIF procedure. The purpose of this study was to compare clinical outcomes, perioperative complications, and radiographic parameters of MIS-TLIF using SM compared with SL magnification.

**Methods:** We included all patients undergoing 1-level MIS-TLIF between January 2017 and December 2019. Type of magnification (SM vs SL), operative time, blood loss, perioperative complications, cross-sectional area of the spinal canal, and fusion rates were analyzed. Clinical outcomes measurement using the visual analog scale (VAS) and Oswestry Disability Index (ODI) were compared between groups.

**Results:** A total of 100 patients had underwent MIS-TLIF (SM group: 62; SL group: 38). Operative time (SM: 182.7 ± 41.5 vs SL: 165.6 ± 32.6 minutes,  $P = 0.043$ ) was significantly shorter in the SL group, with a mean difference of 17.2 minutes and a 10.4% increase in operative time between SL and SM. Blood loss (SM: 187.4 ± 176.4 vs SL: 215.6 ± 99.4 mL,  $P = 0.36$ ) was not different between groups, with a mean difference of 28.2 mL. Both the SM group and SL group demonstrated no significant differences in improvement from baseline in VAS back, VAS legs, ODI score, and cross-sectional area of the spinal canal. There was also no significant difference in complication rates and fusion rates between groups.

**Conclusions:** Our study found no difference between intraoperative use of SL compared with SM in clinical outcomes through the 12-month follow-up timepoint. However, the use of SM resulted in an increased average operative time of 17 minutes compared with the SL group.

**Clinical Relevance:** Intraoperative use of SM and SL magnification in MIS-TLIF provides similar outcomes except prolonged operative time in the SM group.

**Level of Evidence:** 3.

Minimally Invasive Surgery

Keywords: minimally invasive, transforaminal, MIS-TLIF, microscope, loupes

## INTRODUCTION

Minimally invasive transforaminal lumbar interbody fusion (MIS-TLIF) has been reported to result in less trauma to soft tissue and back muscles, decreased blood loss and length of hospital stay, as well as improved functional outcomes compared with an open TLIF procedure.<sup>1–6</sup> Visualization is an important factor for success in any surgical procedure and becomes even more critical when operating through a reduced surgical field such as with MIS-TLIF. Some surgeons use the surgical microscope (SM) for magnification and lighting. Some studies reported that surgical site infection

rates in patients who underwent lumbar microdiscectomy were not different between the groups that used SM or surgical loupes (SL).<sup>7,8</sup> Basques et al found that operative time was slightly increased with using SM during spine surgeries.<sup>9</sup> However, this study was a database review that included a heterogeneous cervical and lumbar surgeries sample. SL magnification is also used by some surgeons for performing MIS-TLIF with favorable outcomes.<sup>4</sup> Nevertheless, some surgeons purport that the use of the intraoperative microscope may allow for a more extensive decompression and potentially improved clinical outcomes and fewer intraoperative complications when performing

MIS-TLIF. We hypothesized that there would be no difference in clinical outcomes or complications when comparing MIS-TLIF cases using SM vs SL. Therefore, the purpose of our study was to compare clinical outcomes, complication rates, and radiographic parameters of MIS-TLIF performed by using SM vs SL magnification.

## METHODS

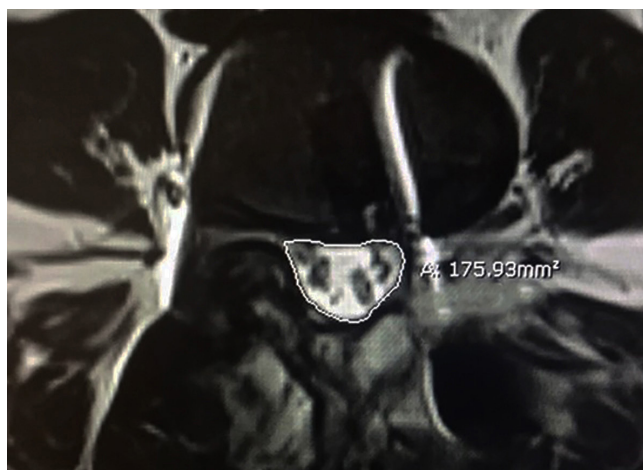We performed a retrospective study evaluating the spine registry data at a single institution by a single surgeon (W.S.). We included patients who had undergone 1-level MIS-TLIF for degenerative lumbar spine diseases with SM or SL between January 2017 and July 2019. The first 38 patients underwent MIS-TLIF using SL, and the subsequent 62 patients underwent the procedure with SM because the hospital acquired a new microscope in the middle of the study period. Patients were excluded if completed patient-reported outcomes were not collected (at baseline and at 1-day, 1-month, 3-month, 6-month, and 12-month postoperative periods). Patients with spinal infection, tumor, or prior spinal surgery were also excluded.

### Data Collection

Baseline data included patient demographics, symptoms, diagnosis, past medical history, patient comorbidities, and preoperative spinal canal cross-sectional area. Perioperative data included estimated blood loss, operative time (from incision to wound closure), and perioperative complications.

Patient-reported outcomes included measurement of Oswestry Disability Index (ODI) and visual analog scale (VAS) score for back pain and leg pain, and both outcome measures were evaluated at preoperative, immediate postoperative (1 day), 1 month, 3 months, 6 months, and 1 year after surgery.

We used picture archiving and communication system program to evaluate the cross-sectional area of the spinal canal on axial view T2-weighted magnetic resonance images at the facet joint level (Figure 1). The area was measured on the preoperative and 3-month postoperative images. The spinal fusion was evaluated by computed tomography images and flexion-extension radiographs 12 months after the operation. Fusion was defined by less than 3-mm translation and 5° angular motion on the flexion-extension radiographs as well as complete bone bridging between the end plates on the computed tomography image.<sup>2,10,11</sup>



**Figure 1.** Spinal canal cross-sectional area was measured by drawing the line surrounding spinal canal using digital synapse picture archiving and communication system.

### Statistical Analyses

Statistical analyses included descriptive statistics and univariate analysis using Student *t* test. Statistical significance was defined as  $P < 0.05$ . All analyses were performed using SPSS.

### Surgical Techniques

The MIS-TLIF procedure was performed with the patient placed in the prone position. Fluoroscopy was then used to identify the starting incision between pedicles of the operative levels. A 2.5-cm skin incision was then made over the interpedicle line and approached through the underlying paraspinous fascia and muscles. A Jamshidi needle was advanced into each pedicle bilaterally using biplanar fluoroscopic guidance. Kirschner guide wires were then placed through the Jamshidi needle, and then the needle was removed over the wire. The Kirschner wires were then bent in cephalad and caudad directions away from the incision site. Sequential dilation was then performed, followed by tubular retractor placement. At this point, the surgeon used either the SM (Carl Zeiss OPMI-Vario700) or the Aculux xenon headlight with 2.5 power SL for magnification and visualization. Hemilaminectomy and facetectomy were performed using high-speed burr and Kerrison rongeur. The ligamentum flavum was removed to identify the thecal sac and nerve root. In the patient with bilateral symptoms, we also decompressed the contralateral side using the “over the top technique.” Discectomy was performed, followed by meticulous end plate preparation. The trial was inserted and sized. Autologous local bone graft plus demineralized bone matrix was used to enhance fusion. Bone graft plus demineralized bone

**Table 1.** Demographic data.

Patient Demographics	Surgical Microscope (n = 62)	Surgical Loupes (n = 38)	P Value
Age, y, mean ± SD	63.7 ± 9.8	66.3 ± 9.2	0.23
Body mass index, mean ± SD	25.0 ± 3.7	25.1 ± 3.9	0.98
Diabetes, n (%)	12 (19.4)	8 (21.1)	0.38
Hypertension, n (%)	36 (58.1)	18 (47.4)	0.64
Dyslipidemia, n (%)	27 (43.6)	12 (31.6)	0.9
Smoker, n (%)	6 (9.7)	1 (2.6)	0.23
Operated level, n (%)			
L2-L3	1 (1.6)	0 (0)	0.32
L3-L4	7 (11.3)	5 (13.2)	0.55
L4-L5	43 (69.4)	28 (73.6)	0.02
L5-S1	11 (17.7)	5 (13.2)	0.12
Diagnosis, n (%)			
Spondylolisthesis	23 (36.9)	19 (48.4)	0.3
Spinal canal stenosis	21 (33.8)	12 (32.3)	0.88
Herniated nucleus pulposus	17 (27.7)	7 (19.4)	0.59
Degenerative disc disease	1 (1.5)	0	0.64

matrix was placed in the anterior portion of disc space, followed by the intervertebral polyetheretherketone cage (CAPSTONE, Medtronic). Percutaneous screws and rods (CD HORIZON SEXTANT II, Medtronic) were then placed on both sides. A drain was placed only on the TLIF side, and the incision was then closed layer by layer.<sup>4,12</sup>

## RESULTS

A total of 100 MIS-TLIF (SM group: 62; SL group: 38) were included in this study. The mean follow-up time was 20.4 months in the SM group and 24.3 months in the SL group. There was no difference between groups in age, body mass index, smoking status, or comorbidities (hypertension, diabetes, and dyslipidemia). Spondylolisthesis was the most common diagnosis in both groups, followed by spinal canal stenosis and degenerative disc disease (Table 1).

### Baseline Patient-Reported Outcome Measures

At baseline, there was no difference in baseline VAS back pain, VAS leg pain, and ODI score. Similarly, we found no difference in mean spinal canal cross-sectional

area between groups (SM: 73.5 ± 35.4 vs SL: 68.1 ± 33.9 mm<sup>2</sup>, *P* = 0.433).

### Intraoperative Outcome Measures

The duration of surgery was significantly different between groups, with the SL group having a shorter mean operative time (SM: 182.7 ± 41.5 vs SL: 165.6 ± 32.6 minutes, *P* = 0.043). Mean blood loss was not significantly different between groups (SM: 215.6 ± 99.4 vs SL: 187.4 ± 176.4 mL, *P* = 0.36). There were also no significant differences in operative time between the first 30 and the last 30 cases of the SM group (*P* = 0.406).

### Postoperative Patient-Reported Outcome Measures

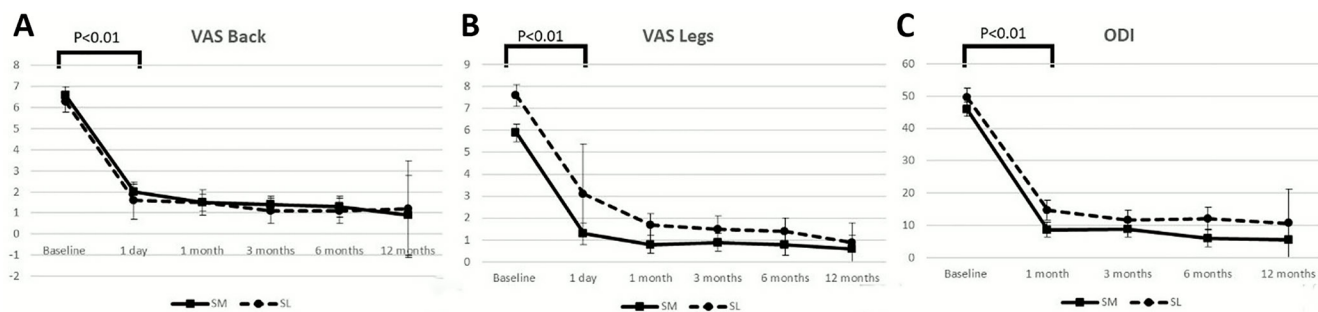
VAS back and leg pain were significantly improved in both groups from baseline to immediate postoperative (*P* < 0.01). These improvements were sustained through the 12-month follow-up. There was no significant difference in VAS back pain or VAS leg pain between these groups at any follow-up timepoint (Table 2 and Figure 2A and B).

**Table 2.** Patient-reported outcome in back pain (VAS back) and leg pain (VAS legs).

Timepoint	VAS Back			VAS Legs		
	Surgical Microscope	Surgical Loupes	P Value	Surgical Microscope	Surgical Loupes	P Value
Baseline	6.8 ± 3.2	6.0 ± 4.2	0.44	5.9 ± 3.5	7.4 ± 3	0.052
1 d	2 ± 1.6	1.8 ± 1.8	0.725	1.1 ± 2.4	2.25 ± 2	0.381
1 mo	1.5 ± 2.4	1.2 ± 2.3	0.538	0.8 ± 1.5	1.6 ± 2.5	0.192
3 mo	1.4 ± 2.3	0.9 ± 2.3	0.478	1 ± 2.4	1.6 ± 2.5	0.453
6 mo	1.5 ± 2.7	1.3 ± 2.4	0.719	1.2 ± 2.6	1.8 ± 2.6	0.489
12 mo	0.9 ± 1.9	1.2 ± 2.3	0.702	0.6 ± 1.7	0.9 ± 1.7	0.615

Abbreviation: VAS, visual analog scale.

Data provided as mean ± SD.



**Figure 2.** Patient-reported outcome in (A) visual analog scale (VAS) back, (B) VAS legs, and (C) Oswestry Disability Index (ODI).

ODI score was also significantly improved in both groups from baseline to immediate postoperative ( $P < 0.01$  in both groups). There was no difference in ODI score between both groups at any follow-up timepoint (Table 3 and Figure 2C).

There was a significant improvement from baseline to postoperative spinal canal cross-sectional area in both groups. In the SM group, the mean cross-sectional area increased from 73.5 to 161.9 mm<sup>2</sup> (120% improvement). In the SL group, the mean cross-sectional area increased from 68.1 to 174.4 mm<sup>2</sup> (156% improvement). There was no difference in mean postoperative spinal canal cross-sectional area between these groups (SM: 161.9 ± 45.3 vs SL: 174.4 ± 16.9,  $P = 0.348$ ).

There was no significant difference in fusion rates at 12 months postoperative between the SM group (91.84%) and the SL group (83.33%) ( $P = 0.397$ ).

The rate of postoperative complications was not different between these groups. There was no incidental durotomy or infection in both groups. Two patients in the SM group and a single patient in the SL group experienced new postoperative lower extremity sensory changes, and all patients recovered in a month after the operation.

## DISCUSSION

The MIS-TLIF procedure has been shown to be a better treatment option compared with traditional open procedures in terms of recovery time and blood loss,<sup>1-3</sup>

and this procedure can be performed using an SM or SL for better visualization.<sup>4</sup> However, to our knowledge, there is no literature to date that compares outcomes between these 2 methods used for performing MIS-TLIF. The theoretical benefits of using SM are greater magnification and a direct light source. These advantages may help surgeons achieve a more extensive and thorough decompression, decreased bleeding due to better identification of bleeding points, more effective in controlling epidural bleeding, and better disc preparation and removal for arthrodesis. Nevertheless, our study did not confirm these theoretical benefits. This study showed no difference in clinical outcomes between the SM and SL groups. Furthermore, the use of SM may be associated with increased operative time.

We performed a retrospective cohort study with at least 1-year follow-up of MIS-TLIF performed with SM vs SL. Our study found no difference in clinical outcomes at 1 year postoperative as well as no difference in complication rates between groups. The duration of surgery was significantly longer in the SM group compared with the SL group, with 17 minutes (10% increase) longer on average in the SM group. The finding may be explained by the preparation period of the microscope, such as sterile draping and positioning. In addition, adjustments are made several times during the use of the SM to maintain appropriate visual fields, lighting, and magnification, whereas these adjustments are not required with the use of SL. Our findings are similar to an investigation of anterior cervical discectomy and fusion (ACDF) procedure by Adogwa et al, who analyzed 140 ACDF patients with and without using an SM. The study found no difference in outcomes except for a significant increase ( $P = 0.01$ ) in operative time. The average operative time was 71 minutes (73% increase) longer with the use of SM.<sup>13</sup> Davidson et al also reported a significant increase ( $P < 0.001$ ) of average operative time (30 minutes) in thyroidectomy procedure with the use of an intraoperative

**Table 3.** Patient-reported outcome in back pain (ODI).

ODI Timepoint	Surgical Microscope	Surgical Loupes	P Value
Baseline	46.5 ± 15.6	50.7 ± 16.4	0.297
1 mo	11 ± 12.9	12.4 ± 14.5	0.734
3 mo	13 ± 19.9	9.6 ± 13.2	0.437
6 mo	10.5 ± 18.7	12.7 ± 16.6	0.675
12 mo	5.5 ± 13.5	10.7 ± 16	0.249

Abbreviation: ODI, Oswestry Disability Index.

Data provided as mean ± SD.

microscope.<sup>14</sup> The SM group had no difference in blood loss when compared with the SL group, which was a similar finding in the current study on MIS-TLIF.

Our study found no difference in baseline demographic parameters or patient-reported outcomes. We demonstrated significant improvement in patient-reported outcomes (VAS back, VAS leg, and ODI) from baseline to all follow-up timepoints in both groups, but no difference in these outcomes at any follow-up timepoint between these groups. The spinal canal cross-sectional area was significantly increased from baseline to the 12-month postoperative time point in each group. However, there was no difference in postoperative cross-sectional area between these groups. Finally, fusion rates were not significantly different between the SM group (91.84%) and the SL group (83.33%).

Our data suggested that both SM and SL are effective for magnification and lighting in the MIS-TLIF procedure performed through a tubular retractor. These 2 visualization methods provided similar clinical outcomes, the extent of decompression, and fusion rates. As previously noted, our results are similar to a study of ACDF procedure in 2016 by Adogwa et al, which found no difference in outcomes.<sup>13</sup> More recently, Ehanire et al evaluated free-flap procedures with SM vs SL and also reported no statistical difference in outcomes and safety between 2 methods.<sup>15</sup> We did not find any previous study specifically comparing the use of SM and SL when performing MIS-TLIF. The study by Basques et al included both cervical and lumbar surgeries. However, the lumbar procedures in their study contained many procedures such as laminotomy, laminectomy, anterior fusion, and posterior fusion. The multivariate analysis found that the microscopic group was associated with an increase of 13.2 minutes of average operative time when their model was controlled for demographic data, comorbidities, and operative characteristics.<sup>10</sup>

Regarding the retrospective nature, this study may potentially have selection bias. However, the baseline demographic characteristics were not different between SM and SL groups. In addition, all surgeries were performed by a single surgeon, which may reduce the variation of surgical outcomes. Due to the small sample size, multivariate analysis was not able to perform in our study. A larger sample size with a longer follow-up time may provide additional data in future studies.

## CONCLUSIONS

Our study found no significant difference in clinical outcomes between intraoperative use of SL compared with SM. During 12-month follow-up period, there was

no difference in patient-reported outcomes, the extent of decompression, fusion rates, and complications between groups. However, the average operative time was 17 minutes longer in the SM group, accounting for 10% longer duration than in the SL group.

## ACKNOWLEDGMENTS

The authors thank Thanachaporn Kittipibul, MD, and Clinical Research Center, Chulalongkorn University, for their support of this study.

## REFERENCES

1. Lee LY, Idris Z, Beng TB, et al. Outcomes of minimally invasive surgery compared to open posterior lumbar instrumentation and fusion. *Asian J Neurosurg*. 2017;12(4):620–637. doi:10.4103/ajns.AJNS\_331\_16
2. Price JP, Dawson JM, Schwender JD, Schellhas KP, et al. Clinical and radiologic comparison of minimally invasive surgery with traditional open transforaminal lumbar interbody fusion: a review of 452 patients from a single center. *Clin Spine Surg*. 2018;31(2):E121–E126. doi:10.1097/BSD.0000000000000581
3. Dai JH, Lin HB, Li X, Wu YY, Zhang HZ, Yu ZX, et al. Clinical effect of minimally-invasive surgical-transforaminal lumbar interbody fusion technique associated with percutaneous pedicle screws in micro endoscopy discectomy. *Zhonghua Yi Xue Za Zhi*. 2017;97(11):864–868. doi:10.3760/cma.j.issn.0376-2491.2017.11.014
4. Ahn J, Tabaraee E, Singh K. Minimally invasive transforaminal lumbar interbody fusion. *J Spinal Disord Tech*. 2015;28(6):222–225. doi:10.1097/BSD.0000000000000289
5. Tan JH, Liu G, Ng R, Kumar N, Wong H-K, Liu G, et al. Is MIS-TLIF superior to open TLIF in obese patients? A systematic review and meta-analysis. *Eur Spine J*. 2018;27(8):1877–1886. doi:10.1007/s00586-018-5630-0
6. Zhao Y, Liang Y, Mao K. Radiographic and clinical outcomes following MIS-TLIF in patients with adult lumbar degenerative scoliosis. *J Orthop Surg Res*. 2018;13(1):93. doi:10.1186/s13018-018-0764-7
7. Omar A, Ecternacht S, Kurucan E, Jubril A, Mesfin A, et al. Do surgical site infection rates differ among microscope-assisted versus loupe-assisted lumbar discectomies? *Clin Spine Surg*. 2020;33(4):E147–E150. doi:10.1097/BSD.0000000000000937
8. Weiner BK, Kilgore WB. Bacterial shedding in common spine surgical procedures: headlamp/loupes and the operative microscope. *Spine (Phila Pa 1976)*. 2007;32(8):918–920. doi:10.1097/01.brs.0000259837.54411.60
9. Basques BA, Golinvaux NS, Bohl DD, et al. Use of an operating microscope during spine surgery is associated with minor increases in operating room times and no increased risk of infection. *Spine (Phila Pa 1976)*. 2014;39(22):1910–1916. doi:10.1097/BRS.0000000000000558
10. Burkus JK, Foley K, Haid RW, LeHuec JC, et al. Surgical interbody research group—radiographic assessment of interbody fusion devices: fusion criteria for anterior lumbar interbody surgery. *Neurosurg Focus*. 2001;10(4):E11. doi:10.3171/foc.2001.10.4.12
11. Kroeze RJ, Graat HCA, Pluymakers WJ, et al. Interobserver and intraobserver reliability in the radiologic assessment of

lumbar interbody fusion. *Clin Spine Surg.* 2017;30(6):E853–E856. doi:10.1097/BSD.0000000000000423

12. Hari A, Krishna M, Rajagandhi S, Rajakumar DV, et al. Minimally invasive transforaminal lumbar interbody fusion-indications and clinical experience. *Neurol India.* 2016;64(3):444–454. doi:10.4103/0028-3886.181536

13. Adogwa O, Elsamadicy A, Reiser E, et al. Comparison of surgical outcomes after anterior cervical discectomy and fusion: does the intra-operative use of a microscope improve surgical outcomes. *J Spine Surg.* 2016;2(1):25–30. doi:10.21037/jss.2016.01.04

14. Davidson BJ, Guardiani E, Wang A. Adopting the operating microscope in thyroid surgery: safety, efficiency, and ergonomics. *Head Neck.* 2010;32(2):154–159. doi:10.1002/hed.21157

15. Ehanire T, Singhal D, Mast B, Leyngold M, et al. Safety of microsurgery under loupes versus microscope: a head-to-head comparison of 2 surgeons with similar experiences. *Ann Plast Surg.* 2018;80(6S Suppl 6):S340–S342. doi:10.1097/SAP.0000000000001324

**Funding:** The authors received no financial support for the research, authorship, and/or publication of this article.

**Declaration of Conflicting Interests:** The authors report no conflicts of interest in this work.

**Ethics Approval:** The Human Investigation Committee of Faculty of Medicine, Chulalongkorn University Institutional Review Board (IRB) approved this study. The approval number is 354/61. The written informed consent was waived.

**Corresponding Author:** Worawat Limthongkul, Department of Orthopedics, Faculty of Medicine, Chulalongkorn University, Bangkok, 1873 Rama IV Rd, Pathumwan, Bangkok, Thailand; dr.worawat@gmail.com

Published 16 May 2022

This manuscript is generously published free of charge by ISASS, the International Society for the Advancement of Spine Surgery. Copyright © 2022 ISASS. To see more or order reprints or permissions, see <http://ijssurgery.com>.