

Diffuse Sarcoidosis Presenting as Metastatic Malignant Disease-Like Picture: A Case Report

Ahmad Alelaumi, Mohammad Alfawareh, Ismail Althunibat, Akram Al-Ibraheem and Fareed Barakat

Int J Spine Surg published online 24 July 2023
<https://www.ijssurgery.com/content/early/2023/07/20/8523>

This information is current as of September 15, 2024.

Email Alerts Receive free email-alerts when new articles cite this article. Sign up at:
<http://ijssurgery.com/alerts>

Diffuse Sarcoidosis Presenting as Metastatic Malignant Disease-Like Picture: A Case Report

AHMAD ALELAUMI, MD¹; MOHAMMAD ALFAWAREH, MD¹; ISMAIL ALTHUNIBAT, MD¹;
AKRAM AL-IBRAHEEM, MD²; AND FAREED BARAKAT, MD³

¹Department of Orthopedics and Spine Surgery, King Hussein Cancer Center, Amman, Jordan; ²Department of Nuclear Medicine, King Hussein Cancer Center, Amman, Jordan; ³Department of Pathology, King Hussein Cancer Center, Amman, Jordan

ABSTRACT

Background: Sarcoidosis is a chronic inflammatory condition characterized by the formation of granulomas, which can impact various organs and tissues throughout the body. It frequently affects the lungs and mediastinal lymph nodes. The presence of multiple lytic lesions in the spine can be concerning, as it may indicate an undiagnosed or advanced metastatic malignancy. We present an unusual and interesting case of sarcoidosis in which the patient had multiple lytic lesions in the vertebrae, which resembled the presentation of metastatic malignant disease.

Case Description: A 46-year-old woman with no known medical history presented to our cancer center complaining of neck pain and bilateral shoulder pain. After conducting extensive investigations, an atypical manifestation of sarcoidosis was identified. The patient was administered corticosteroids, which effectively managed the disease and resulted in a substantial improvement in her symptoms.

Conclusions: Before considering surgical intervention or radiotherapy for cases involving multiple lytic lesions in the spine with an unknown primary cause, it is essential to conduct a comprehensive diagnostic evaluation. This thorough work-up is necessary to establish a clear diagnosis. If the patient's neurological condition permits, a complete assessment can help prevent substantial morbidity. In certain cases, a patient's condition may involve an atypical manifestation of pathologies that are not related to metastatic diseases, suggesting that simpler treatment approaches might be adequate.

Case Report

Keywords: sarcoidosis, spine, metastasis

INTRODUCTION

Sarcoidosis is a systemic disease that typically affects multiple organs, with the lungs being involved in more than 90% of cases. The noncaseating granuloma is the hallmark of sarcoidosis.¹ Skeletal system involvement in sarcoidosis has been reported to range from less than 1% to 13% of cases.^{1,2} Small bones of the hands are the usually affected bones, and spinal involvement is rare.³

The prevalence of sarcoidosis varies regionally, with different geographic areas showing different rates. In East Asia, the prevalence is reported to be around 1–5 cases per 100,000 population, while in cold countries such as Sweden and Canada, the prevalence is higher, ranging from 140 to 160 cases per 100,000 population.⁴ In the Middle East, there is a single study from Saudi Arabia that estimated the prevalence of sarcoidosis to be approximately 13 cases per 100,000 population.⁵ Among different ethnic groups, the highest incidence of sarcoidosis has been reported in African Americans at approximately 17.8 cases per 100,000 population per year, with even higher rates observed in African American women. In Scandinavian populations, such as in

Sweden, the incidence of sarcoidosis is lower, with an estimated rate of 11.5 cases per 100,000 population per year.^{6,7} A total of 70% of cases present between the ages of 30 and 50 years.⁸

Due to its multisystemic nature, sarcoidosis has the potential to affect any organ within the body. Systemic symptoms such as fatigue are present in nearly 70% of cases. The lungs are the most commonly affected site in sarcoidosis, and in up to 91% of cases, involvement of the lungs can be detected on chest radiography, regardless of the presence or absence of respiratory symptoms. Erythema nodosum is the most frequently observed extrapulmonary manifestation of sarcoidosis with an incidence rate of approximately 40%.⁹

To diagnose sarcoidosis, it is necessary to have both the clinical presentation consistent with the disease and the presence of noncaseating granulomas in one or more tissue samples. Additionally, it is crucial to rule out other potential causes of granulomatous diseases in order to confirm the diagnosis of sarcoidosis. In certain cases where there is a typical presentation of Löfgren syndrome or Heerfordt syndrome, the diagnosis of

sarcoidosis can be made without requiring a tissue sample.¹⁰ Lofegren syndrome is a form of acute sarcoidosis that presents as fever, hilar lymphadenopathy, peripheral arthropathy, and erythema nodosum.¹¹ Herfordet syndrome is a form of subacute sarcoidosis characterized by anterior uveitis, facial nerve palsy, and salivary gland enlargement.¹²

Key findings

- In rare cases of sarcoidosis, the symptoms and presentation may closely resemble those of metastatic malignant disease affecting the spine. Therefore, it is crucial to include sarcoidosis in our differential diagnosis list.

What is known and what is new?

- Sarcoidosis can involve the spine and presents in a picture of multiple lytic lesions. However, it is worth noting that the extent of lytic lesions observed in the presented case is not typically seen in sarcoidosis.
- This case report highlights the significance of conducting a comprehensive work-up before proceeding with invasive interventions whenever possible. Providers must consider the patient's neurological condition and the atypical presentation of sarcoidosis.

What is the implication, and what should change now?

- Attaining a diagnosis should involve various modalities in cases of multiple lytic lesions in the spine before providing treatment to enable precise and adequate management.
- Diagnosing the primary pathology can potentially spare the patient from undergoing invasive treatments such as extensive surgeries and radiotherapy.

CASE DESCRIPTION

A previously healthy 46-year-old woman sought medical attention at our center due to a 5-month history of neck pain accompanied by bilateral shoulder pain. The symptoms were initially mild but gradually increased

over time. At the time of presentation, the patient experienced constant severe pain that worsened with any movement of the neck. Coughing, simple movement, and even speaking with a high-pitched voice were associated with an increased intensity of pain. She applied a soft neck collar to decrease neck movement and pain.

Physical examination findings were significant for pain with neck hyperextension and radiation to both shoulders. There was no weakness and no hyperreflexia. Upon review of the systems, no other notable abnormalities were found, and the patient's vital signs were within normal ranges. She did not have any visual symptoms, erythema nodosum, or gastrointestinal symptoms. The patient had previously undergone contrast-enhanced whole spine magnetic resonance imaging (MRI) at another hospital, which revealed findings suggestive of metastatic cancer with an unknown primary source. Consequently, she was referred to our center for further evaluation and management.

The whole spine MRI showed multiple vertebral lesions involving the anterior bodies and posterior arches associated with soft tissue components that are highly suggestive of bony metastases. Lesions were seen at the anterior body and posterior arch of C2 extending into the dens, C3 body, C4 body, T1 body, T4 left transverse process and costovertebral junction, T6 vertebral body, and sternum. The C4 lesion was associated with a large soft tissue component with epidural extension severely compressing the thecal sac and spinal cord. Lesions at the C2 and C3 levels were associated with

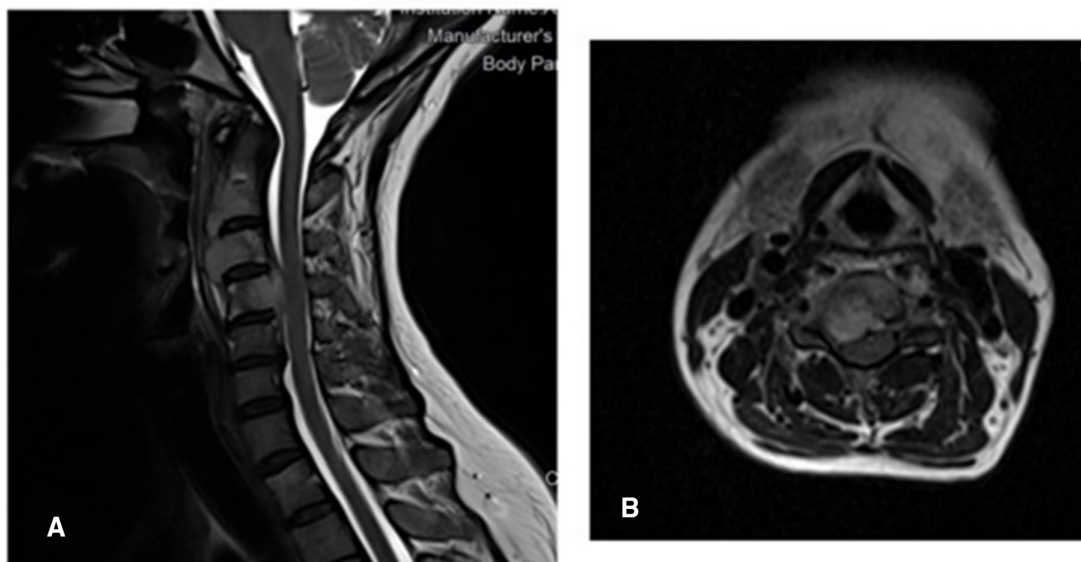


Figure 1. (A) T2-weighted magnetic resonance image (MRI) of the cervical spine with sagittal cut showing body involvement at C2, C3, and C4 with the anterior soft tissue component at C2 and C3. (B) T2-weighted MRI of the cervical spine with axial cut at the C4 level showing significant epidural soft tissue component and epidural spinal cord compression grade 3 at the C4 level.

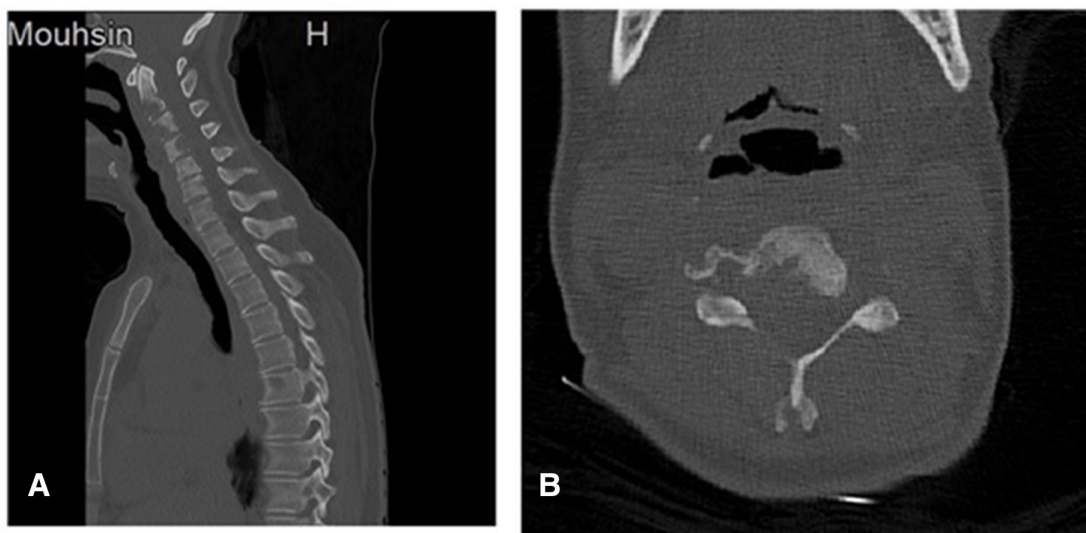


Figure 2. (A) Whole spine computed tomography (CT) image with sagittal cut showed the lytic lesions in C2, C3, C4, and T6. (B) CT image with axial cut at the C4 level showed the lytic lesion involvement of the posterior cortex of C4.

anterior soft tissue components bulging into the oropharynx (Figure 1).

Considering the patient's severe pain and the potential for neurological deterioration and the development of motor weakness, she was admitted for close monitoring and to complete her investigations in the shortest duration possible.

The administration of dexamethasone treatment was temporarily held until the completion of the patient's diagnostic work-up to prevent masking of the underlying diagnosis. Neurological examinations were conducted frequently on a daily basis to closely monitor any potential deterioration in the patient's neurological status that might require immediate surgical intervention. Whole spine computed tomography (CT) was done to assess spine stability and showed that the previously mentioned lesions in the MRI images were lytic. Spinal instability neoplastic score (SINS) was calculated at C2 and was 9 (potentially unstable), at C3 and was 7 (potentially unstable), and at C4 and was 8 (potentially unstable) (Figure 2).

The laboratory evaluation revealed the following results: an elevated erythrocyte sedimentation rate of 103 mm/h (reference range: 0–20), a minimally elevated platelet count of 459×10^3 (reference range: 150–400), a decreased hemoglobin level of 9.7 g/dL (reference range: 12–16), and normal white blood cell count and blood film. Further laboratory testing revealed an elevated total protein level of 8.5 g/dL (reference range: 6.2–8.2) and a low albumin level of 3.9 g/dL (reference range: 4.1–5). However, the liver function test, alkaline

phosphatase, and lactate dehydrogenase results were within the normal range.

Serum protein electrophoresis (SPEP) and bone marrow aspiration were performed due to the elevated total protein levels. The SPEP results showed an increased level of alpha 2 globulin and a polyclonal increase in gamma globulin, which is consistent with acute or subacute inflammation. No monoclonal bands were detected by the immunofixation test. The bone marrow aspirate and biopsy revealed a reactive bone marrow with trilineage hematopoiesis and maturation. There was no morphological evidence of metastatic disease, focal lesions, or infiltrative bone marrow disease. Tumor markers were assessed, and they showed mildly elevated levels of cancer antigen 15–3 (41.2 U/mL, reference range: 0–34.5) and CA 19.9 (41.9 U/mL, reference range: 0–27). However, the carcinoembryonic antigen level was within the normal range (1.08 ng/mL). Angiotensin-converting enzyme was also measured, and the result was within the normal range at 30 U/L (reference range: 8–52).

Breast mammography was reported as BIRADS 2 (benign findings), and breast ultrasonography findings were reported as normal.

The neck and chest CT findings showed the presence of consolidative nodules in the upper lung lobes, lingula, and right middle lung lobe. Additionally, there were scattered patchy areas of ground glass opacities in both lower lung lobes. These findings suggest an inflammatory or infectious process within the lungs. No significant enlargement of thoracic or axillary lymph nodes was observed. The abdominal and pelvic CT scan showed a soft tissue mass lesion measuring

2.7 × 2.6 × 4.5 cm located in the right root of the mesentery, adjacent to the iliac vessels, which were found to be patent. Additionally, a few mesenteric lymph nodes were noted, with the largest measuring up to 0.7 cm in size. Considering the presence of the abdominal mesenteric mass, enlarged abdominal lymph nodes, and the need for further evaluation, a positron emission tomography-CT (PET-CT) scan was conducted to explore the possibility of a lymphoma diagnosis (Figure 3).

F-18 fluorodeoxyglucose whole-body PET-CT demonstrated hypermetabolic potentially malignant right paramedial abdominal mass lesion and multiple hypermetabolic lytic bone lesions (most with soft tissue components) along with hypermetabolic left lateral abdominal wall deposit, suggestive of the metastatic process. It also demonstrated a hypermetabolic segmental process affecting the ascending and transverse colon accompanied by minimal wall thickening. In the chest, there were mildly hypermetabolic bilateral pulmonary consolidations with ground glass opacities indicating an inflammatory or infectious process. A moderately hypermetabolic right upper cervical lymph node that may be inflammatory or infectious in nature was also shown.

Due to the presence of multiple small lesions and the potential risks associated with performing an image-guided biopsy on the large mesenteric mass, a biopsy was obtained from the most accessible site, which was the vertebral body of T6. Additionally, a colonoscopy was scheduled to further evaluate the increased activity observed in the transverse and ascending colon as indicated by the PET-CT scan. Immediately following the vertebral body biopsy, the patient was started on high-dose dexamethasone (4 mg every 6 h). This approach is similar to cases of metastatic epidural spinal cord compression. The decision regarding further intervention, such as radiotherapy modalities or surgery, was to be determined based on the results of the biopsy. Two days after starting dexamethasone, the patient reported significant improvement in her symptoms.

The biopsy results from the T6 vertebral body showed the presence of granulomatous inflammation, predominantly noncaseating. The examined sections demonstrated vascularized tissue cores that were heavily infiltrated by noncaseating granulomas, with some areas showing focal necrosis. Special stains for acid-fast bacilli (Ziehl-Neelsen stain) and fungi (Grocott's Methenamine Silver stain) were negative. Immunostains for CD15, PAX-5, and CD30 were performed. Based on these findings, the differential diagnosis

included sarcoidosis as the top differential diagnosis (Figure 4).

The rheumatology team was consulted on the case, and they recommended the same dose of dexamethasone and that the patient follow up in the rheumatology clinic.

Before pursuing further intervention and because the symptoms were clearly improved 2 days after starting dexamethasone, whole spine MRI with contrast was repeated 6 days after starting dexamethasone and showed significant improvement in the soft tissue component that was compressing the cord at the C4 level (Figure 5).

As the patient's symptoms improved and her cord compression decreased with dexamethasone treatment, the patient was discharged to complete her follow-up on an outpatient basis at the spine and rheumatology clinics. A soft neck collar was used as a method of immobilization and was discontinued after 3 months.

The case was managed as a sarcoidosis case; colonoscopy was done after 2 weeks of dexamethasone treatment and showed normal colonic mucosa up to the cecum with no polyps or mass lesions. The dexamethasone dose was tapered gradually to 4 mg daily after 2 weeks of treatment.

Follow-up abdomen CT after 1 month of dexamethasone treatment revealed resolution of the previously noted right mesenteric soft tissue mass with stable diffuse small mesenteric lymph nodes enlargement. A follow-up whole spine MRI with contrast was conducted after 3 months of treatment (Figure 6). The results showed interval sclerosis and decreased enhancement of the lesions indicating improvement, and there was no evidence of extraosseous soft tissue extension or bone expansion observed.

The patient maintained regular follow-up appointments at the rheumatology and spine clinics for 8 months. During this period, the dose of dexamethasone was gradually tapered down to a daily dose of 0.5 mg. Additionally, methotrexate was introduced as part of her treatment plan.

During the most recent follow-up clinic visit, a CT scan was performed. The CT scan revealed that the lesions in the chest and abdomen had completely resolved. Additionally, the lytic lesions in the spine showed partial calcification, suggesting a process of healing (Figure 7).

Cervical spine x-ray imaging was done and showed a well-aligned and symmetric vertebral column. The vertebral bodies showed smooth and regular contours

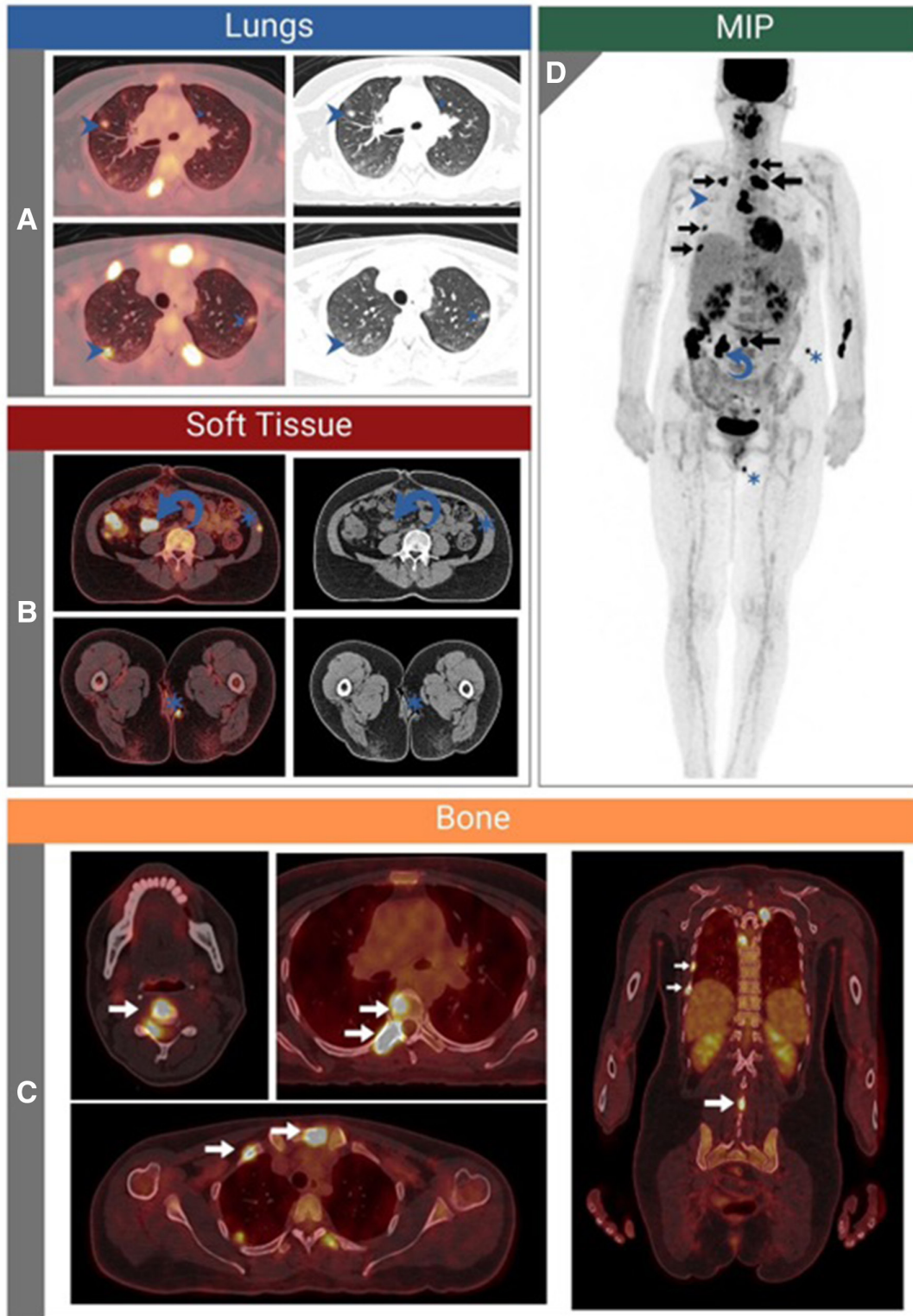


Figure 3. (A) Axial positron emission tomography-computed tomography (PET-CT) and axial CT images demonstrated multiple hypermetabolic pulmonary nodules and ground glass opacities involving both lung fields (blue arrowheads). (B) Axial PET-CT and axial CT images demonstrated a large hypermetabolic abdominal mass lesion occupying the right paramedian region (blue curved arrow) along with evidence of 2 subcutaneous nodules involving the left lateral abdominal wall and left inner thigh (blue asterisk). (C) Axial PET-CT images and coronal PET-CT images demonstrated multiple hypermetabolic lytic bone lesions involving the sternum, right 1st, 7th, and 8th ribs, as well as T6, L3 vertebrae, and the most prominent C4 vertebral body lesion (white arrows). (D) Maximum intensity projection image demonstrated a hypermetabolic process involving bilateral pulmonary nodules (blue arrowheads), abdominal mass lesion (blue curved arrow), 2 skin nodules (blue asterisk), and multiple lytic bone lesions (black arrows). The overall picture was potentially suspicious, necessitating tissue confirmation by biopsy to exclude malignant pathology.

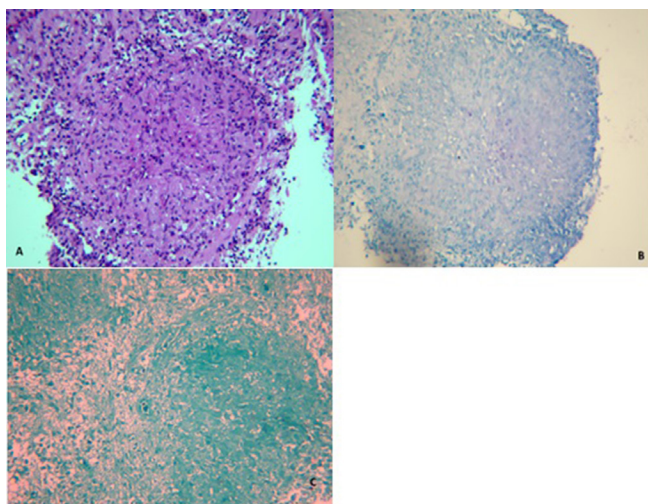


Figure 4. (A) Histopathologic finding of noncaseating granuloma. (B) Negative staining by Ziel-Neelsen. (C) Negative staining by Grocott's Methenamine Silver stain.

without any signs of fractures, deformities, or bone abnormalities (Figure 8).

DISCUSSION

This case serves as an example of a diagnostic dilemma. However, the crucial aspect of the case was the cautious approach taken, avoiding hasty administration

of dexamethasone, radiotherapy, or surgical intervention in the absence of a clear diagnosis and comprehensive evaluation, as long as the patient's condition permitted such an approach. Administering dexamethasone directly without a clear diagnosis could have potentially led to a negative biopsy result, and proceeding with surgery or radiotherapy without a definitive diagnosis might have resulted in significant morbidity.

Given the patient's condition, which allowed for further investigation, regular neurological examinations were crucial to closely monitor any changes in neurological status. In the event of any deterioration, urgent surgical intervention might have been necessary to prevent neurological deficits.

Central nervous system involvement in sarcoidosis is a recognized manifestation, often affecting the cranial nerves. However, it is important to note that a presentation of sarcoidosis mimicking metastatic cancer is an exceedingly rare occurrence. While sarcoidosis can affect multiple organs and systems, including the skeletal system and the spine, extensive involvement resembling metastatic cancer is uncommon highlighting the diverse and sometimes unexpected clinical manifestations of the disease. This article highlights the significance of conducting a comprehensive work-up in patients presenting with a clinical picture suggestive of

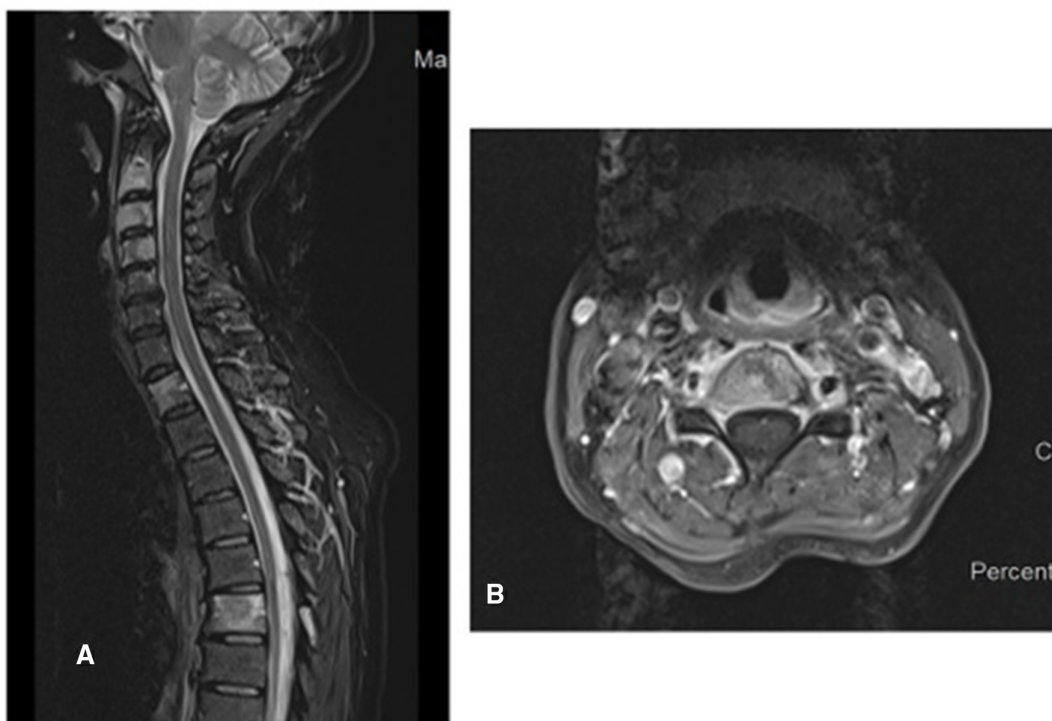


Figure 5. (A) T2-weighted magnetic resonance image (MRI) of the cervical spine with sagittal cut showed significant improvement in the soft tissue components at C2, C3, and C4. (B) T1-weighted MRI of the cervical spine with axial cut at the C4 level showed near resolution of the significant epidural soft tissue component and epidural spinal cord compression at the C4 level.

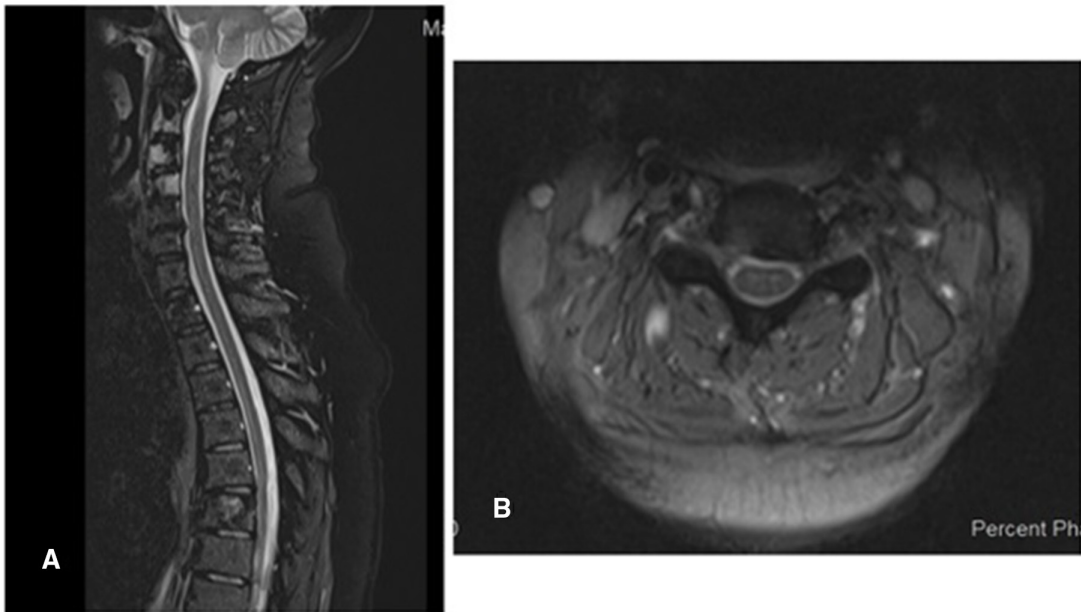


Figure 6. Three months after treatment. (A) T2-weighted magnetic resonance image (MRI) of the cervical spine with sagittal cut. (B) T2-weighted MRI of the cervical spine with axial cut at the C4 level revealed interval sclerosis and decreasing enhancement of the lesions at C2, C3, C4, T1, and T6.

metastatic spinal cord compression. By emphasizing the importance of a thorough evaluation, accurate diagnosis can be achieved, enabling appropriate and targeted treatment strategies. This approach is crucial to prevent subjecting patients to unnecessary interventions such as surgery or radiotherapy, thus minimizing potential risks and optimizing patient care.

During the diagnostic process, various potential causes of noncaseating granulomas were carefully considered and explored to ensure an accurate diagnosis. Infectious causes, such as atypical mycobacterial or fungal infections, were ruled out due to the absence of systemic symptoms, stable vital signs, and the significant improvement observed with dexamethasone

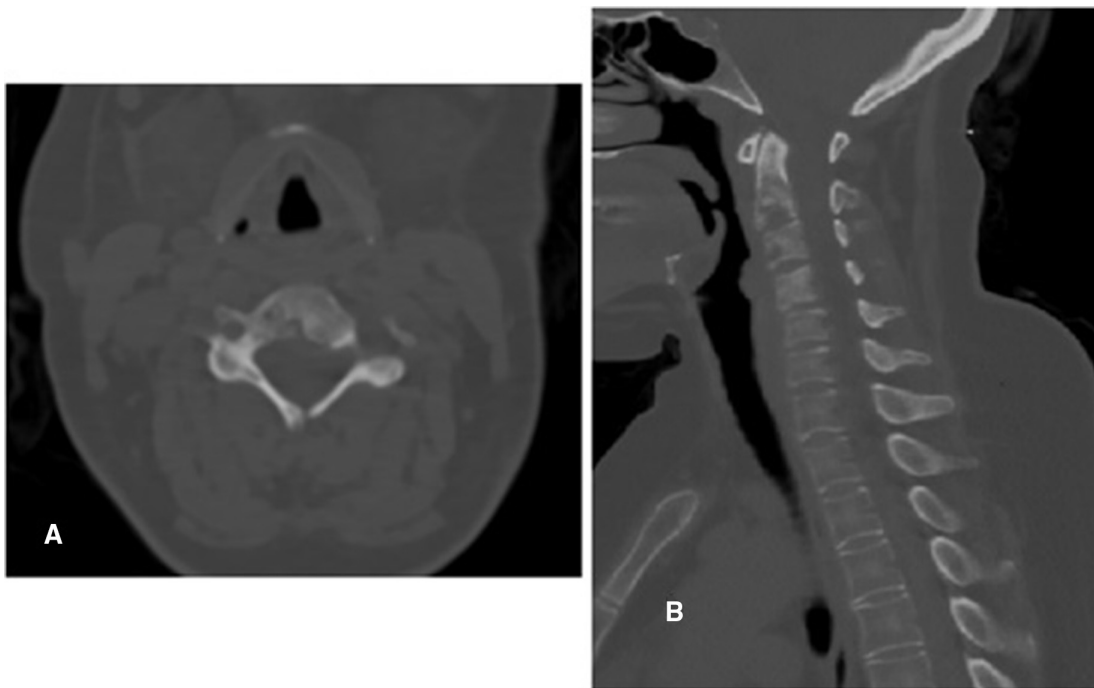


Figure 7. Eight months after treatment. (A) Spine computed tomography (CT) image with axial cut showed partial calcification of the lytic lesion in C4. (B) CT image with sagittal cut showed partial calcifications in the other lesions.

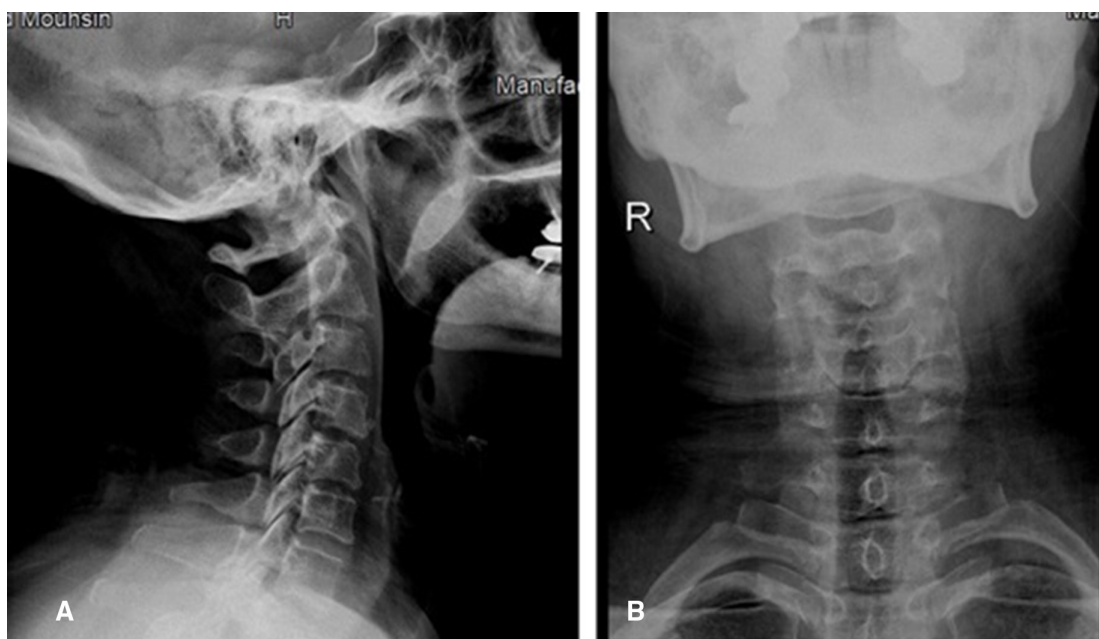


Figure 8. Eight months after treatment, lateral (A) and anteroposterior (B) cervical spine x-ray images showed normal findings.

treatment. Malignant causes were excluded based on the biopsy results and the subsequent regression of lesions with immunosuppressive treatment. Other possible causes, including berylliosis, foreign body reaction, and drug reaction, were eliminated based on the absence of relevant exposure history. Crohn's disease was considered in the differential diagnosis; however, the absence of gastrointestinal symptoms and normal colonoscopy findings made it less likely. Throughout the presentation and follow-up period, the patient did not report any gastrointestinal symptoms, further supporting the exclusion of Crohn's disease. It is important to note that other conditions may present with typical manifestations that are distinct from the reported case.

The SINS is a mechanical scoring system used to assess the stability of spinal metastases. It helps guide treatment decisions, particularly regarding the need for surgical intervention. However, in the case described, since the diagnosis turned out to be benign (sarcoidosis), a more conservative approach was taken. This decision was based on the complexity of surgical intervention and the potential risks involved. Instead, the patient was closely monitored with regular follow-ups to evaluate the response to conservative treatment and ensure the stability of the spine.

The present report has certain limitations, including a relatively brief 8-month follow-up period, necessitating ongoing patient monitoring. Additionally, the utilization of anabolic or anticatabolic medications may have contributed to hastened calcification in the bone lesions and this was not used. Moreover, the use of a soft neck

collar for immobilization, although it may be effective in symptom alleviation, could have been substituted with a more rigid form of immobilization to ensure stability and minimize the likelihood of fractures.

The aim of this study is to highlight the ongoing difficulty in diagnosing sarcoidosis, primarily due to its ability to imitate different diseases and manifestations, as well as its tendency to exhibit atypical presentations.

REFERENCES

1. Llanos O, Hamzeh N. Sarcoidosis. *Med Clin North Am.* 2019;103(3):527–534. doi:10.1016/j.mcna.2018.12.011
2. Dempsey OJ, Paterson EW, Kerr KM, Denison AR. Sarcoidosis. *BMJ.* 2009;339:bmj.b3206. doi:10.1136/bmj.b3206
3. Neville E, Carstairs LS, James DG. Bone sarcoidosis. *Ann N Y Acad Sci.* 1976;278:475–487. doi:10.1111/j.1749-6632.1976.tb47060.x
4. Arkema EV, Cozier YC. Sarcoidosis epidemiology: recent estimates of incidence, prevalence and risk factors. *Curr Opin Pulm Med.* 2020;26(5):527–534. doi:10.1097/MCP.0000000000000715
5. Al-Khouzaie TH, Al-Tawfiq JA, Al Subhi FM. Sarcoidosis in the eastern region of Saudi Arabia. *Ann Thorac Med.* 2011;6(1):22–24. doi:10.4103/1817-1737.74272
6. Baughman RP, Field S, Costabel U, et al. Sarcoidosis in America: analysis based on health care use. *Ann Am Thorac Soc.* 2016;13(8):1244–1252. doi:10.1513/AnnalsATS.201511-760OC
7. Cozier YC, Berman JS, Palmer JR, Boggs DA, Serlin DM, Rosenberg L. Sarcoidosis in black women in the United States: data from the black women's health study. *Chest.* 2011;139(1):144–150. doi:10.1378/chest.10-0413
8. Hunninghake G, Costabel U. Statement on sarcoidosis. *Am J Respir Crit Care Med.* 1999;160:20. doi:10.1034/j.1399-3003.1999.14d02.x

9. Mañá J, Rubio-Rivas M, Villalba N, et al. Multidisciplinary approach and long-term follow-up in a series of 640 consecutive patients with sarcoidosis: cohort study of a 40-year clinical experience at a tertiary referral center in Barcelona, Spain. *Medicine (Baltimore)*. 2017;96(29):e7595. doi:10.1097/MD.00000000000007595

10. Sève P, Pacheco Y, Durupt F, et al. Sarcoidosis: a clinical overview from symptoms to diagnosis. *Cells*. 2021;10(4):766. doi:10.3390/cells10040766

11. Hebel JL, Snider RL, Mitchell D. Lofgren's syndrome. *Cutis*. 1993;52(4):223–224.

12. Fraga RC, Kakizaki P, Valente NYS, Portocarrero LKL, Teixeira MFS, Senise PF. Do you know this syndrome? Heerfordt-waldenström syndrome. *An Bras Dermatol*. 2017;92(4):571–572. doi:10.1590/abd1806-4841.20175211

Funding: The authors received no financial support for the research, authorship, and/or publication of this article.

Declaration of Conflicting Interests: The authors report no conflicts of interest in this work.

Disclosures: Akram Al-Ibraheem reports a grant/contract from the International Atomic Energy Agency (chief investigator of a coordinated research project on PSMA PET/CT in high-risk prostate cancer); expert

fees from the World Health Organization and the International Atomic Energy Agency; and leadership roles in the Jordanian Society of Nuclear Medicine and the Asia Oceania Federation of Nuclear Medicine. The remaining authors have nothing to disclose.

Author Contributions: A. Alelaumi and I. Althunibat conducted data collection; all authors contributed to data analysis and manuscript preparation; and all authors reviewed the results and approved the final version of the manuscript.

Corresponding Author: Ahmad Alelaumi, Department of Orthopedic Surgery, King Hussein Cancer Center, Amman, Jordan; ahmadalelaumi@gmail.com

This manuscript is generously published free of charge by ISASS, the International Society for the Advancement of Spine Surgery. Copyright © 2023 ISASS. To see more or order reprints or permissions, see <http://ijssurgery.com>.