

The Correlation Between Paraspinal Muscular Morphology, Spinopelvic Parameters, and Back Pain: A Comparative Cohort Study

Enrico Giordan, Giacomo Drago, Roberto Zanata, Elisabetta Marton and Jacopo Del Verme

Int J Spine Surg published online 6 October 2023
<https://www.ijssurgery.com/content/early/2023/10/05/8531>

This information is current as of July 18, 2024.

Email Alerts Receive free email-alerts when new articles cite this article. Sign up at:
<http://ijssurgery.com/alerts>

The Correlation Between Paraspinal Muscular Morphology, Spinopelvic Parameters, and Back Pain: A Comparative Cohort Study

ENRICO GIORDAN, MD¹; GIACOMO DRAGO, MD²; ROBERTO ZANATA, MD¹; ELISABETTA MARTON, MD²; AND JACOPO DEL VERME, MD¹

¹Neurosurgical Department, Aulss2 Marca Trevigiana, Treviso, Italy; ²Department of Neuroscience, University of Padova, Padova, Italy

ABSTRACT

Background: The relationship between paraspinal muscle degeneration and low back pain (LBP), disability, and structural changes has been investigated in the literature, but it is still a matter of debate. We differentiated paraspinal muscle magnetic resonance imaging by quality and quantity, focusing on fatty infiltration (FI) and paraspinal muscles cross-sectional area (CSA) from T12 to S1 in patients with and without chronic LBP. We aimed to determine whether paraspinal muscle quantity (CSA) and quality (FI) are positively associated with LBP or degenerative/spinopelvic changes in the spine.

Methods: Between 2018 and 2021, we prospectively enrolled 205 patients aged between 18 to 65 years, of whom 153 patients had chronic back pain (back pain group) and 52 patients did not have chronic back pain (no back pain group), and collected clinicodemographic, structural, and spinopelvic data. We correlated these data with paraspinal muscle FI and CSA from T12 to S1. Multivariate models were run to highlight associations between pain, disability, or degenerative and spinopelvic parameters.

Results: Age was not associated with increased FI but consistently with decreased CSA values. After adjusting for age, sex, and body mass index, FI was associated with an increased risk of back pain (OR, 8.80; 95% CI, 1.9–39.79; $P = 0.006$) and high disability scores (OR, 3.41; 95% CI, 1.12–10.30; $P = 0.030$). Decreased CSA was associated with reduced disc height ($P < 0.001$), while FI and CSA did not associate with abnormal spinopelvic parameters.

Conclusions: FI on paraspinal muscle highly correlates with back pain and disability but was not found in structural and degenerative changes in the lower back.

Clinical Relevance: Findings from this study are clinically relevant for patient counseling and rehabilitation strategies.

Level of Evidence: 2b.

Biomechanics

Keywords: spine, muscle, fat infiltration, aging, degenerative, back pain

INTRODUCTION

The etiology of low back pain (LBP) is multifactorial, and paraspinal muscle composition has often been questioned as a predictor of degenerative changes or as a pain generator.^{1,2} Atrophy of the paraspinal muscles has been frequently found in patients with LBP, in the form of decreased cross-sectional area (CSA) of the multifidus (MF), erector spinae (ES), and psoas major (PM) muscles.³ The muscles' role in spine stability has also been questioned, with the MF muscle being the most critical for segmental stability by acting synergistically with ES and PM muscles.⁴ Another degenerative change that raised interest was the increased fat deposition reported in paraspinal muscles of LBP patients.^{2,3} Several authors have measured the muscles' CSA, density, or segmental fatty infiltration (FI) using computer tomography (CT) or magnetic resonance imaging (MRI).^{2,3,5–7}

Measuring the CSA as a surrogate for muscle atrophy fails to capture internal architectural derangements, such as fat replacement.^{5,7} Furthermore, a few authors have attempted a quantitative analysis of FI in the paraspinal muscle complex, mainly focusing on segmental analysis.⁷

We collected and analyzed clinical, structural, and spinopelvic parameters, such as intervertebral disc height, Modic changes, disc degeneration, stenosis degree, spondylolisthesis, lordosis, pelvic tilt (PT), and pelvic incidence (PI). They were then correlated with FI and paraspinal muscles CSA from T12 to S1 in patients with and without chronic LBP.

In the present study, we investigated whether paraspinal muscle composition, especially in terms of FI, is a factor associated with back pain (BP) and whether the degeneration of paraspinal lower back muscles is associated with degenerative changes of the spinal column.

We performed an extensive analysis that included a wide range of parameters because focusing only on one condition, such as muscle atrophy or FI, without also considering degenerative or spinopelvic changes may fail to catch possible interaction between different factors.

METHODS

Participants

Community-based adults were prospectively recruited and enrolled through neurosurgery outpatient clinics between 2018 and 2021. They were subdivided into 2 groups: patients with back pain (“back pain” group [BP]) and those without back pain (“no back pain” group [NBP]). Patients in the NBP group were referring to neurosurgical outpatient clinics for reasons other than back pain.

Participants in the BP group were recruited if they met the following criteria:

1. Age >18 years but <65 years
2. LBP (defined as value >5 on the visual analog scale [VAS] for more than 6 months) due to chronic degenerative disc disease alone or in combination with any of the following:
 - Degenerative lumbar spinal stenosis (grades I to III by Lee grading⁸);
 - Degenerative spondylolisthesis (grades I to II by Meyerding grading⁹)
 - Degenerate discs (ie, black disc; grades I [ie, normal disc] to V by Pfirrmann grading¹⁰)
 - Endplate degeneration (grades I to III by Modic grading¹¹)
 - BP is defined as a long-lasting ache, pain or discomfort, or debilitating suffering in the lumbar area and sometimes down to the buttocks and legs.
3. Pain duration >6 months
4. Lumbar spine MRI (from T12 to S1), including T1 and T2 weighted axial, sagittal, and coronal scans made within 4 weeks of the visit
5. No previous percutaneous procedures that could overestimate the MRI signal (ozonolysis, epidural injections, facets infiltrations, and full-endoscopic surgery)
6. Dynamic lumbar x-rays and standing lumbar x-rays
7. Normal serum levels of albumin, triiodothyronine and thyroxine, glucose, and a normal lipid profile

Patients were excluded if they had the following:

- Pure radicular pain or symptoms
- Nonspecific BP
- Acute BP
- Sedentary or inactive (ie, most of the time spent reclining, seated, or lying position requiring deficient energy expenditure), wheelchair-bound, or bedridden
- Migrated disc herniations
- History of back muscle trauma or contracture responding to physical therapy;
- Primitive or secondary spine tumor;
- Significant systemic condition
- Muscle atrophy due to systemic, neurological, or autoimmune disease;
- A history of discitis or paraspinal muscle infections/abscess
- Degenerative spondylolisthesis > grade II
- Isthmic spondylolisthesis
- Previous spine surgery
- Posttraumatic or pathological (ie, BP consequent to osteoporotic fractures) fractures at the lumbar level

Participants in the NBP group were recruited if they met the following criteria:

1. Age >18 years but <65 years
2. No BP in the past 24 months
3. Lumbar spine MRI (from T12 to S1), including T1- and T2-weighted axial, sagittal, and coronal scans
4. Any other reason to undergo an MRI scan not listed in the exclusion criteria above

Data Collection

We collected data on age and sex for both groups of patients and anthropometric values. In addition, we collected diagnoses and at-visit conclusions for LBP patients (conservative vs surgical treatment).

To diagnose chronic BP, we adopted a 6-month span in which the patient, when possible, was advised to participate in physical and rehabilitation therapy. We believed that in 6 months, lumbar contracture or muscle damage consequent to sprains had the time to heal, thus reducing possible bias in patient selection. Also, MRI was asked to be not older than 4 weeks to clearly understand the muscles near time of enrollment and after chronic pain was established.

Patients included in the NBP group were patients who came to our attention because of complaints

unrelated to BP and who underwent spine MRI because of other reasons (ie., suggested by general practitioner, suspected spine localization of primitive tumors, spinal arteriovenous malformations, follow-up in mild spine trauma, dissemination of brain tumors, etc).

The 65-year age cut-off was decided because we did not want to include patients at higher risk of age-related sarcopenia. Muscle mass decreases approximately 3% to 8% per decade after age 30 years. This rate of decline is even higher after age 65 years, either as a consequence of menopause or andropause.¹² Indeed, considering the natural and involuntary loss of muscle mass, we found that such an age cut-off will allow for less biased analysis.

Body mass index (BMI; kg/m^2) was calculated by dividing weight (in kg) by square height (in meters; m^2). $\text{BMI} \geq 30 \text{ kg}/\text{m}^2$ was considered obesity.

Pain was assessed at the visit time by the VAS,¹³ while the Oswestry Disability Index (ODI) questionnaire was used for disability assessment.¹⁴ The ODI is a self-administered questionnaire that measures back-specific function using 10-items with 6 response categories. Each item is scored from 0 to 5, and the summation of scores is converted into a total score of 0 to 100. The ODI score is subdivided into minimal, moderate, severe, cripple, and total (bedridden) disability. High disability grades were considered severe to total disability (40–100).

CSA, Muscle Volume, and FI Calculations

MRI was performed using a 3T magnetic resonance unit (Siemens Healthineers Magnetom Vida 3T MRI). The participant was positioned supine, and the following isovolumetric (3D) scans were performed: sagittal and axial T1- and T2-weighted images (slice thickness: 1 mm) from T12 to the sacrum (S1). Paraspinal muscle CSA, FI, and muscle volume (MV) were determined from T12 to S1. At the midpoint of each disc level (L1–L2, L2–L3, L3–L4, L4–L5, and L5–S1), the CSA of the MF, ES, and PM muscles were measured by outlining each muscle's border at each disc level from T12 to S1, using drawing tools in Slicer 3D. We then calculated mean values by adding level values and dividing them by 5. The MF and ES muscle (ie, the paraspinal muscle complex) total muscle volume (TMV) was measured in a semiquantitative way by contouring each muscle for each orthogonal plane (sagittal, coronal, and axial) from T12 to S1 using the Slicer 3D “volume rendering” module and drawing tools and then interpolating them in a 3-dimensional model. Slicer 3D is a free software for medical imaging analysis with previously documented

and validated applications in the literature for spine segmentation and imaging elaboration.¹⁵ For volume calculation, a threshold was manually determined based on T2-weighted signal intensity volumetric MRI scans (1 mm of slice thickness) by manually instructing the software to recognize fat hyperintense regions within the paraspinal muscles.¹⁶ MV was calculated using the following equation: $\text{TMV} - \text{FI} = \text{MV}$ (Figure 1).

Degenerative Changes

Intervertebral disc height was measured on midsagittal MRI from the middle of the superior border of the disc to the middle of the disc's inferior border with the inclusion of both endplates. The average disc height was obtained by summing disc height collected at each intervertebral disc: L1 to L2, L2 to L3, L3 to L4, L4 to L5, and L5 to S1 heights and dividing it by 5.

Modic change was classified according to the original system¹¹ into 3 types: Type 1: hypointense on T1 and hyperintense on T2 images; Type 2: hyperintense on T1 isointense/hyperintense on T2 images; and Type 3: hypointense on both T1 and T2 images. Images were assessed in the sagittal plane. Modic changes were investigated from T12 to S1, and each affected level and degree of change were collected according to the classification.

All MRI measurements were performed independently between 2 investigators (E.G. and G.D.). These measurements were repeated 2 times. The mean values of these measurements were then taken as the basis for the study analysis. When a significant difference was observed between the measurements of the 2 investigators, the 2 observers repeated these measurements together.

Stenosis degree was examined in all vertebral segments from T12 to S1 and collected from the most stenotic segment also according to the patient's symptoms and reported by Young grading.⁸

Spinopelvic Parameters Calculations

Patients were instructed to stand in a comfortable position with their hands resting on their clavicle. From the standing position spine radiograph, the following spinopelvic parameters were measured with the use of SurgiMap software (Nemaris, Inc.; Globus Medical Inc.): PI: the angle between the line perpendicular to the sacral plate at its midpoint and the line connecting this point to the axis of the femoral heads; lumbar lordosis (LL): the Cobb angle from the upper endplate of L1 to the lower endplate of S1; and PT: as the angle created by a

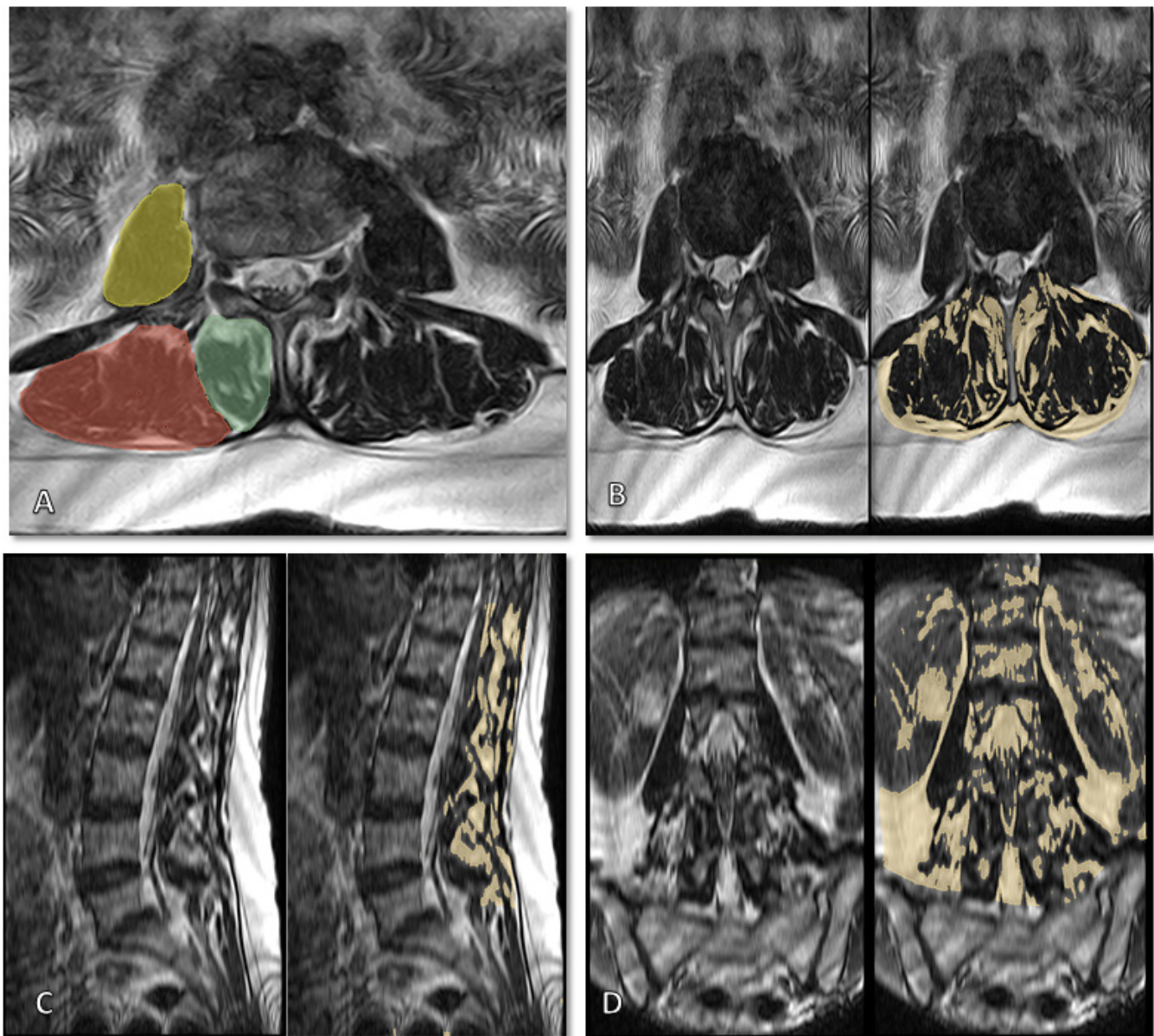


Figure 1. (A) Example of paraspinal muscle cross-sectional area segmentation at L4 to L5 level. The multifidus muscle segmentation is in green, the erector spinae in red, and the psoas major in yellow. (B) Axial T2-weighted scan. (C) Sagittal T2-weighted scan. (D) Coronal T2-weighted scan. MRI scan of the whole lumbar segment. On the left of each image is the MRI. On the right, semiquantitative contouring of fatty infiltration for 3-dimensional model building.

line running from the sacral endplate midpoint to the center of the bifemoral heads and the vertical axis. This study used the sagittal modifier of SRS Schwab classification¹⁷ to measure spine imbalance. When PI–LL is >10, it is defined as a spinopelvic mismatch.

Statistical Analysis

Before starting the data collection, we calculated the sample size for a proportion test with a significance of 0.05 and power of 0.8 to test the hypothesis that the minimal significant difference in FI between BP and

NBP patients would be evaluable only if at least 30% (the 30% cut-off value was derived from a previous study in which it was considered significant for FI).¹⁸ We found that the minimum sample size for statistical significance was at least 64 patients.

Descriptive statistics are reported as the median and interquartile range or mean and SD for continuous variables and proportions and percentages for categorical variables. The Mann-Whitney *U* or *t* test was used to analyze the continuous variables and the Fisher exact test for the categorical variables. Multiple univariate logistic regression models were used between outcomes

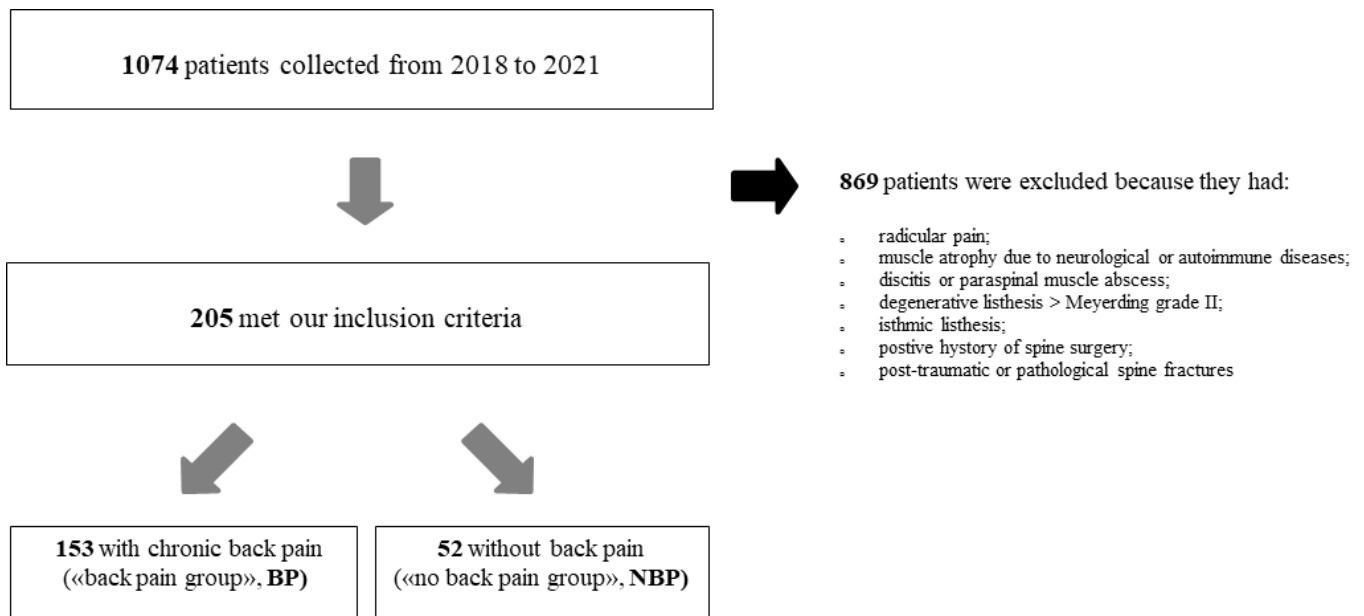


Figure 2. Flow chart of the patients' selection process.

(BP, FI, and CSA; independent variables) and dependent variable (ie, group [BP vs NBP], age, sex, and BMI) to examine the relationships of paraspinal muscle CSA and FI with all structural (ie, disc height, disc degeneration, stenosis grade, spondylolisthesis grade, and Modic grade) and spinopelvic parameters (ie, LL, PT, PI, and pelvic mismatch). Multiple uni- and multivariate models were run for group comparisons of paraspinal muscle and spinopelvic parameters. Only multivariate significant findings were reported in the tables. Multivariate analyses were adjusted for dependent variables (age, gender, and BMI). The statistical tests were 2-tailed, and the alpha (α) level was set at 0.05. These analyses were performed using commercially available software (Stata 13.0, StataCorp, College Station, TX, USA).

RESULTS

Sample Demographics and Characteristics

After reviewing 1074 consecutive patients with BP in our outpatient visits between 2018 and 2021, we identified 205 patients who met our inclusion criteria. One hundred fifty-three patients were included in the BP group and 52 patients in the NBP group, as shown in Figure 2. Eight hundred and sixty-nine patients were excluded because they were not fulfilling out strict inclusion criteria (ie, 345 mixed radicular/BP; 225 no adequate imaging; 131 out of upper age limits; 168 post-traumatic, pathological BP of >grade II spondylolisthesis). Most of the patients enrolled (76.7%), either in the BP or NBP group, presented some degree of disc

degeneration alone or combined with other degenerative changes of the column (stenosis, listhesis, Modic changes, etc).

Overall, the median age at presentation was 53 years (interquartile range [IQR]: 41–65 years). The man-to-woman ratio was 1.2:1, and 45.7% of patients were woman. In the BP group, the median age was 56 years (IQR 52–65 years), and 48.4% were woman. More than half of patients (55.4%) underwent surgical treatment because of failed conservative strategies (ie, physical therapy and/or analgesics). The remaining patients insisted on medical and rehabilitation therapy or refused the proposed intervention. The mean VAS value was 6.8 (SD \pm 1.8), and the mean ODI was 45.2 (SD \pm 16.1). Almost one-third of patients were obese (33.6%, BMI > 30).

In the NBP group, the median age was 50 years (IQR: 41–58 years). The man-to-woman ratio was 1.6:1, and 37.5% were woman. One-fourth of the patients were obese (25%). The clinicodemographic characteristics of the 205 study participants are shown in Table 1.

Clinicodemographic, Structural, and Spinopelvic Parameters Comparison

Median age was lower for NBP patients compared with BP patients (50 vs 56 years, $P < 0.0001$), but there were no differences in terms of sex distribution between the 2 groups ($P = 0.163$). A significantly higher proportion of patients with Modic changes were primarily found in BP patients than in NBP

Table 1. Summary of clinicodemographic and structural parameters differences between groups.

Parameter	Back Pain (n = 153)	No Back Pain (n = 52)	P
Age y, median (IQR)	56 (52–65)	50 (41–58)	<0.0001
Male sex, %	52.3	62.5	0.163
Surgical treatment, %	55.4	-	-
VAS score, mean ± SD	6.8 ± 1.8	-	-
ODI score, mean ± SD	45.2 ± 16.1	-	-
Body mass index >30, %	33.6	25	0.249
Structural parameters			
Modic type, %			
Total	46.2	9.1	<0.0001
I	24.2	6.1	0.005
II	19.0	3.0	0.005
III	3.0	0	0.207
Listhesis grade, %			
Total	49.4	3.0	<0.001
I	42.4	3.0	<0.0001
II	7.0	0	0.048
Stenosis grade, %			
Total	66.0	30.3	<0.0001
I	9.9	24.2	0.009
II	28.8	6.1	0.001
III	27.3	0	<0.0001
Pfirrmann grade, %			
I	9.9	54.6	<0.001
II	31.1	36.4	0.482
III	38.6	6.0	<0.001
IV/V	20.4	3.0	0.003
Disc height, mm, mean ± SD	8.6 ± 1.8	10.1 ± 1.4	<0.0001

Abbreviations: IQR, interquartile range; ODI, Oswestry Disability Index; VAS, visual analog scale.

ones (46.2% vs 9.1%, $P < 0.0001$). Most of them were Modic I (24.2%). Almost half of the patients in the BP group had signs of degenerative spondylolisthesis compared with NBP patients (49.4% vs 3.0%, $P < 0.001$), and they were mostly in grade I spondylolisthesis (42.4%).

The prevalence of spinal stenosis in BP patients almost doubled NBP ones (66.0% vs 30.3%, $P < 0.0001$) and was distributed similarly between grades II to III in the BP group (28.8% and 27.3% for grades II and III, respectively), while it was for the majority grade I in the NBP group.

Disc degeneration was preponderantly higher in BP patients than in NBP patients ($P < 0.001$ and 0.003 for Pfirrmann grades III and IV, respectively). Mean disc height was slightly but significantly lower in the BP group (8.6 mm vs 10.1 mm, $P < 0.0001$), as well as mean CSA of ES (15.7 vs 17.1 cm², $P = 0.032$), MF (5.9 vs 6.9 cm², $P = 0.004$), and PM muscles (8.6 vs 10.8 cm², $P = 0.004$).

The percentage of pure paraspinal muscle (ie, homogeneous MRI intensity, without FI) volume was significantly higher in the NBP group compared with BP (80.9% vs 67.7%, $P < 0.0001$). Contrarily,

the mean percentage of FI was higher in the BP (32.4% vs 19.0%, $P < 0.0001$; Figure 3).

The BP group's mean PI values were significantly higher (54.4° vs 49.9°, $P = 0.044$) and PT (19.7° vs 13.7°, $P = 0.0001$) than NBP. Mean values of LL were not significantly different between groups (45.6° vs 51.2°, $P = 0.064$). The percentage of patients with a lordosis angle outside commonly reported age and sex confidence intervals in literature was higher in BP than in the NBP group (81.2% vs 55.6%, $P < 0.0001$). A higher percentage of patients in the BP group had a spinopelvic mismatch compared with the NBP (53.6% vs 9.6%, $P < 0.0001$). The distribution of the structural and spinopelvic characteristics between groups is shown in Table 2.

Multivariate Analysis Results

After adjusting for sex and BMI, increased age was independently associated with higher risk of decreased CSA for MF (OR, 1.06; 95% CI, 1.03–1.10; $P < 0.001$), ES (OR, 1.04; 95% CI, 1.02–1.08; $P = 0.002$), and PM muscles (OR, 1.07; 95% CI, 1.03–1.10; $P < 0.001$).

Female sex was associated with CSA reduction of MF (OR, 3.70; 95% CI, 1.70–8.06; $P = 0.001$), ES (OR, 7.20; 95% CI, 3.20–16.20; $P < 0.001$), and PM muscles (OR, 6.93; 95% CI, 2.94–16.35; $P < 0.001$). Also, female sex was associated with a higher risk of FI despite age or obesity status (OR, 2.88; 95% CI, 1.31–6.31; $P = 0.001$). Sex was not associated with an increased risk of structural or abnormal spinopelvic parameters changes.

Obesity (BMI ≥ 30) was not associated with increased paraspinal muscle atrophy and abnormal spinopelvic parameters changes. In contrast, it was associated with an increased risk of a higher degree of spinal stenosis (grade II or more, OR, 2.22, 95% CI 1.00–5.08, $P = 0.050$).

After adjusting for age, sex, and BMI, we found that fat replacement of paraspinal muscles was associated with an increased risk of developing BP (OR, 8.8; 95% CI, 1.9–39.7.9; $P = 0.006$) and high disability (OR, 3.41; 95% CI, 1.12–10.30; $P = 0.030$), as well as a decrease of PM CSA (OR, 4.13; 95% CI, 1.52–11.2; $P = 0.005$).

Decreased CSA of MF, ES, and PM muscles were associated with a high risk of reducing disc height ($P < 0.001$). The degree of FI or decrease in paraspinal muscles CSA was not associated with spinopelvic parameter changes.

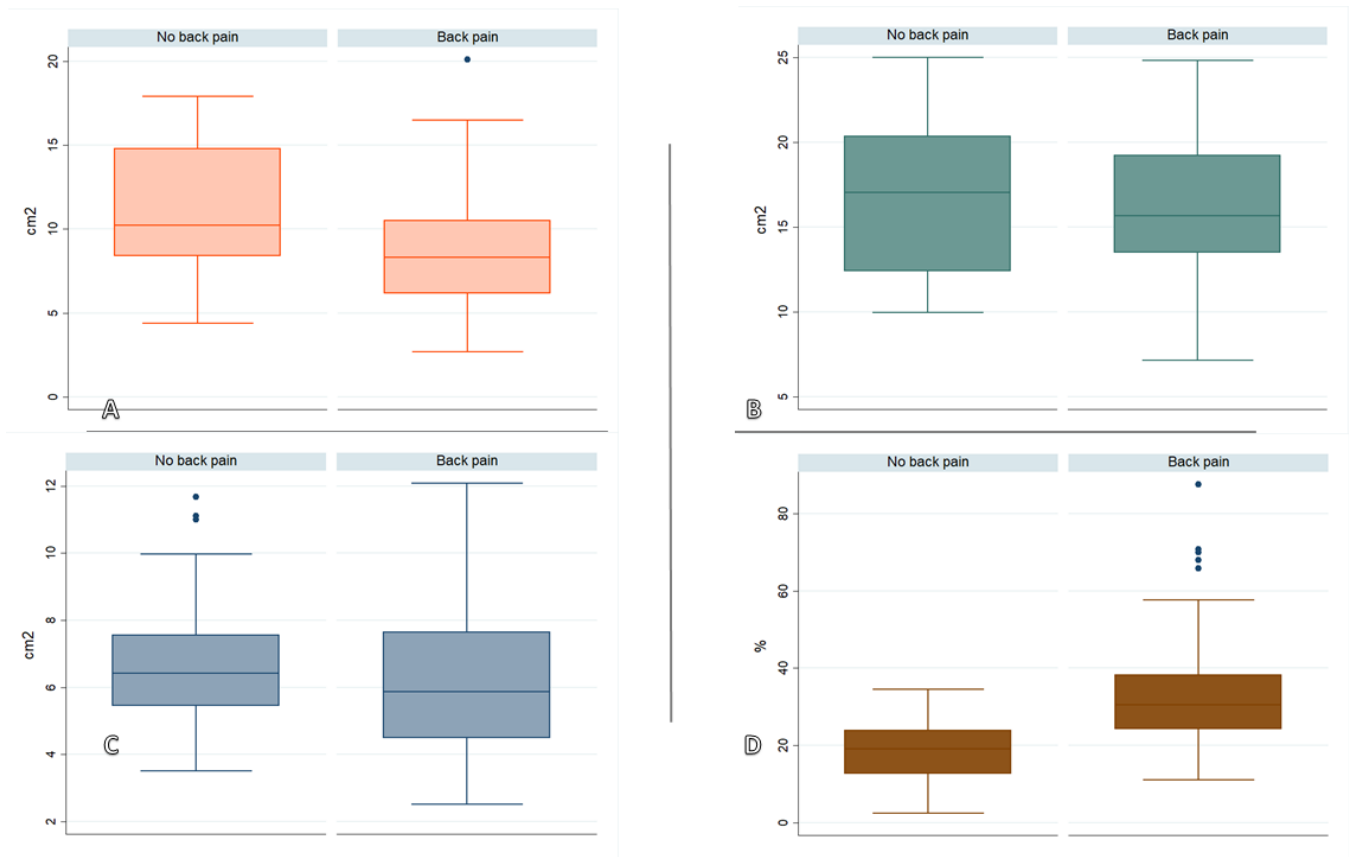


Figure 3. (A) Median and interquartile range (IQR) values of the psoas major cross-sectional area (CSA; cm²) between back pain and no back pain patients. (B) Median and IQR values of multifidus CSA (cm²) between back pain and no back pain patients. (C) Median and IQR values of erector spinae CSA (cm²) between back pain and no back pain patients. (D) Median and IQR values of percentages of paraspinal muscle fatty infiltration between back pain and no back pain patients.

Multivariate analysis results are summarized in Table 3.

DISCUSSION

This study analyzed the role of paraspinal FI, along with MF, ES, and PM CSA, in correlation with structural and spinopelvic parameter changes. We performed

the most extensive volumetric (3-dimensional) analysis of the paravertebral muscles, extending from T12 to S1, including the entire changes in the lumbar segment. This was done because, in similar studies without such extensive analysis, some authors demonstrated discrepancies in results. For example, FI was found to increase in patients suffering from chronic LBP, while others

Table 2. Summary of CSA, volumetric analysis, and spinopelvic parameters values.

Outcome Measure	Back Pain	No Back Pain	P
CSA			
Erector spinae, cm ² , mean ± SD	15.7 ± 3.8	17.1 ± 4.7	0.032
Multifidus, cm ² , mean ± SD	5.9 ± 2.0	6.9 ± 2.2	0.004
Psoas major, cm ² , mean ± SD	8.6 ± 3.2	10.8 ± 3.4	0.004
Paraspinal Muscle Volumetry			
Muscle clean volume, %, mean ± SD	67.7 ± 12.4	80.9 ± 8.5	<0.0001
Fatty infiltration, %, mean ± SD	32.4 ± 12.4	19.0 ± 8.3	<0.0001
Spinopelvic Parameters			
Pelvic incidence, mean ± SD	54.4° ± 13.5°	49.9° ± 14.8°	0.044
Pelvic tilt, mean ± SD	19.7° ± 9.3°	13.7° ± 8.9°	0.0001
Lumbar lordosis (L1–S1), mean ± SD	45.6° ± 20.2°	51.2° ± 13.6°	0.064
Lumbar lordosis, ^a %	81.2	55.6	0.171
Pelvic mismatch, ^b %	53.6	9.6	0.704

Abbreviation: CSA, cross-sectional area.

^aPercentage of patients with L1 to S1 lumbar lordosis values outside confidence interval values for age and sex.

^bPercentage of patients with pelvic mismatch values outside confidence interval values for age and sex.

Table 3. Summary of multivariate analysis models for FI and muscles cross-sectional area interactions with degenerative and structural parameters.

Independent Variables	OR	Multivariate Analysis (95% CI)	P	Adjusting Factors (Dependent Variables)
FI ^a				
Back pain	8.75	1.85–39.65	0.006	Sex, age, and BMI
ODI	3.41	1.12–10.31	0.030	Sex, age, and BMI
P muscle				
Back pain	3.61	1.30–10–2	0.015	Sex, age, and BMI
ODI	4.13	1.52–11.2	0.005	Sex, age, and BMI
Disc height, mm ^b	8.06	3.07–21.2	0.000	Sex, age, and BMI
ES muscle				
Disc height, mm ^b	5.32	2.10–13.43	0.000	Sex, age, and BMI
MF muscle				
Disc height, mm ^b	4.71	1.98–11.46	0.001	Sex, age, and BMI

Abbreviations: BMI, body mass index; ES, erector spinae; FI, fatty infiltration; MF, multifidus; ODI, Oswestry Disability Index; P, psoas.

^aFI > 30% of total paravertebral muscles volume.

^bAverage disc height from T12 to S1.

found that FI does not differ significantly between patients with or without LBP.^{19,20} This discrepancy in the results might be due to methodological differences in FI quantification (ie, whole paraspinal segment vs isolated muscle) or measuring techniques (qualitative vs quantitative or CT vs MRI).

Therefore, unlike past studies, in which the paravertebral muscle complex was analyzed only through axial images capturing a single layer of the muscle as reference images, a 3-dimensional volumetric interpolation to analyze both muscle quantity (CSA) and quality (composition, FI)¹⁹ for the whole lumbar segment was done.²¹ To the best of our knowledge, this has not been done before in such an extensive manner, and 3T MRI was employed for its superior ability to discriminate soft tissue changes, which have been validated against the histology of intraoperative specimens for FI measurements.²² Examining paravertebral muscle composition and changes could better clarify the correlation between degenerative spinal diseases and lower BP, helping develop targeted intervention plans.^{21,23}

Our results revealed that increasing age is independently associated with muscle CSA diminution but not with increased FI or the risk of developing structural or spinopelvic abnormalities. A higher degree of FI on the paraspinal muscles has been correlated with higher instances of BP and disability, but it was not correlated with an increased risk of degenerative spinal changes.²⁴ In contrast, a decrease in the CSA of the paraspinal muscles was consistently associated with disc narrowing. We believe that the loss of CSA is a sign of atrophy and may favor an imbalance in the forces applied to the discs, thus possibly leading to disc degeneration. In this study, obesity was associated with an increased risk of developing lumbar canal stenosis but was not associated with an increased risk of other spinal degenerative changes. Although such results need to be evaluated

with caution because of the relatively limited sample size, they have not been affected by differences in the measured level, as in the previous studies,^{5,25} where the qualitative or quantitative analysis of the muscle was restricted to only a single lumbar level.²⁴

FI seems to increase linearly with age for both sexes, with lumbar paravertebral values higher in women²³ and generally increasing from cranial to caudal,^{26,27} with L4 and L5 being the most affected segments regardless of age.⁵ Increased values of FI and higher odds of developing BP were observed in women despite their age and level of obesity, which might be due to well-documented differences in body composition between men and women.¹⁹ Regarding the decline in paraspinal muscles compared with the degeneration of the spinal column, FI appears to be higher across all age levels in individuals with lumbar spine pathology compared with healthy controls.^{21,23,24}

Declines in MF, ES, and psoas muscle quality were found to occur at similar rates to degenerative changes such as disk protrusion, annular fissure, and spondylolisthesis. When comparing FI levels in the lumbar MF for individuals with and without LBP, some authors reported mean FI percentage values ranging from 4.3% to 73.4% in individuals with chronic LBP symptoms.²³

While data for age-related, degenerative changes to lumbar bones and joints in asymptomatic people have been published, few studies have assessed age-related alterations in paravertebral muscle morphology. Some authors reported 28.8% MF FI at age 40, 28.7% at 45, and 31.6% at age 49 years, indicating a nonlinear increase in fat content. Other studies found a yearly rate of decline in muscle mass, calculated between the ages of 40 and 49 years, which ranged from 0.11% to 0.31%.^{21,23} Despite the partially unclear role of aging in FI and CSA diminution, several authors reported, in line with this study, no association between CSA

or overall MV and age.^{23,28} In one study that investigated lumbar spine MV and FI across a group comprising young and old healthy individuals of similar body weight, age explained 18%–36% of the variance in MF and ES, with age accounting for approximately 30% of the FI percentage in individuals with lumbar spine pathology.^{23,28}

Several authors have confirmed that the increased FI, rather than the decreased muscle CSA, is associated with lower BP, disability, and structural abnormalities in the lumbar spine.^{3,27} They also found higher fat deposits in LBP patients than in healthy controls.^{2,29} Additionally, MF or ES fat replacement was associated with an increased risk of Modic changes or reduced intervertebral disc height.³ Muscle density, assessed by CT, was also associated with lumbar spine facet joint osteoarthritis, spondylolisthesis, and disc narrowing,^{6,30} while some authors found a reduced paraspinal CSA among patients with stenosis than in asymptomatic individuals.^{5,20} Although MF and ES muscles seem to play a crucial role in maintaining pelvic alignment, they were not found to be associated with thoracic kyphosis and sagittal imbalance in patients with degenerative spinal diseases.²⁵ Other studies have speculated on how the capacity of paraspinal muscles, with increased FI, could be reduced to both abilities to extend and stabilize the spine, which may result in decreased LL.²⁷ Indeed, the degree of FI of the back muscle compartment was inversely proportional to that of the intact muscle fiber region, and it may correlate with the level of functional impairment, leading to, or at least aggravating, lumbar back deformity.^{1,18,27}

Muscular disuse and spinal injury were the leading causes of FI.^{3,12} Early FI is seen in the acute period after muscle inactivity, leading to type I slow muscle fibers transforming to type II rapid muscle fibers, along with an increase in FI. In the chronic period, muscle atrophy increases, and FI becomes even more evident and is accompanied by fibrosis formation. Some studies conducted intraoperative biopsies in patients who underwent surgical intervention for intervertebral disc herniation or chronic degenerative lumbar diseases. These studies proved that fat infiltration, muscle degeneration, decreased vascularity, and a rise in inflammatory cytokine expression occurs in the MF and epidural adipose tissue during the muscle inactivity period.^{6,24,31}

However, past studies that analyzed physical activity scores in healthy and LBP patients have not supported this theory entirely, as they have found no differences in the muscle composition or quality between the 2 groups.⁵ Regarding actual physical

intervention that could be done to improve muscle composition, Welch et al found that there was a significant reduction in fat infiltration at the L3 to L4 and L4 to L5 levels after a free-weight-based resistance training,³² while Shahtahmassebi et al, in a systematic review, reported an increase in lower trunk muscle size following participation in an exercise program.³³ Among positive trials, studies involving motor control exercises combined with nonmachine-based resistance exercises and machine-based resistance exercises demonstrated medium to large effects on trunk muscle size.^{2,33}

A denervation theory was also proposed, which raised speculation that FI might negatively affect muscle contractility due to the substitution of muscle fibers by noncontractile tissue, such as fat tissue.¹⁹ However, FI increased bilaterally and evenly between denervated and innervated muscles.¹⁹ Ultimately, the large amount of data collected proves the association between FI and LBP. However, we still cannot infer whether the high-fat content in paraspinal muscles was a cause or result of adverse structural changes.⁷

Strengths and Limitations

Considering that the role of paraspinal muscle composition on structural and spinopelvic parameter changes is still unclear, the present study's limitation is the relatively small number of patients that virtually do not account for all possible confounders/modifiers involved in such a complex and multifactorial disease as LBP. Notably, it is well known that there is increased FI and decreased muscle mass with age and gender. Indeed, a more appropriate analysis would be to try to match the age and gender between the 2 groups and reduce the overall number of subjects in the LBP group.

Also, MRI in the supine position may fail to properly evaluate paraspinal muscle signal and composition due to the lower back muscles compression. Nevertheless, upright MRI devices (standing position MRI) are available in a few centers, and even those instruments do not reach a full standing position, making this an unavoidable bias. Technological advancements may make studying paraspinal muscle composition in better experimental conditions or while moving possible. Another possible limitation is the lack of an accurate collection of physical activity or sarcopenia degree with a validated questionnaire/test (ie, nutrition status, handgrip strength tests, body composition examinations, etc) to elucidate if an underlying pathological condition may

have altered the results, thus possibly introducing a selection bias. There is a need for more age- and sex-matched and randomized studies to elucidate the relationship between LBP and FI.

However, the strength of this study resides in the a priori design, the strict selection criteria, and the pervasive MRI analysis of the whole lumbar segment, making it the first to analyze a whole set of degenerative and spinopelvic parameters from T12 to S1. The study further adjusted the multivariate analysis for age, sex, and BMI to clarify the independent role of FI and muscle CSA on clinical and radiological parameters, making the results more robust. The study performed a size analysis confirming that the sample used was big enough to identify significant changes in the studied parameters. Unfortunately, researchers were not able to be consistent with spinopelvic parameter collections such as sagittal vertical axis or thoracic parameters because of lacking whole columns standing x-ray images. Thus, while the whole hip and lumbar areas were considered, the study included values that allowed researchers to perform a solid logistic regression analysis.

CONCLUSIONS

This study reinforces that FI is associated with increased pain and disability without favoring structural changes and imbalance. It shows that age is independently associated with muscle CSA decrease but not directly with increased fat infiltration or structural or spinopelvic abnormalities. A decrease in the CSA was consistently associated with disc narrowing. By confirming the association between pain generation and paraspinal muscle FI, the study indirectly highlights the role of paraspinal muscle involution and fat substitution on lower BP. The conclusion of our adjusted analysis by age, BMI, and sex is that physical interventions may possible be beneficial in terms of FI reduction and involution. Such interventions may help to maintain or restore muscle quality and possibly decrease BP.

REFERENCES

1. Katzman WB, Miller-Martinez D, Marshall LM, Lane NE, Kado DM. Kyphosis and paraspinal muscle composition in older men: a cross-sectional study for the osteoporotic fractures in men (MrOS) research group. *BMC Musculoskelet Disord*. 2014;15(1):19. doi:10.1186/1471-2474-15-19
2. Kamaz M, Kireşi D, Oğuz H, Emlik D, Levendoğlu F. CT measurement of trunk muscle areas in patients with chronic low back pain. *Diagn Interv Radiol*. 2007;13(3):144–148.
3. Wan Q, Lin C, Li X, Zeng W, Ma C. MRI assessment of paraspinal muscles in patients with acute and chronic unilateral low back pain. *Br J Radiol*. 2015;88(1053):20140546. doi:10.1259/bjr.20140546
4. Kamaz M, Kireşi D, Oğuz H, Emlik D, Levendoğlu F. CT measurement of trunk muscle areas in patients with chronic low back pain. *Diagn Interv Radiol*. 2007;13(3):144–148.
5. Mandelli F, Nüesch C, Zhang Y, et al. Assessing fatty infiltration of paraspinal muscles in patients with lumbar spinal stenosis: goutallier classification and quantitative MRI measurements. *Front Neurol*. 2021;12:656487. doi:10.3389/fneur.2021.656487
6. Kalichman L, Hodges P, Li L, Guermazi A, Hunter DJ. Changes in paraspinal muscles and their association with low back pain and spinal degeneration: CT study. *Eur Spine J*. 2010;19(7):1136–1144. doi:10.1007/s00586-009-1257-5
7. Teichtahl AJ, Urquhart DM, Wang Y, et al. Fat infiltration of paraspinal muscles is associated with low back pain, disability, and structural abnormalities in community-based adults. *Spine J*. 2015;15(7):1593–1601. doi:10.1016/j.spinee.2015.03.039
8. Lee GY, Lee JW, Choi HS, Oh K-J, Kang HS. A new grading system of lumbar central canal stenosis on MRI: an easy and reliable method. *Skeletal Radiol*. 2011;40(8):1033–1039. doi:10.1007/s00256-011-1102-x
9. Niggemann P, Kuchta J, Grosskurth D, Beyer HK, Hoeffler J, Delank KS. Spondylolysis and isthmic spondylolisthesis: impact of vertebral hypoplasia on the use of the meyerding classification. *Br J Radiol*. 2012;85(1012):358–362. doi:10.1259/bjr/60355971
10. Pfirrmann CW, Metzendorf A, Zanetti M, Hodler J, Boos N. Magnetic resonance classification of lumbar intervertebral disc degeneration. *Spine (Phila Pa 1976)*. 2001;26(17):1873–1878. doi:10.1097/00007632-200109010-00011
11. Modic MT, Steinberg PM, Ross JS, Masaryk TJ, Carter JR. Degenerative disk disease: assessment of changes in vertebral body marrow with MR imaging. *Radiology*. 1988;166(1 Pt 1):193–199. doi:10.1148/radiology.166.1.3336678
12. Volpi E, Nazemi R, Fujita S. Muscle tissue changes with aging. *Curr Opin Clin Nutr Metab Care*. 2004;7(4):405–410. doi:10.1097/01.mco.0000134362.76653.b2
13. Childs JD, Piva SR, Fritz JM. Responsiveness of the numeric pain rating scale in patients with low back pain. *Spine (Phila Pa 1976)*. 2005;30(11):1331–1334. doi:10.1097/01.brs.0000164099.92112.29
14. Monticone M, Baiardi P, Ferrari S, et al. Development of the Italian version of the Oswestry Disability Index (ODI-D): a cross-cultural adaptation, reliability, and validity study. *Spine (Phila Pa 1976)*. 2009;34(19):2090–2095. doi:10.1097/BRS.0b013e3181aa1e6b
15. Fedorov A, Beichel R, Kalpathy-Cramer J, et al. 3D slicer as an image computing platform for the quantitative imaging network. *Magn Reson Imaging*. 2012;30(9):1323–1341. doi:10.1016/j.mri.2012.05.001
16. Goutallier D, Postel JM, Bernageau J, Lavau L, Voisin MC. Fatty muscle degeneration in cuff ruptures. Pre- and postoperative evaluation by CT scan. *Clin Orthop Relat Res*. 1994;(304):78–83.
17. Slattery C, Verma K. Classification in brief: SRS-Schwab classification of adult spinal deformity. *Clin Orthop Relat Res*. 2018;476(9):1890–1894. doi:10.1007/s11999-0000000000000264

18. Kim WJ, Kim KJ, Song DG, et al. Sarcopenia and back muscle degeneration as risk factors for back pain: a comparative study. *Asian Spine J.* 2020;14(4):583–585. doi:10.31616/asj.2020.0329r2
19. D'hooge R, Cagnie B, Crombez G, Vanderstraeten G, Dolphens M, Danneels L. Increased intramuscular fatty infiltration without differences in lumbar muscle cross-sectional area during remission of unilateral recurrent low back pain. *Man Ther.* 2012;17(6):584–588. doi:10.1016/j.math.2012.06.007
20. Danneels LA, Vanderstraeten GG, Cambier DC, Witvrouw EE, De Cuyper HJ. CT imaging of trunk muscles in chronic low back pain patients and healthy control subjects. *Eur Spine J.* 2000;9(4):266–272. doi:10.1007/s005860000190
21. Crawford RJ, Cornwall J, Abbott R, Elliott JM. Manually defining regions of interest when quantifying paravertebral muscles fatty infiltration from axial magnetic resonance imaging: a proposed method for the lumbar spine with anatomical cross-reference. *BMC Musculoskelet Disord.* 2017;18(1):25. doi:10.1186/s12891-016-1378-z
22. Rossi A, Zoico E, Goodpaster BH, et al. Quantification of intermuscular adipose tissue in the erector spinae muscle by MRI: agreement with histological evaluation. *Obesity (Silver Spring).* 2010;18(12):2379–2384. doi:10.1038/oby.2010.48
23. Crawford RJ, Volken T, Valentin S, Melloh M, Elliott JM. Rate of lumbar paravertebral muscle fat infiltration versus spinal degeneration in asymptomatic scolioses: an age-aggregated cross-sectional simulation study. *Scoliosis Spinal Disord.* 2016;11:21. doi:10.1186/s13013-016-0080-0
24. Shahidi B, Hubbard JC, Gibbons MC, et al. Lumbar multifidus muscle degenerates in individuals with chronic degenerative lumbar spine pathology. *J Orthop Res.* 2017;35(12):2700–2706. doi:10.1002/jor.23597
25. Katsu M, Ohba T, Ebata S, Oba H, Koyama K, Haro H. Potential role of paraspinal musculature in the maintenance of spinopelvic alignment in patients with adult spinal deformities. *Clin Spine Surg.* 2020;33(2):E76–E80. doi:10.1097/BSD.0000000000000862
26. Kjaer P, Bendix T, Sorensen JS, Korsholm L, Leboeuf-Yde C. Are MRI-defined fat infiltrations in the multifidus muscles associated with low back pain? *BMC Med.* 2007;5:2. doi:10.1186/1741-7015-5-2
27. Lee JC, Cha J-G, Kim Y, Kim Y-I, Shin B-J. Quantitative analysis of back muscle degeneration in the patients with the degenerative lumbar flat back using a digital image analysis: comparison with the normal controls. *Spine (Phila Pa 1976).* 2008;33(3):318–325. doi:10.1097/BRS.0b013e318162458f
28. Shahidi B, Parra CL, Berry DB, et al. Contribution of lumbar spine pathology and age to paraspinal muscle size and fatty infiltration. *Spine (Phila Pa 1976).* 2017;42(8):616–623. doi:10.1097/BRS.0000000000001848
29. Parkkola R, Rytökoski U, Kormanen M. Magnetic resonance imaging of the discs and trunk muscles in patients with chronic low back pain and healthy control subjects. *Spine (Phila Pa 1976).* 1993;18(7):830–836. doi:10.1097/00007632-199306000-00004
30. Yanik B, Keyik B, Conkbayir I. Fatty degeneration of multifidus muscle in patients with chronic low back pain and in asymptomatic volunteers: quantification with chemical shift magnetic resonance imaging. *Skeletal Radiol.* 2013;42(6):771–778. doi:10.1007/s00256-012-1545-8
31. James G, Chen X, Diwan A, Hodges PW. Fat infiltration in the multifidus muscle is related to inflammatory cytokine expression in the muscle and epidural adipose tissue in individuals undergoing surgery for intervertebral disc herniation. *Eur Spine J.* 2021;30(4):837–845. doi:10.1007/s00586-020-06514-4
32. Joiner EF, Youngerman BE, Hudson TS, et al. Effectiveness of perioperative antiepileptic drug prophylaxis for early and late seizures following oncologic neurosurgery: a meta-analysis. *J Neurosurg.* 2018;130(4):1274–1282. doi:10.3171/2017.10.JNS172236
33. Berry DB, Padwal J, Johnson S, Englund EK, Ward SR, Shahidi B. The effect of high-intensity resistance exercise on lumbar musculature in patients with low back pain: a preliminary study. *BMC Musculoskelet Disord.* 2019;20(1):290. doi:10.1186/s12891-019-2658-1

Funding: The authors received no financial support for the research, authorship, and/or publication of this article.

Declaration of Conflicting Interests: The authors report no conflicts of interest in this work.

Corresponding Author: Enrico Giordan, Department of Neurosurgery, Aulss2 Marca Trevigiana, Via Piazzale dell'Ospedale 1, Treviso, Treviso 31100, Italy; enrico.giordan@aulss2.veneto.it

This manuscript is generously published free of charge by ISASS, the International Society for the Advancement of Spine Surgery. Copyright © 2023 ISASS. To see more or order reprints or permissions, see <http://ijssurgery.com>.