

A Network Meta-Analysis Comparing the Efficacy and Safety of Pedicle Screw Placement Techniques Using Intraoperative Conventional, Navigation, Robot-Assisted, and Augmented Reality Guiding Systems

Kanyakorn Riewruja, Teerachat Tanasansomboon, Wicharn Yingsakmongkol, Vit Kotheeranurak, Worawat Limthongkul, Ronpichai Chokesuwattanaskul, Stephen J. Kerr and Weerasak Singhatanadgige

Int J Spine Surg published online 30 July 2024
<https://www.ijssurgery.com/content/early/2024/07/29/8618>

This information is current as of July 30, 2024.

Email Alerts Receive free email-alerts when new articles cite this article. Sign up at:
<http://ijssurgery.com/alerts>

A Network Meta-Analysis Comparing the Efficacy and Safety of Pedicle Screw Placement Techniques Using Intraoperative Conventional, Navigation, Robot-Assisted, and Augmented Reality Guiding Systems

KANYAKORN RIEWRUJA, MD¹; TEERACHAT TANASANSOMBOON, MD²;
WICHARN YINGSAKMONGKOL, MD^{1,2}; VIT KOTHEERANURAK, MD^{1,2}; WORAWAT LIMTHONGKUL, MD^{1,2};
RONPICHAI CHOKESUWATTANASKUL, MD³; STEPHEN J. KERR, PhD⁴; AND WEERASAK SINGHATANADGIGE,
MD^{1,2}

¹Department of Orthopedics, Faculty of Medicine, Chulalongkorn University and King Chulalongkorn Memorial Hospital, Bangkok, Thailand; ²Center of Excellence in Biomechanics and Innovative Spine Surgery, Chulalongkorn University, Bangkok, Thailand; ³Division of Cardiology, Department of Medicine, Faculty of Medicine, Chulalongkorn University and King Chulalongkorn Memorial Hospital, Thai Red Cross Society, Bangkok, Thailand; ⁴Research Affair, Faculty of Medicine, Chulalongkorn University and King Chulalongkorn Memorial Hospital, Thai Red Cross Society, Bangkok, Thailand

ABSTRACT

Background: Studies were reviewed and collected to compare different image guidance systems for pedicle screw placement (PSP) regarding accuracy and safety outcomes. Included were conventional, navigation, robot-assisted, and recent technology such as augmented reality (AR) guiding systems.

Methods: This network meta-analysis obtained human comparative studies and randomized controlled trials (RCTs) regarding PSP found in 3 databases (Cochrane, PubMed, and Scopus). Data extraction for accuracy, safety, and clinical outcomes were collected. The network meta-analysis was analyzed, and a surface under the cumulative ranking curve (SUCRA) was used to rank the treatment for all outcomes.

Results: The final 61 studies, including 13 RCTs and 48 non-RCTs, were included in the meta-analysis. These studies included a total of 17,023 patients and 35,451 pedicle screws. The surface under the cumulative ranking curve ranking demonstrated the supremacy of robotics in almost all accuracy outcomes except for the facet joint violation. Regarding perfect placement, the risk difference for AR was 19.1 (95% CI: 8.1–30.1), which was significantly higher than the conventional method. The robot-assisted and navigation systems had improved outcomes but were not significantly different in accuracy vs the conventional technique. There was no statistically significant difference concerning safety or clinical outcomes.

Conclusions: The accuracy of PSP achieved by robot-assisted technology was the highest, whereas the safety and clinical outcomes of the different methods were comparable. The recent AR technique provided better accuracy compared with navigation and conventional methods.

Level of Evidence: 2

New Technology

Keywords: Augmented reality, spine surgery, spinal navigation, robot-assisted, pedicle screw placement

INTRODUCTION

There have been many advancements in spinal surgery instrumentation and techniques over the past few decades, with posterior fixation being one of the most significant developments.¹ In various indications, pedicle screws are used to stabilize and fuse the spine. Biomechanically, posterior fixation provides 3-dimensional (3D) stability to fused segments and has improved spinal fusion surgery outcomes, which has led to its growing popularity and acceptance.² Several pedicle screw placement (PSP) techniques have been described. The conventional freehand technique is the

technique that was originally used. With this technique, the surgeon identifies the screw entry point based on the patient's spinal anatomical landmarks and inserts the pedicle screws under conventional fluoroscopic guidance.³ However, the rates of screw penetration or misplacement following this technique are not uncommon, potentially leading to serious postoperative complications, such as neurological injuries and hardware failure.^{4,5}

Various assistive intraoperative image guidance technologies have been introduced to help improve the accuracy of the PSP. The intraoperative navigation system was developed and incorporated with different imaging

inputs, such as 2-dimensional (2D) fluoroscopy, 3D fluoroscopy, and computed tomography (CT)-based or O-arm navigation (O-arm, Medtronic, Minneapolis, MN, USA). This system has recently gained popularity among spine surgeons.^{6,7} Several studies demonstrated better accuracy rates of screw placement and fewer screw-related complications compared with the conventional technique, regardless of imaging resources.^{8,9} The robot-assisted system is one of the latest advanced assistive technologies, which provides excellent screw accuracy comparable to navigation.¹⁰ Recently, augmented reality (AR), which is an emerging technology, has provided users with stereoscopic visualizations and integrated computer-generated information into the real-time environment.¹¹ Evidence of the efficacy of AR-assisted PSP has been demonstrated in cadaveric proof-of-concept studies,¹²⁻¹⁶ among diverse operators,^{17,18} and in clinical studies that report high potential efficacy,^{19,20} high efficiency,^{18,21} and a low-radiation system.^{22,23} However, few publications provide quantitative evidence of its value compared with other PSP methods.

In this study, we pooled the data from the studies that utilized several image guidance technologies for the PSP, including recent clinical studies using the AR-assisted method, to investigate and compare the effectiveness regarding screw accuracy, safety, and clinical outcomes among these intraoperative image guidance systems.

MATERIALS AND METHODS

Literature Review and Search Strategy

The protocol for this network meta-analysis (NMA) was registered with PROSPERO (International Prospective Register of Systematic Reviews; no. CRD 42023398773). A systematic literature search of PubMed (1991 to November 2022), SCOPUS (1988 to November 2022), and the Cochrane Database of Systematic Reviews (2000 to November 2022) was conducted to compare different assistive techniques for PSP. The primary outcome was the accuracy of the PSP considering perfect placement, clinically acceptable (safe) placement, screw malposition, intraoperative screw revision, and facet joint violation. The secondary outcomes include safety outcomes consisting of the overall complications, neurological complications, wound and infection complications, and clinical outcomes at 1 year after the index surgery.

The systematic literature review was undertaken independently by 2 investigators (K.R. and T.T.)

applying a search approach that incorporated the terms “pedicle screw” AND “freehand,” “fluoroscope,” “CT,” “C-arm,” “O-arm,” “navigation,” “robot,” “AR,” “virtual reality,” or “mixed reality” in combination found in the Title, Abstract, or Keyword. Only literature published in the English language was included. This study was conducted in accordance with the Preferred Reporting Items for Systematic Reviews and Meta-Analysis statement.²⁴

Definition and Classification

Since there has been a continuous development of assistive technology for better PSP, we classified it into 4 major groups, including conventional, navigation, robot-assisted, and AR-assisted techniques. The conventional method included studies recorded as either freehand or C-arm fluoroscopy, as all the included freehand studies also used C-arm fluoroscopy for final checking of the screw placement. The navigation method included studies using any image sources that could be either 2D, 3D, or CT/O-arm-based systems where we specified the details of image guidance in Table 1. The robot-assisted method is the technique that uses a robot to perform PSP instead of a surgeon. The AR-assisted method uses mixed reality combined with more advanced real-time 3D technology imaging to guide the surgeon while performing PSP.

The primary objective of this study was to evaluate the accuracy of PSP, which consists of 5 aspects, including the perfect placement, a clinically acceptable placement, screw malposition, intraoperative screw revision, and proximal facet joint violation. Postoperative CT images were used to classify the accuracy of screw position in the pedicle. The perfect PSP was graded as Grade A (0 mm breach) of the Gertzbein and Robbins' classification⁵ or Rampersaud's classification,²⁷ while the accuracy of clinically acceptable (safe) placement was defined as less than 3 mm of pedicle screw breach (Grades A and B of the Gertzbein and Robbins' classification, Rampersaud's classification, and Group I-II of the Learch's classification).²⁸ Screw malposition was defined as screw penetration beyond the safe placement borderline. Proximal facet joint violation was also recorded as grade 1 or more of the classifications described by Kim et al²⁹ and Babu et al.³⁰

The secondary outcomes include safety and functional outcome aspects. Postoperative complications imply the safety of the procedure, including any adverse events, neurological complications, wound and infection complications, and reoperation or revision incidences. The postoperative clinical changes reported in extracted studies consist of the visual analog scale of the back (VAS back), the VAS

Table 1. Study characteristics providing information on the study design, comparative intervention, instrument details, study duration, population, number of patients, gender percentages, and body mass index of included patients.

Study	Study Design	Group Comparison	Study Group	Details of the Image Guidance System	Control Group	Details of the Image Guidance System	No. of Patients		Age, y		Gender (% men)		BMI, kg/m ²		
							Total	T	C	T	C	T	C	T	C
Allam et al., 2013 ²⁵	Cohort study	NC	Navigated	3D navigation	Conventional	January 2009–March 2010	Internal fixation for fractures, tumors, and spondylodiscitis of the thoracic spine and degenerative lumbar lordosis	45	27	18					
Aqurashi et al., 2021 ²⁶	Prospective cohort study	NC	Navigated	CT-guided navigation	Conventional	March 2016–April 2017	Instrumented lumbar fusion using transpedicular screws	57	15	42	59.3 ^a (27–76)	26.7	42.9	29.5 ^a (23.2–27.3)	30.1 ^a (22–34.2)
Baky et al., 2019 ²⁹	Retrospective cohort study	NC	Navigated	CT-guided navigation	Conventional	2009–2015	Younger than 19 y underwent pedicle screw instrumentation	217	105	112	13.9	32.38	25		
Bovonratwet et al., 2018 ⁴⁰	Retrospective cohort study	NC	Navigated	Any navigation	Conventional	2010–2015	Posterior lumbar fusion, excludes multiple-level cases, uninstrumented cases, cases involving trauma, fracture, neoplasms, infection, or patient age <18 y	5805	1161	4644	58.8	40.57	40.91	30.8	30.7
Budu et al., 2020 ⁴¹	Retrospective cohort study	NC	Navigated	3D Iso-C scan	Conventional	2013–2018	Cases involving a pedicle or lateral mass screw insertion	176	total = 176						
Crawford et al., 2022 ⁴²	Retrospective cohort study	NC	Navigated	O-arm	Conventional	June 2012–May 2016		155	84	71	53.37 (15.5)	54.7	42.2		
De Biase et al., 2021 ⁴³	Retrospective cohort study	RC	Robotic	Mazor X Robot	Conventional	July 2017–March 2020	MIS TLIF	101	52	49	56 (11.7)	42.8	53	28.8 (4.8)	30.3 (4.6)
Du et al., 2020 ⁴⁴	Retrospective cohort study	RN	Robotic	Tinavi Robot	Navigated	2017–2019	Thoracolumbar internal fixation with pedicle screws	302	136	166	58.6 (9.9)	54.4	51.8	22.5 (4.3)	23.2 (3.9)
Edström et al., 2020 ⁴⁵	Prospective study with retrospective control	AC	AR	ARSN	Conventional		Deformity surgery for scoliosis and kyphosis	44	15	29	28.3 (19)	46.6	31.37		
Elmi-Terander et al., 2020 ⁴⁶	Prospective study with retrospective control	AC	AR	ARSN	Conventional			40	20	20	30 (19.4)	45	45	19.8 (2.1)	23.2 (5.5)
Fan et al., 2017	Retrospective cohort study	RNC	Robotic	SpineAssist	Navigated and conventional	2017	Degenerative pathology	67	39	28	60.6 (7.9)	49	39	22.9 (4.7)	24.8 (3.5)
Fayed et al., 2020 ⁴⁸	Prospective comparative study	RC	Robotic	ExcelsusGPS system	Conventional	December 2019–February 2020	Degenerative spine conditions	48	20	28	62.8 ^a (44–75)	30.4	35.7	31.2 (5.8)	NA
Fraser et al., 2010 ⁴⁹	Cohort study	NC	Navigated	3D Iso-C-arm	Conventional	December 2005–July 2007	Degenerative lumbar instability	42	29	13	55.1 (13.6)	41.4	46.2		
Fu et al., 2008 ⁵⁰	Retrospective cohort study	NC	Navigated	CT	Conventional		Pedicle screw insertion below the level of T8	24	11	13					
Gao et al., 2021 ⁵¹	Retrospective cohort study	RC	Robotic	Mazor Renaissance Surgical guidance robot	Conventional	December 2017–February 2020	2-Level percutaneous endoscopic LIF or MIS-TLIF	41	18	23	61.6 (7.1)	44.4	47.8	26 (3.6)	25.5 (2.9)
García-Fantini et al., 2018 ⁵²	Retrospective cohort study	NC	Navigated	3D isocentric fluoroscopic navigation	Conventional	2012–2017	Open L4–L5–S1 fixation with pedicle screw implantation	135	96	39	60.6	28.12	23.07		
Good et al., 2021 ⁵³	Prospective comparative study	RC	Robotic	Mazor Renaissance Surgical guidance robot	Conventional	October 2014–September 2018	Primary short lumbar or lumbosacral percutaneous/MIS spinal fusion	485	374	111	59 (12.6)	43.9	37.8	31.2 (6.8)	28.1 (5.2)

Table 1. Continued.

Study	Study Design	Group Comparison	Study Group	Details of the Image Guidance System	Control Group	Details of the Image Guidance System	Duration	Population	Total	No. of Patients			Age, y			Gender (% men)			BMI, kg/m ²		
										T	C	T	C	T	C	T	C	T	C	T	C
Gu et al., 2020 ⁵⁴	Prospective comparative study	AC	AR	HoloLens 2 mixed reality technology	Conventional	HoloLens 2 mixed reality technology	January 2017–October 2018	Lumbar disc herniation and/or lumbar spondylosisthesis	50	25	25	44.32 (3.78)	45.56 (3.93)	44	52						
Han et al., 2010 ⁵⁵	RCT	NC	Navigated	3D computer navigation	Conventional	3D computer navigation	2006	Thoracic spine pedicle screw insertion	42	22	20										
Han et al., 2019 ⁵⁶	RCT	RC	Robotic	TiRobot	Conventional	TiRobot	January 2016–September 2017	Thoracolumbar posterior fusion due to degenerative or traumatic disorders	234	115	119	54.6 (11.3)	56.1 (13.4)	52.17	51.26	25.7 (4.1)	24.9 (2.9)				
Hyun et al., 2017 ⁵⁷	RCT	RC	Robotic	Mazor Renaissance Surgical	Conventional	Mazor Renaissance Surgical	December 2013–January 2015	Primary lumbar interbody fusion	60	30	30	66.5 (8.1)	66.8 (8.9)	30	26.7	24.7 (2.6)	25.8 (3.3)				
Ishikawa et al., 2010 ⁵⁸	Retrospective cohort study	NC	Navigated	3D fluoroscopy-based computer assisted	Conventional	3D fluoroscopy-based computer assisted	2003–2008	Posterior cervical fixation	62	32	30	59.3 (9.8)	59.9 (18.3)	62.5	53.33						
Jin et al., 2016 ⁵⁹	Retrospective cohort study	NC	Navigated	O-arm	Conventional	O-arm	June 2011–September 2013	Dystrophic neurofibromatosis I associated scoliosis	31	12	19	14.8 ^a _{11–22}	15.3 ^a _{12–24,27–29}	38.46	47.37						
Karamian et al., 2023 ³²	Retrospective cohort study	RC	Robotic	Globus Excelstus GPS and Medtronic Mazor Robotic Renaissance	Conventional	Globus Excelstus GPS and Medtronic Mazor Robotic Renaissance	January 2014–August 2020	1–3-level lumbar fusion	262	85	177	65 (11.9)	64.9 (11.5)	44.7	44.6	29.7 (6.67)	29.5 (6.58)				
Katsevan et al., 2021 ⁶⁰	Retrospective cohort study	RC	Robotic	Mazor X robot	Conventional	Mazor X robot	2017–2019	Posterior percutaneous thoracic and/or lumbar fixation surgery	37	17	20	61.4 (13.8)	57.3 (17.3)	75	52.94	32.3 (6.7)	31.9 (8.1)				
Khanna et al., 2016 ⁶¹	Retrospective cohort study	NC	Navigated	O-arm	Conventional	O-arm	March 2005–May 2015	1-Level lumbar fusion surgery	136	73	63										
Kim et al., 2017 ⁶²	RCT	RC	Robotic	Mazor Renaissance Surgical guidance robot	Conventional	Mazor Renaissance Surgical guidance robot	December 2013–October 2014	Lumbar spinal stenosis	78	37	41	65.4 (10.4)	66 (8.6)	50	54.8	25.9	25.3				
Kim et al., 2018 ⁶³	RCT	RC	Robotic	Mazor Renaissance Surgical guidance robot	Conventional	Mazor Renaissance Surgical guidance robot	December 2013–October 2014	Degenerative spinal disease with lumbar spinal stenosis	78	37	41	65.4 (10.4)	66 (8.6)	51.4	54.8	25.9	25.3				
Laine et al., 2000 ⁶⁴	RCT	NC	Navigated	Meditation	Conventional	Meditation	April 1980–June 1999	Thoracolumbar and lumbosacral fusion	91	41	50										
Lai et al., 2022 ⁶⁵	Retrospective cohort study	RC	Robotic	Mazor Renaissance Surgical guidance robot	Conventional	Mazor Renaissance Surgical guidance robot	May 2018–September 2020	Degenerative lumbar disease underwent TLIF	108	29	79	66 ^a _(60–76.5)	64 ^a _(54.5–71)	48.3	41.8	27.4 ^a _(23.3–30.6)	25.9 ^a _(23.4–29)				
Laudato et al., 2018 ⁶⁶	Retrospective cohort study	RNC	Robotic	Mazor robotics	Navigated and conventional	Mazor robotics	2006–2011	MIS TLIF	142	37	105	50.2 (13.2)	53.9 (14.6)	48.6	35.2	31.9 (6.7)	28.9 (5.8)				
Lau et al., 2013 ⁶⁷	Matched cohort study	NC	Navigated	O-arm	Conventional	O-arm	October 2014–January 2019	Short segment minimally invasive lumbar interbody fusion procedure	485	374	111	59	62.5	43.9	37.8	31.2	28.1				
Lioumakos et al., 2021 ⁶⁸	Retrospective review of a prospective study	RC	Robotic	Orthbot system	Conventional	Orthbot system	August 2018–December 2018	Posterior fusion for degenerative lumbar disease	27	7	20	47.4 (12.9)	49.9 (10.9)	42.85	40	24.3 (1.8)	24.6 (2.6)				
Li et al., 2020 ⁶⁹	RCT	RC	Robotic	Orthbot system	Conventional	Orthbot system	April–October 2013	Posterior fusion for degenerative lumbar spine disease	20	10	10	63.4 (11)	63.4 (11)	66.67	66.67	27.8 (4)	27.3 (5.6)				
Lonjon et al., 2016 ⁷⁰	Prospective matched controlled study	RC	Robotic	ROSA robots	Conventional	ROSA robots	2019–2020	Open posterior lumbar fusion, exclude MIS because of necessity of bone registration	90	45	45	63.8	64	31.11	48.88						
Malham et al., 2022 ⁷¹	RCT	AN	AR	FLASH	Navigated	FLASH															

Table 1. Continued.

Study	Study Design	Group Comparison	Study Group	Details of the Image Guidance System	Control Group	Details of the Image Guidance System	Duration	Population	Total	No. of Patients			Age, y			Gender (% men)			BMI, kg/m ²		
										T	C	T	C	T	C	T	C	T	C	T	C
Mollitaj et al. 2017 ²	Retrospective cohort study	RC	Robotic	Mazor robot	Conventional		2007–2015	Spinal instability due to degeneration, tumor, or trauma	169	98	71	58.3 (12.8)	54.4 (17)	51.02	50.7						
Noshchenko et al. 2018 ⁷³	Retrospective cohort study	NC	Navigated	O-arm	Conventional		2011–2012		81	41	40	59 (9.3)	65 (9.2)	29.3	34.5						
Pendharkar et al. 2019 ⁷⁴	Matched retrospective study	NC	Navigated	Any navigation	Conventional		2007–2016	Laminectomy and instrumented PLIF: single level and 3–5 levels	893	893	16	55.6 (12.2)	55.1 (12.3)	60.8	60.2						
Rajasekaran et al. 2007 ⁷⁵	RCT	NC	Navigated	3D Iso-C scan	Conventional			Spinal deformity correction using posterior pedicle screw of the thoracic spine	33	17	16	19.6 (9.3)	15.4 (4.3)	35.29	25						
Ringel et al. 2012 ⁷⁶	RCT	RC	Robotic	Mazor SpineAssist	Conventional			Lumbosacral stabilization	60	30	30	68 ^a	67 ^a	46.67	40	26 ^a					28 ^a
Ruati et al. 2016 ⁷⁷	RCT	NC	Navigated	3D fluoroscopy	Conventional		March 2011–July 2012		143	71	72										
Schatlo et al. 2014 ⁷⁸	Matched retrospective study	RC	Robotic	Mazor SpineAssist	Conventional		2007–2011	PLIF and TLIF	95	55	40	52 ^a (27–83)	58 ^a (23–82)	47.3	30	24.7 (3.7)	28 (6.1)				
Schizas et al. 2012 ⁷⁹	Prospective study	RC	Robotic	Mazor bone-mounted robotic	Conventional			Vertebral fracture, spinal stenosis, degenerative disc disease, or lumbar scoliosis; exclude thoracic scoliosis	34	11	23										
Shafi et al. 2022 ⁸⁰	Retrospective cohort study	RN	Robotic	ExcelsiusGPS system	Navigated	3D fluoroscopy	April 2017–June 2021	MIS TLIF	222	92	130	59.5 (12.1)	58.5 (12.9)	51.1	53.1	27.5 (4.9)	27.9 (6.4)				
Shi et al. 2021 ⁸¹	Retrospective cohort study	RC	Robotic	Robotic system of Zhuzhens	Conventional		September 2017–June 2019	Thoracolumbar fracture underwent MIS pedicle screw fixation	30	13	17	47 ^a (23–70)	49.1 ^a (25–69)	61.5	52.94	24.16 ^a (19.1–27.0)	25.13 ^a (18.7–31.1)				
Shin et al. 2015 ⁸²	RCT	NC	Navigated	O-arm	Conventional		January 2010–July 2010	Thoracic or lumbar spine pathology	40	20	20	57.5 ^a (30–72)	55.3 ^a (28–75)	60	55						
Silbermann et al. 2011 ⁸³	Comparative study	NC	Navigated	O-arm	Conventional		January–September 2009	PLIF or TLIF	67	37	30	64.41	60.1	56.76	50						
Solomichuk et al. 2017 ⁸⁴	Matched retrospective study	RC	Robotic	Mazor SpineAssist	Conventional		June 2009–June 2015	Metastatic spine disease	70	35	35	63.7 (10.6)	62.2 (11.1)	60	65.7						
Su et al. 2020 ⁸⁵	Prospective controlled study	RC	Robotic	TiRobot	Conventional		December 2018–December 2019	Posterior cervical surgeries for degenerative or trauma conditions	58	28	30	60.40 (4.99)	60.33 (5.23)	53.57	56.67	23.53 (3.22)	23.59 (2.64)				
Boon Tow et al. 2015 ⁸⁶	Prospective study	RC	Robotic	O-arm	Conventional			Single-level lumbar degenerative spondylolisthesis	38	19	19	60 (11.25)	62 (18.07)								
Urbanski et al. 2018 ⁸⁷	Cohort study	NC	Navigated	O-arm	Conventional		2016	Progressive idiopathic scoliosis	49	27	22	20 ^a (11–45)	24 ^a (12–48)	18.51	13.63						
Wang et al. 2021 ⁸⁸	Retrospective cohort study	RC	Robotic	Mazor Renaissance Surgical guidance robot	Conventional		January 2017–January 2020	Open surgery for lumbar spondylolisthesis	62	31	31	57.2 (12.1)	58.6 (10.7)	25.8	32.25	26.1 (3.8)	26.4 (3.5)				
Wang et al. 2019 ⁸⁹	Retrospective cohort study	NC	Navigated	O-arm	Conventional		January 2014–June 2016	3-Level degenerative lumbar disease	41	20	21	72.15 (5.58)	72.57 (6.41)	45	57.14						
Waschke et al. 2013 ⁹⁰	Retrospective cohort study	NC	Navigated	CT navigation	Conventional		1995–2005	Pedicle screw instrumentation	1006	505	501										
Wu et al. 2010 ⁹¹	RCT	NC	Navigated	3D computer navigation	Conventional		2006	Pedicle screw instrumentation	42	22	20										
Yang et al. 2019 ⁹²	Retrospective cohort study	RC	Robotic	Mazor Renaissance Surgical guidance robot	Conventional		January 2017–December 2017	Unstable lumbar spondylolisthesis	60	30	30	54 (7.7)	55.1 (8.1)	46.67	40	23.5 (1.9)	23.2 (1.7)				

Table 1. Continued.

Study	Study Design	Group Comparison	Study Group	Details of the Image Guidance System		Control Group	Details of the Image Guidance System	Duration	Population	No. of Patients		Age, y		Gender (% men)		BMI, kg/m ²	
				Total	T					C	T	C	T	C	T	C	T
Yan et al, 2022 ³³	Retrospective cohort study	RC	Robotic	TiRobot	Conventional	Conventional	December 2020–June 2021	Thoracolumbar pedicle screw placement	89	40	49	58.68 (11.64)	60.78 (7.78)	42.5	35	26.5 (5.14)	25.78 (3.2)
Zhang et al, 2021 ³⁴	Retrospective cohort study	RC	Robotic	Renaissance robot system	Conventional	Conventional	January 2018–December 2019	Lumbar revision surgery	81	39	42	65.96 (7.55)	66.86 (7.32)	53.84	52.38	24.46 (2.26)	23.68 (2.58)
Zhang et al, 2019 ³⁵	Retrospective cohort study	RC	Robotic	TiRobot system	Conventional	Conventional	March 2016–November 2017	TLIF for lumbar degenerative surgery	87	43	44	56.7 (12.5)	60.2 (10.9)	27.9	40.9	26.4 (3.9)	25.2 (2.8)
Zhang et al, 2019 ³⁶	Prospective study	RC	Robotic	TiRobot system	Conventional	Conventional	February 2016–2018	Lumbar degenerative disease undergoing TLIF	100	50	50	54.6 (11.1)	55.6 (12.8)	34	52	25.6 (3.9)	25.3 (3.1)

Abbreviations: AC, augmented reality-assisted vs conventional methods; AN, augmented reality; ARS, augmented reality system navigation; C, control group; CT, computer tomography; 3D, 3-dimensional; LIF, lumbar interbody fusion; MIS, minimally invasive surgery; NC, navigated vs conventional methods; PLF, posterior lumbar fusion; PLIF, posterior lumbar interbody fusion; RC, robotic vs conventional methods; RCT, randomized controlled trial; RNC, robotic vs navigated vs conventional methods; T, treatment group; TLIF, transforaminal lumbar interbody fusion. *Age and BMI were reported with mean (SD) or median (range).

leg, and the Oswestry Disability Index (ODI) up to 1-year after the operation.

Selection Criteria

Data from comparative studies (cohort, case-control, or cross-sectional studies) and randomized controlled trials (RCTs) were included in the analysis, whereas descriptive studies, case series, case reports, cadaveric studies, non-human studies, systematic reviews, literature reviews, or meta-analyses were excluded. Eligible studies are needed to provide data on measurement accuracy, the prevalence of any adverse events, or clinical outcomes. Inclusion was not limited by the study sample size. Retrieved articles were individually reviewed for eligibility by K.R. and T.T. Discrepancies were discussed and resolved by a third investigator (W.S.).

Data Extraction

A structured data collection form was utilized to derive the following information from each study: the year that the study was conducted, name of the first author, publication year, demographic and characteristic data of the population, intraoperative imaging guidance system used, and types of instruments.

Statistical Analyses

We conducted a contrast-based NMA using Stata 17 (Statacorp LLC, College Station, TX, USA).³¹ Binary efficacy and safety outcomes were summarized as pooled risk differences (95% CI) between conventional surgery and AR, navigation, or robot-assisted surgery, and a global test of inconsistency was performed. The surface under the cumulative ranking curve (SUCRA) was used for the hierarchical ranking of the treatments, which could be interpreted as the estimated possibilities of being the best treatment. Clinical outcome data were reported by most studies as pre- and postsurgical means, without reporting the SD of the change from pre- to postsurgery. We used the study that reported outcomes in sufficient detail³² to derive a correlation coefficient, which we used to impute an SD of the change from the baseline for the other studies.³³ The risk of bias across studies was summarized by the Newcastle-Ottawa quality assessment scale for case-control studies³⁴ and the Cochrane Collaboration's tool for randomized trials.³⁵ Funnel plots were drawn to assess the risk of publication bias.

RESULTS

Study Selection

A total of 3987 studies were imported from 3 different electronic databases (PubMed, Scopus, and the Cochrane Library), and 1411 duplicate studies were removed. After screening, 2352 studies were excluded because they were not related to pedicle screw insertion in spine surgery. A total of 224 full-text articles were assessed, of which 163 studies were excluded based on the inclusion and exclusion criteria. Thus, we included the final 61 articles, including 13 RCTs and 48 non-RCTs (11 prospective cohort studies and 37 retrospective observational studies), for conducting the systematic review and NMA. A flow diagram of study selection is presented in Figure 1.

Overall Characteristics and Risk of Bias Assessment of the Included Studies

A total of 17,023 patients and 35,451 pedicle screws were included in the study. The mean study sample size was 67 patients (range 20–5805), with an average of 3 pedicle screws per patient. The baseline characteristics of each study are shown in Table 1. The quality of evidence was appraised according to the quality assessment tools for different study designs as previously stated and reported in Table 2 and Figure 2.

Primary Outcomes

PSP Accuracy

Fifty-six studies used Gertzbein and Robbins' classification to evaluate the accuracy of the PSP. Four studies employed Rampersaud's classification, and the other 3 used Leach's classification. All of these classifications employed postoperative CT to assess the accuracy of the PSP.

Perfect Placement of Pedicle Screws

The NMA of 41 studies gave direct comparisons among 4 different techniques: conventional method, navigation, robot-assisted, and AR technologies, while there were only indirect comparisons between AR and robot-assisted systems (Figure 3a). There was no evidence of inconsistency ($\chi^2 = 6.05$, $P = 0.195$). Compared with the conventional method, AR had significantly higher accuracy with a risk difference of 19.1 (95% CI: 8.1–30.1; Figure 3a). The robot-assisted and navigation systems had better accuracy vs the conventional method, but the difference was not statistically significant (risk difference: 9.3, 95% CI: –9.1 to 27.7; and 2.9,

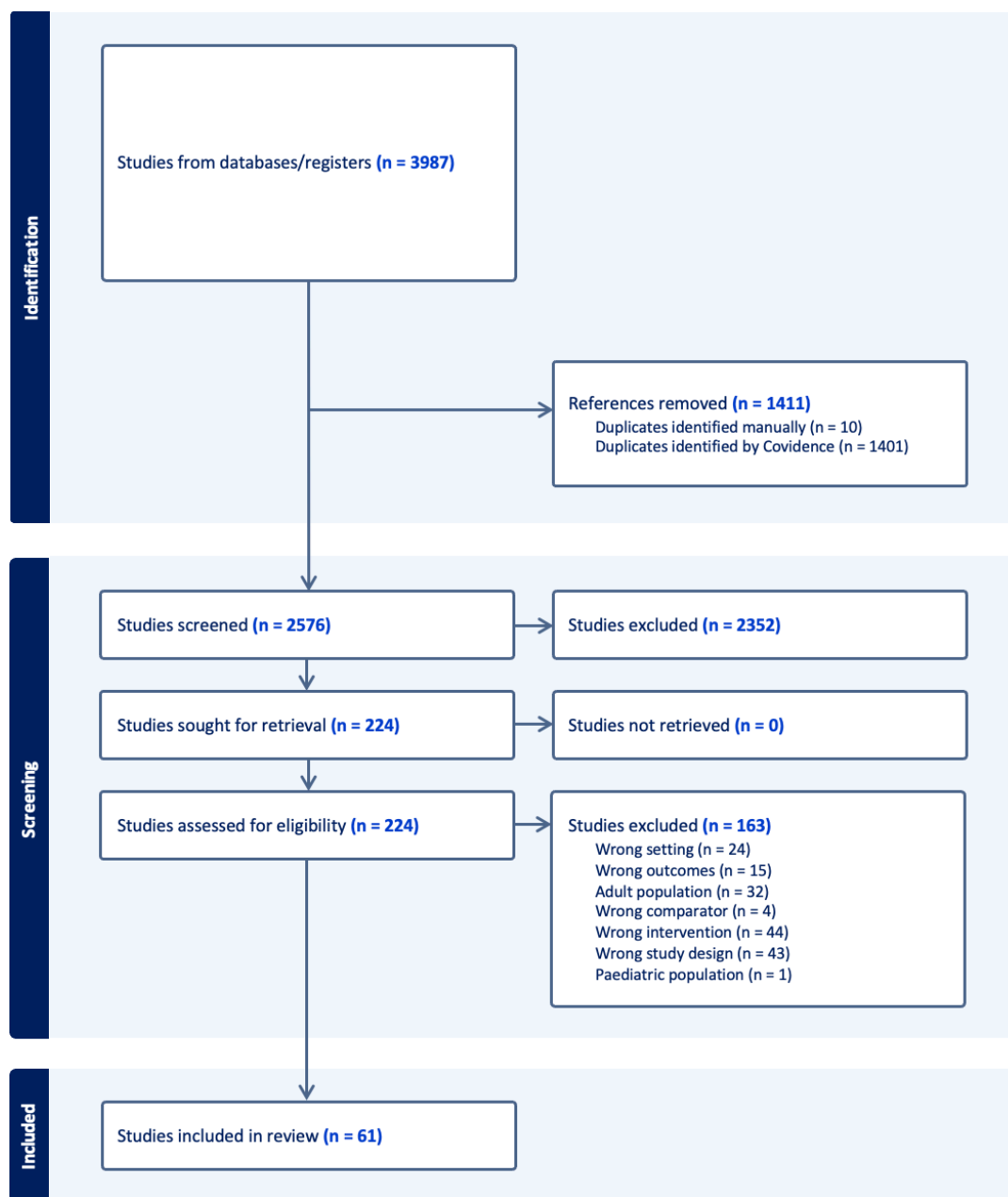


Figure 1. The Preferred Reporting Items for Systematic Reviews and Meta-Analysis flow diagram of the selection process of related articles.

95% CI: -9.1 to 14.8, respectively; Figure 3a). Nonetheless, there was no significant difference between robotic-assisted and AR (risk difference of 0.7, 95% CI: -15.3 to 16.6).

Clinically Acceptable (Safe) Placement and Screw Malposition

Safe screw placement was reported in 36 studies, and NMA provides 53 direct comparisons across 4 different methods. Among those, there was no direct comparison between AR and robot-assisted methods. Inconsistency testing was conducted, and the consistency assumption

could be accepted at the overall level of each treatment ($\chi^2 = 4.66, P = 0.3237$). Compared with the conventional method, there was no statistically significant difference found for robot-assisted, navigation, or AR methods (risk differences of -0.74 [95% CI: -12.42 to 10.94], 3.35 [95% CI: -3.34 to 10.04], and 4.3 [95% CI: -4.37 to 12.99], respectively; Figure 3b). On the contrary, screw malposition data extracted from 40 studies giving 55 direct comparisons across 4 methods demonstrated more significant displacement in the conventional technique when compared with robot-assisted (risk difference: -4.81, 95% CI: -7.05 to -2.58) but not compared

Table 2. Newcastle-Ottawa Scale—for cohort studies.

Study	Items and Scores								Total
	Representativeness of the Exposed Cohort (1)	Selection of the Nonexposed Cohort (1)	Ascertainment of Exposure (1)	Demonstration That Outcome of Interest Was Not Present at Start of Study (1)	Compare Ability of Cohorts on the Basis of the Design or Analysis (2)	Assessment of Outcome (1)	Was Followed Up Long Enough for Outcomes to Occur (1)	Adequacy of Follow-Up of Cohorts (1)	
Allam et al, 2013 ²⁵	★	★	★	★	★	★	★	★	8
Alqurashi et al, 2021 ²⁶	★	★	★	★	★	★	★	★	8
Baky et al, 2019 ²⁷	★	★	★	★	★	★	★	★	8
Bovonratwet et al, 2018 ⁴⁰	★	★	★	★	★	★	★	★	8
Budu et al, 2020 ⁴¹	★	★	★	★	★	★	★	★	8
Crawford et al, 2022 ⁴²	★	★	★	★	★	★	★	★	8
De Biase et al, 2021 ⁴³	★	★	★	★	★	★	★	★	8
Du et al, 2020 ⁴⁴	★	★	★	★	★	★	★	★	8
Edström et al, 2020 ^{25,45}	★	★	★	★	★	★	★	★	8
Elmi-Terander et al, 2020 ⁴⁶	★	★	★	★	★	★	★	★	8
Fan et al, 2017 ⁴⁷	★	★	★	★	★	★	★	★	8
Fayed et al, 2020 ⁴⁸	★	★	★	★	★	★	★	★	8
Fraser et al, 2010 ⁴⁹	★	★	★	★	★	★	★	★	8
Fu et al, 2008 ⁵⁰	★	★	★	★	★	★	★	★	8
Gao et al, 2021 ⁵¹	★	★	★	★	★	★	★	★	8
García-Fanfani et al, 2018 ⁵²	★	★	★	★	★	★	★	★	8
Good et al, ⁵³	★	★	★	★	★	★	★	★	9
Gu et al, ⁵⁴	★	★	★	★	★	★	★	★	8
Ishikawa et al, 2010 ⁵⁸	★	★	★	★	★	★	★	★	8
Jin et al, 2016 ⁵⁹	★	★	★	★	★	★	★	★	8
Karamian et al, 2023 ³²	★	★	★	★	★	★	★	★	8
Katsevman et al, 2021 ⁶⁰	★	★	★	★	★	★	★	★	8
Khanna et al, 2016 ⁶¹	★	★	★	★	★	★	★	★	8
Lai et al, 2022 ⁶⁵	★	★	★	★	★	★	★	★	8
Laudato et al, 2018 ⁶⁶	★	★	★	★	★	★	★	★	8
Lau et al, 2013 ⁶⁷	★	★	★	★	★	★	★	★	8
Liounakos et al, 2021 ⁶⁸	★	★	★	★	★	★	★	★	9
Lonjon et al, 2016 ⁷⁰	★	★	★	★	★	★	★	★	8
Molligaj et al, 2017 ⁷²	★	★	★	★	★	★	★	★	9
Noshchenko et al, 2018 ⁷³	★	★	★	★	★	★	★	★	8
Pendharkar et al, 2019 ⁷⁴	★	★	★	★	★	★	★	★	9
Schatlo et al, 2014 ⁷⁸	★	★	★	★	★	★	★	★	9
Schizas et al, 2012 ⁷⁹	★	★	★	★	★	★	★	★	8
Shafi et al, 2022 ⁸⁰	★	★	★	★	★	★	★	★	9
Shi et al, 2021 ⁸¹	★	★	★	★	★	★	★	★	8
Silbermann et al, 2011 ⁸³	★	★	★	★	★	★	★	★	8
Solomnichuk et al, 2017 ⁸⁴	★	★	★	★	★	★	★	★	8
Su et al, 2022 ⁸⁵	★	★	★	★	★	★	★	★	9
Boon Tow et al, 2015 ⁸⁶	★	★	★	★	★	★	★	★	8
Urbanski et al, 2018 ⁸⁷	★	★	★	★	★	★	★	★	8
Wang et al, 2021 ⁸⁸	★	★	★	★	★	★	★	★	8
Wang et al, 2019 ⁸⁹	★	★	★	★	★	★	★	★	8
Waschke et al, 2013 ⁹⁰	★	★	★	★	★	★	★	★	8
Yang et al, 2019 ⁹²	★	★	★	★	★	★	★	★	8
Yan et al, 2022 ⁹³	★	★	★	★	★	★	★	★	8
Zhang et al, 2021 ⁹⁴	★	★	★	★	★	★	★	★	8
Zhang et al, 2019 ⁹⁵	★	★	★	★	★	★	★	★	8
Zhang et al, 2019 ⁹⁶	★	★	★	★	★	★	★	★	8

Abbreviations: -, The study did not describe items according to the Newcastle-Ottawa quality assessment scale; ★, The study reported items according to the Newcastle-Ottawa quality assessment scale; ★★, The study reported control for the analysis with any additional factor.

Note: The maximum number of stars for each item is indicated within parentheses.

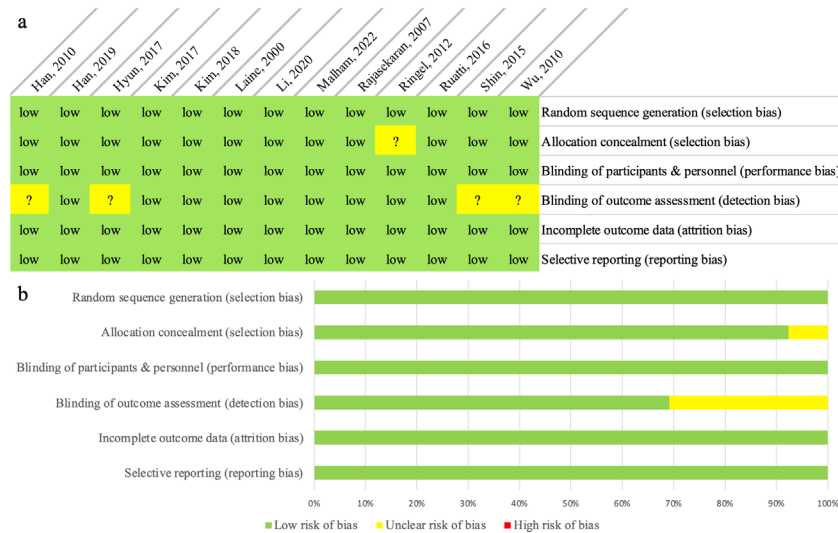

Figure 2. The Cochrane Collaboration’s tool for assessing the risk of bias for randomized controlled trials. (a) Risk-of-bias summary: A review of authors’ judgments on each risk-of-bias item for each study included. (b) Risk-of-bias graph: A review of authors’ judgments on each risk-of-bias item, presented as percentages across all included studies.

with AR (risk difference: -4.3 , 95% CI: -13.17 to 4.56 , $P = 0.330$) and navigation (risk difference: -1.46 , 95% CI: -8.17 to 5.25) methods (Figure 3c). Evidence of inconsistency was not found ($\chi^2 = 3.23$, $P = 0.3570$).

Intraoperative Screw Revision and Proximal Facet Joint Violation

Other aspects indicating the accuracy of different techniques are, first, the intraoperative screw revision, where mispositioned screws or unsatisfactory screw insertion were revised using either a similar or a backup conventional method, and second, the proximal facet joint violation. Despite not being the primary study outcomes in most included studies, 8 studies provided direct comparisons among conventional, navigation, and robotics. None of the AR studies reported these outcomes. Testing for inconsistency was conducted ($\chi^2 = 0.29$, $P = 0.865$). In comparison to the conventional method, the robot-assisted and navigation methods demonstrated fewer incidences of intraoperative screw revision (risk difference: -2.27 , 95% CI: -5.28 to 0.74 , and -0.88 , 95% CI: -7.41 to 5.63 , respectively; Figure 3d). Facet joint violation, from the 10 included studies, was greater in conventional compared with robot-assisted and navigation methods (risk difference: 8.31 [95% CI: -1.52 to 18.13] and 3.02 [95% CI: -5.24 to 11.29], respectively; Figure 3e). Inconsistency testing was achieved ($\chi^2 = 2.74$, $P = 0.0977$).

Overall, the SUCRA hierarchical ranking of estimated probabilities, ranging from 0% to 100%, from NMA was used to grade the accuracy of different

techniques. A higher SUCRA value and a taller bar graph correspond to a higher ranking and higher accuracy rates. Regarding the perfect placement, the superiority of robot-assisted ($S = 83.4$) placement is shown, followed by AR ($S = 81.2$), navigation ($S = 35.4$), and the reference, which is the conventional technique ($S = 0$; Figure 4a). Similarly, safe placement and positive grading for screw malposition are found in the robot-assisted PSP. Lastly, the SUCRA ranking showed the best performance for the least intraoperative screw revision and proximal facet joint violation in the robot-assisted technique (Figure 4a).

Secondary Outcomes

Safety Outcomes

Safety outcomes that were analyzed in this NMA consist of any adverse events, neurological complications (such as neurological deficits and significant painful radiculopathy), wound and infection complications, and reoperation or revision incidences. Wound and infection complications that were reported in the included studies consist of wound problems, such as surgical site infection, seroma formation, wound dehiscence, and delayed wound healing, as well as other non-specific infections, such as urinary tract infections. All analyzed outcomes were tested for inconsistency and showed a global consistency ($\chi^2 = 0.24$, $P = 0.9701$; $\chi^2 = 0.48$, $P = 0.9232$; $\chi^2 = 2.15$, $P = 0.5424$, respectively). There were no AR studies that mentioned the safety aspect; however, safety outcomes have not been

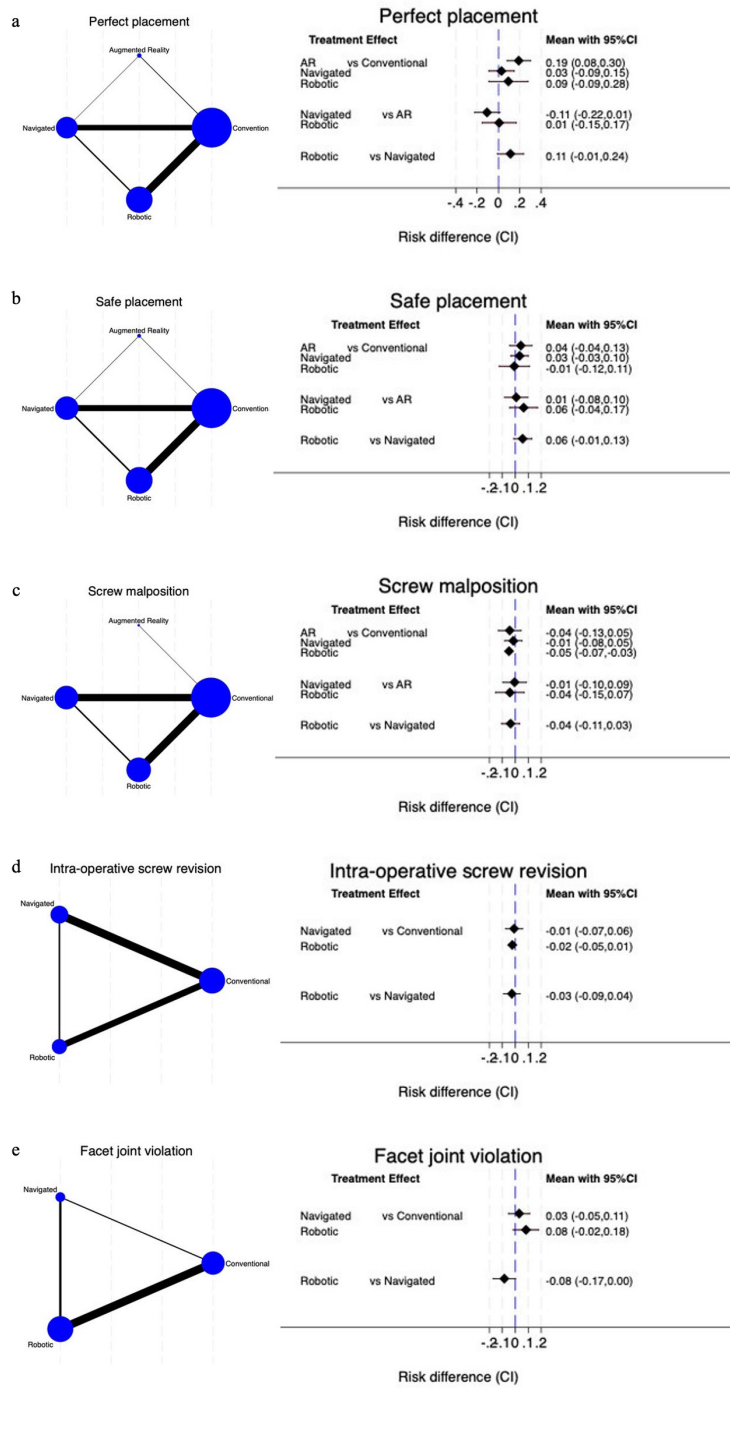
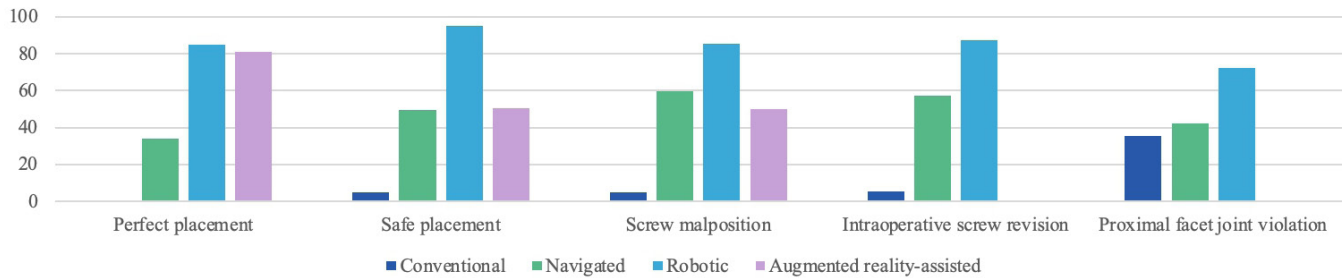


Figure 3. The network geometry (left) and interval plots (right) for accuracy outcomes. (a) Perfect placement, (b) safe placement, (c) screw malposition, (d) intraoperative screw revision, and (e) proximal facet joint violation. Of the network geometry, each circular node represents a type of treatment as labels. The circle size is proportional to the total number of pedicle screws. The width of lines is proportional to the number of studies performing head-to-head comparisons. The interval plots of the risk difference demonstrate treatment effect comparison in the studies.

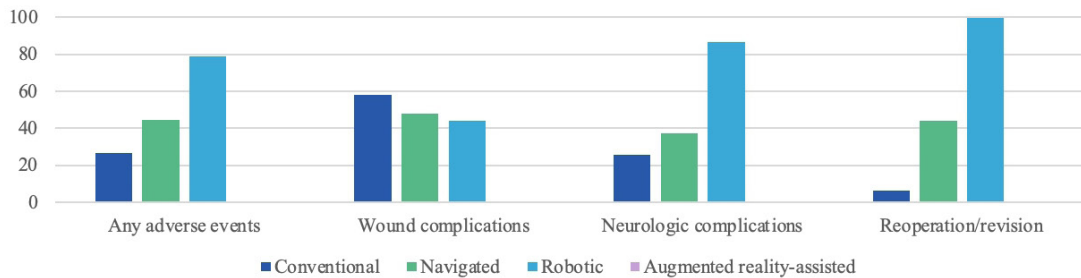
documented in most of the meta-analyses that reported on the PSP. So, we performed NMA across only 3 different methods (conventional, navigation, and robotics) in this study.

Any adverse event was assessed from 15 studies demonstrating insignificantly fewer adverse events in robotics and navigation (risk difference: -3.07 , 95% CI: -18.3 to 12.15 , -2.64 , 95% CI: -37.6 to 32.35 ,

a SUCRA Ranking of Accuracy Outcomes



b SUCRA Ranking of Safety Outcomes



c SUCRA Ranking of Clinical Outcomes

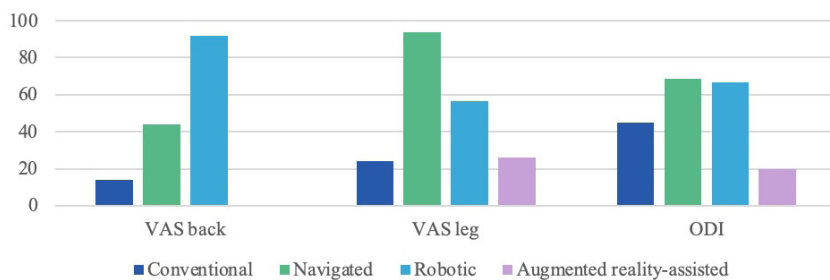


Figure 4. The surface under the cumulative ranking curve (SUCRA) of a treatment hierarchical ranking for the estimated probability of being the best assistive pedicle screw placement method. (a) Accuracy outcomes, (b) safety outcomes, and (c) clinical outcomes. *Abbreviations:* ODI, Oswestry Disability Index; VAS, visual analog scale.

respectively) than those in the conventional method. Nine studies reported neurological complications, whereas wound complications and infection complications were present in 12 studies. Our analysis nonetheless found an insignificant difference across the 3 methods (Figure 5). The SUCRA hierarchy ranking demonstrated superiority in robot-assisted, followed by navigation and then conventional methods for overall complications and neurological complications, whereas the conventional method was ranked the most superior regarding wound complications (Figure 4b).

Reoperation or revision was reported in 14 studies due to several causes, including pseudoarthrosis, infection, instrumentation irritation causing low back pain requiring removal, and radiculopathy requiring revision decompression or screw removal. Three methods of PSP, including conventional, navigation, and robot-assisted, were directly compared. Testing for inconsistency was performed ($\chi^2 = 0.45$, $P = 0.5007$). In comparison to the

conventional method, both robot-assisted and navigation methods showed insignificantly different revision rates (risk difference: 0.9, 95% CI -1.79 to 3.67 , and -0.38 , 95% CI: -1.02 to 0.27 , respectively); however, robot-assisted methods had fewer reoperation rates than navigation (Figure 5d). The SUCRA hierarchy ranking showed the positive value of robot-assisted methods and the most inferior of the conventional method (Figure 4b).

Clinical Outcomes

Differences between the preoperative and postoperative clinical outcomes reported in extracted studies were up to 1-year results consisting of the VAS back, the VAS leg, and the ODI. However, limited data were collected, and the inconsistency model thereby failed to develop. With careful interpretation, 5 studies giving direct comparisons for VAS back reported the most superiority

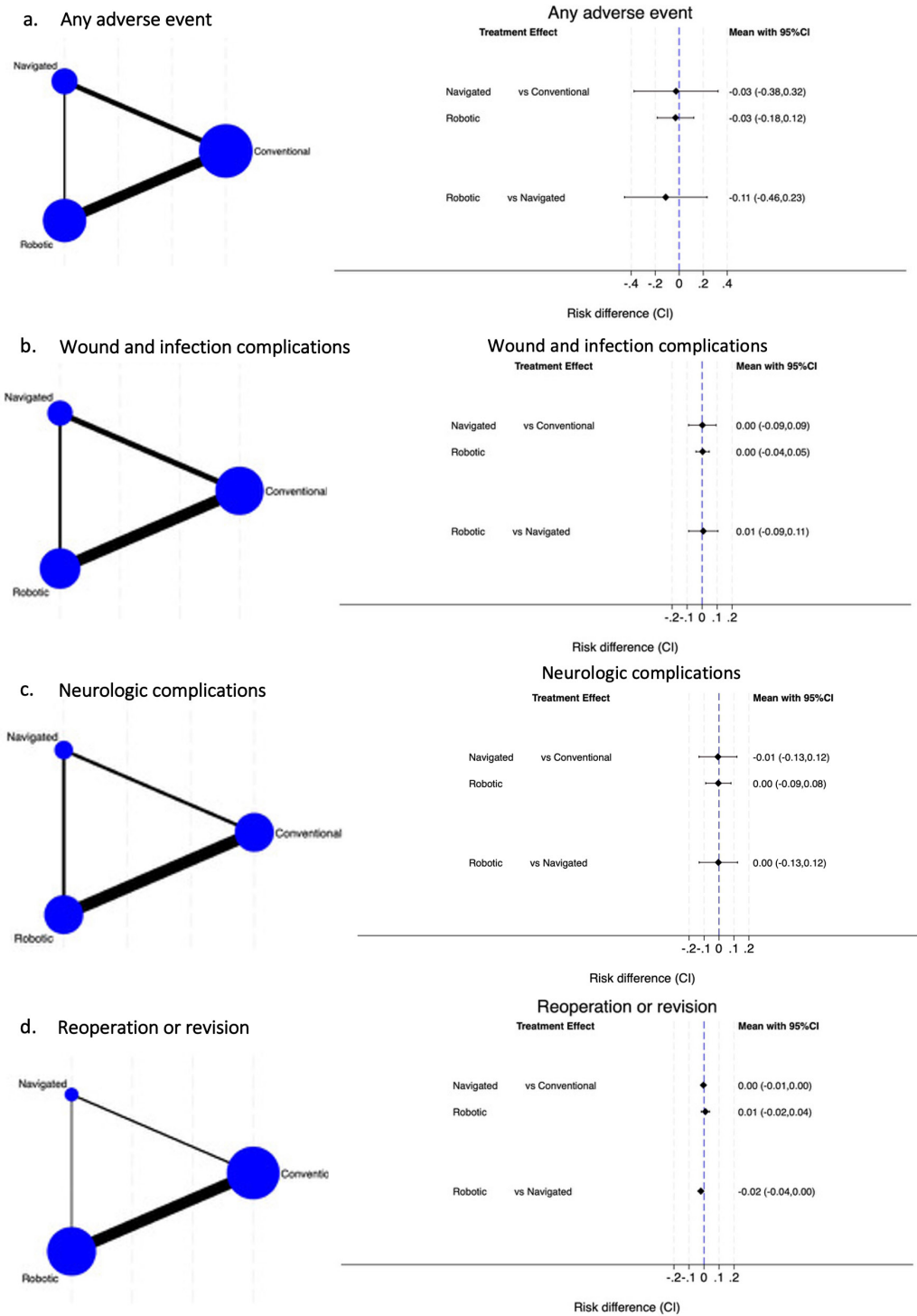


Figure 5. The network geometry (left) and interval plots (right) for safety outcomes. (a) Any adverse event, (b) wound and infection complications, (c) neurological complications, and (d) reoperation or revision.

in robot-assisted methods, followed by navigation and conventional methods. The VAS leg was reported in 7 studies, including a direct comparison of the AR

method (Figure 6). Given the possibility of statistical inconsistencies, careful interpretation is necessary. The SUCRA ranking demonstrated the best improvement in

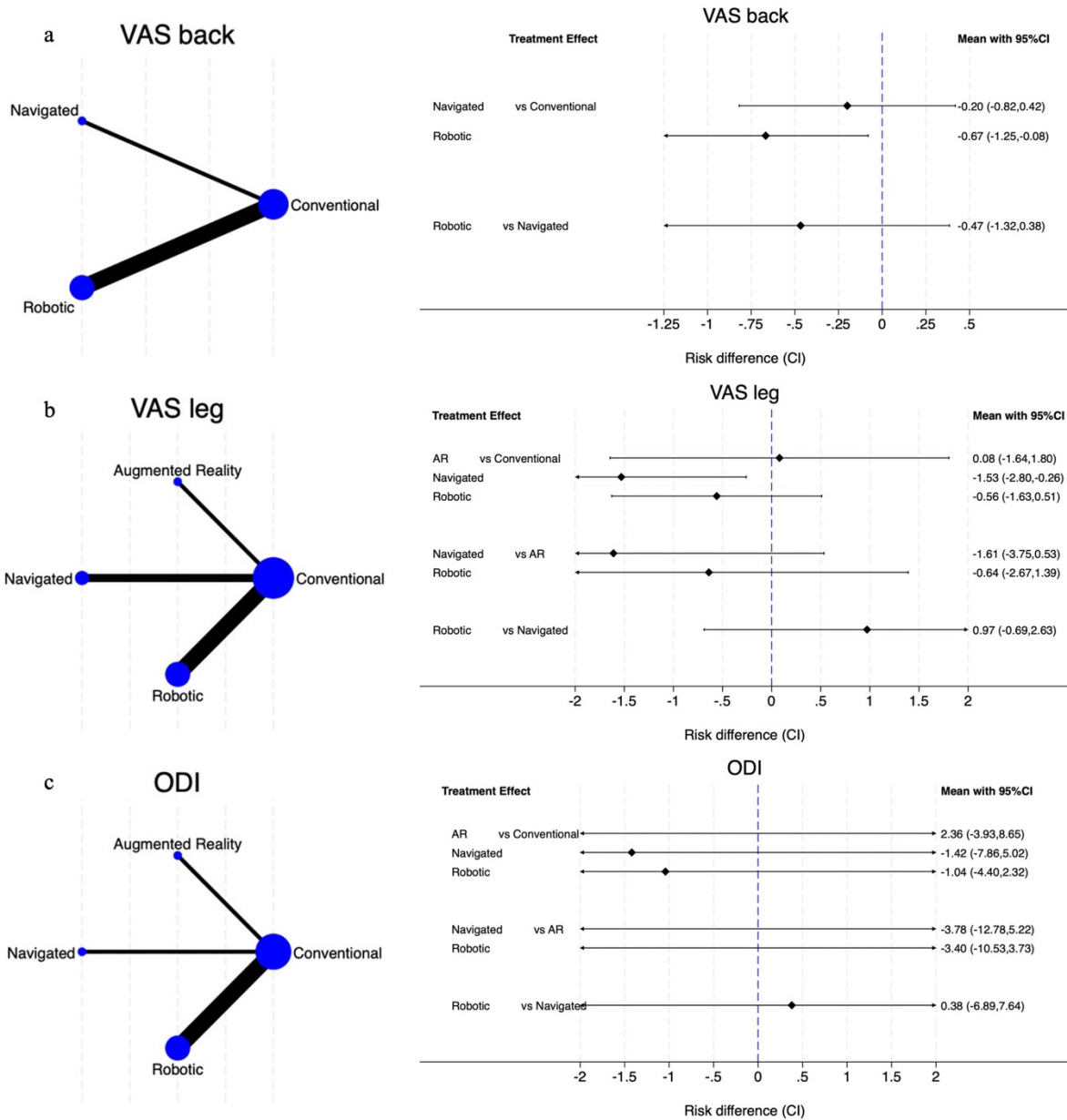


Figure 6. The network geometry (left) and interval plots (right) for clinical outcomes up to 1 year after the index surgery. (a) Visual analog scale (VAS) of the back, (b) VAS leg, and (c) Oswestry Disability Index (ODI).

the navigation group for VAS leg and ODI outcomes (Figure 4c).

Publication Bias

To check for publication bias in NMA, a network funnel plot was made and shown in Figure 7. Visually inspecting for symmetry was clearly demonstrated for the main primary outcomes, namely perfect placement, safe placement, and screw malposition. Additionally, clinical outcomes as well as safety outcomes, namely

any adverse event and wound and infection complication, were also assessed. Intraoperative screw revision, facet joint violation, and reoperation/revision were usually not the major study objective in included studies, and combining smaller studies would likely show asymmetry in these outcomes.

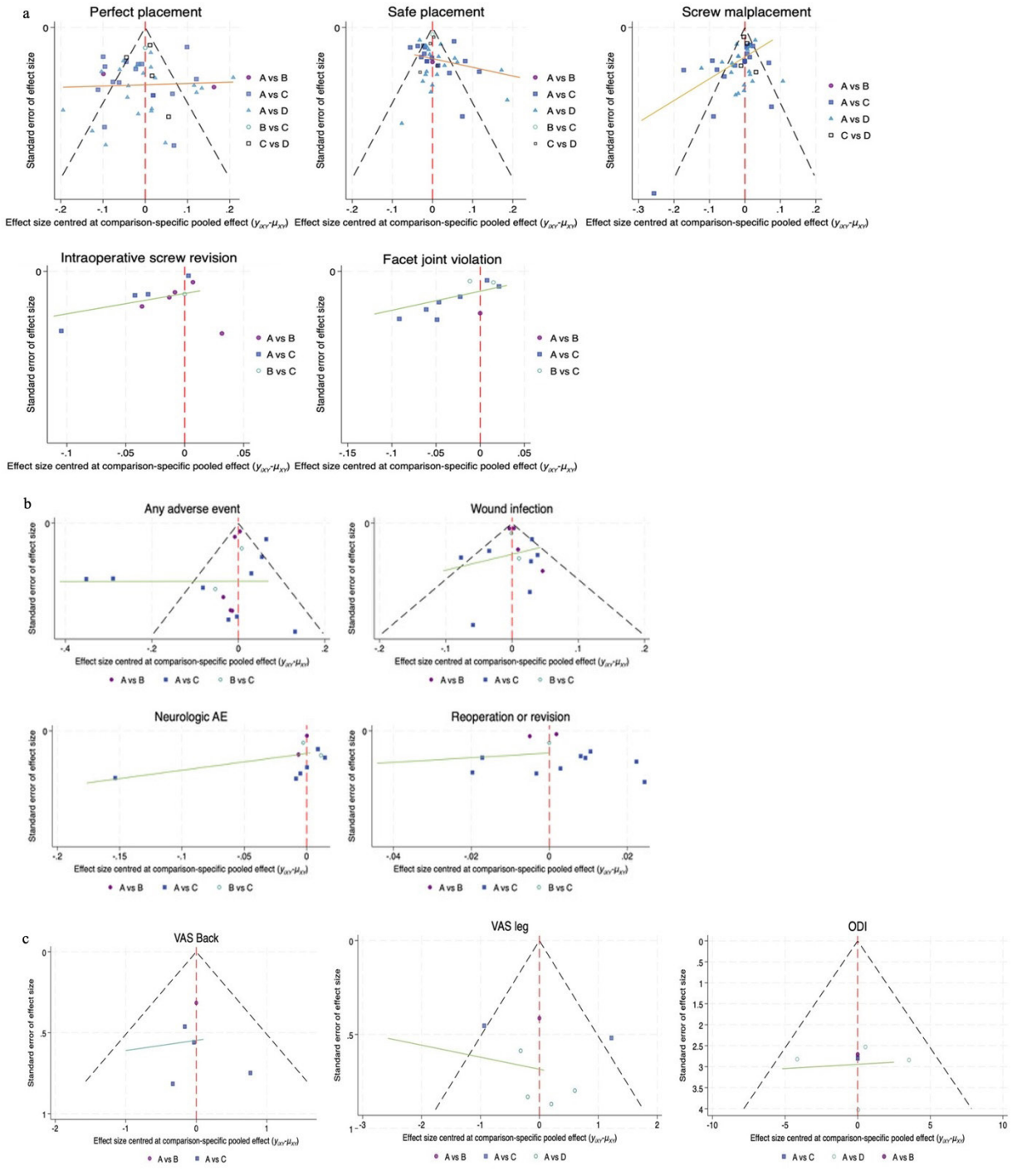


Figure 7. Funnel plots for (a) accuracy, (b) safety, and (c) clinical outcomes.

DISCUSSION

Our study provides the first statistical analyses of different advanced assistive techniques for PSP, including the emerging AR guiding technology. We found that the robot-assisted PSP performed the most accurately

among the various assistive methods. This was followed by AR and navigation, which were more accurate than the conventional method. This was also in accordance with the safety results that the assistance of any techniques might reduce rates of complications.

The accuracy of the PSP is critically important not only in determining the surgical outcomes but also in contributing to the safety of the procedure due to the proximity of vital neurovascular structures to the pedicle area. Recently, advances in assistive technologies, including O-arm-based navigation and robot-assisted methods, have helped improve the accuracy of the PSP. A prior meta-analysis conducted by Staartjes et al,³⁶ which included controlled studies comparing robot-assisted with conventional and navigation methods, showed a reduction in rates of intraoperative screw revision and postoperative revision due to screw malposition. However, there was little evidence of a direct comparison between robot-assisted and navigation systems. Naik et al later reported the NMA of robot-assisted PSP with a comparison to navigation where image references were derived from different techniques: 2D fluoroscope, 3D fluoroscope, and CT or O-arm. Similarly, the robot-assisted method provided the advantages of significantly improving accuracy, perfect, and optimum placement, and reducing complications, even greater than the navigation.³⁷ According to our analyses, we could not obtain statistically significant differences for the superiority of robot-assisted placement accuracy, both perfect and safe placements, despite the first rank from the SUCRA ranking. Besides, intraoperative screw revision and proximal facet joint violation were better with the assistive devices. Greater screw accuracy and precision from robot-assisted approaches were achieved because of the autonomous operation independent of the surgeon, which could reduce risks from human errors. However, the initial system settings and software conditions could influence the effectiveness of its performances, resulting in heterogeneity of results.

For the past few years, reality has been merged with computer-generated displays, known as AR. Evidence has cumulated where AR has been used and tested in proof-of-concept preclinical settings: phantom agar^{38,97} and cadavers.^{12,14,15,98} Several case series and comparative cohort studies suggested not only the high accuracy of screw insertion^{20,99–102} but also the additional benefits of reducing radiation exposure²³ and operative time.¹⁹ Since the technology is still in its infancy, there has been no study comparing it with other advanced methods except for the conventional method.¹⁰³ Thus, we utilized NMA to obtain a bird's-eye view of the aiding technologies. As a result of our analysis, AR produced significantly more perfectly placed screws compared with the conventional method and ranked second to the robot-assisted method concerning SUCRA probabilities.

Safety outcomes bluntly resulted from the screw accuracy, where common reasons leading to reoperation were painful radiculopathy or nerve root injury due to screw malposition, as stated in the included studies. Based on our analyses, the robot-assisted method reported fewer complications than navigation, and navigation reported a smaller number of adverse events compared with the conventional technique. This finding was aligned with a prior meta-analysis.³⁷ Due to the fact that clinical outcomes were not commonly investigated for assessing the effectiveness of different techniques, a small number of studies were derived for analyses. Therefore, the analysis was not sufficiently powered to draw a meaningful conclusion. In addition, there were wide ranges of diagnoses and operations that directly affected clinical/surgical outcomes.

Although this NMA was able to determine only the possibility of superiority between different assisting technologies, it did demonstrate the impact of advancements in technology that may help improve surgical outcomes. Combining the 2 techniques could also enhance their advantages even further. For example, surgeons could supervise autonomous robotics using AR technologies.¹⁰⁴

As an NMA, the present study has some limitations. To obtain a comprehensive sample, we included both RCTs and comparative studies. There were a variety of image guidance systems for navigation, including 2D fluoroscopy, 3D fluoroscopy, and CT or O-arm, which we mentioned in detail if presented, in the characteristic table of the included studies. Also, there were various types of robot-assisted systems in the studies, and we did not compare each system in this NMA. Last, due to the recent development of AR technology, there have been only a small number of studies, resulting in the limited power of direct comparison; nonetheless, this study utilized the NMA method to gain a better understanding of the usefulness of the novel technique.

CONCLUSIONS

The robot-assisted methods achieved the most superior accuracy of PSP, whereas the safety and functional outcomes of the different methods were comparable. The AR technology provided better accuracy compared with navigation and conventional techniques.

ACKNOWLEDGMENTS

Teerachat Tanasansomboon expresses his heartfelt gratitude to his wife, Thanachaporn Kittipibul, for her unwavering dedication. They joyfully welcome their baby boy “Darwin” into this world.

REFERENCES

- Walker CT, Kakarla UK, Chang SW, Sonntag VKH. History and advances in spinal neurosurgery. *J Neurosurg Spine*. 2019;31(6):775–785. doi:10.3171/2019.9.SPINE181362
- Cho W, Cho SK, Wu C. The biomechanics of pedicle screw-based instrumentation. *J Bone Joint Surg Br*. 2010;92(8):1061–1065. doi:10.1302/0301-620X.92B8.24237
- Perna F, Borghi R, Pilla F, Stefanini N, Mazzotti A, Chehrassan M. Pedicle screw insertion techniques: an update and review of the literature. *Musculoskelet Surg*. 2016;100(3):165–169. doi:10.1007/s12306-016-0438-8
- Ebraheim NA, Xu R, Darwich M, Yeasting RA. Anatomic relations between the lumbar pedicle and the adjacent neural structures. *Spine*. 1997;22(20):2338–2341. doi:10.1097/00007632-199710150-00003
- Gertzbein SD, Robbins SE. Accuracy of pedicular screw placement in vivo. *Spine*. 1990;15(1):11–14. doi:10.1097/00007632-199001000-00004
- Otomo N, Funao H, Yamanouchi K, Isogai N, Ishii K. Computed tomography-based navigation system in current spine surgery: a narrative review. *Medicina*. 2022;58(2):241. doi:10.3390/medicina58020241
- Baldwin KD, Kadiyala M, Talwar D, Sankar WN, Flynn JJM, Anari JB. Does intraoperative CT navigation increase the accuracy of pedicle screw placement in pediatric spinal deformity surgery? a systematic review and meta-analysis. *Spine Deform*. 2022;10(1):19–29. doi:10.1007/s43390-021-00385-5
- Tian W, Zeng C, An Y, Wang C, Liu Y, Li J. Accuracy and postoperative assessment of pedicle screw placement during scoliosis surgery with computer-assisted navigation: a meta-analysis. *Int J Med Robot*. 2017;13(1). doi:10.1002/rcs.1732
- Tian N-F, Huang Q-S, Zhou P, et al. Pedicle screw insertion accuracy with different assisted methods: a systematic review and meta-analysis of comparative studies. *Eur Spine J*. 2011;20(6):846–859. doi:10.1007/s00586-010-1577-5
- Naik A, MacInnis BR, Shaffer A, et al. Trends in technology for pedicle screw placement: a temporal meta-analysis. *Spine*. 1976;48(11):791–799. doi:10.1097/BRS.0000000000004604
- Guha D, Alotaibi NM, Nguyen N, Gupta S, McFaul C, Yang VXD. Augmented reality in neurosurgery: a review of current concepts and emerging applications. *Can J Neurol Sci*. 2017;44(3):235–245. doi:10.1017/cjn.2016.443
- Spirig JM, Roner S, Liebmann F, Fürnstahl P, Farshad M. Augmented reality-navigated pedicle screw placement: a cadaveric pilot study. *Eur Spine J*. 2021;30(12):3731–3737. doi:10.1007/s00586-021-06950-w
- Dennler C, Jaberg L, Spirig J, et al. Augmented reality-based navigation increases precision of pedicle screw insertion. *J Orthop Surg Res*. 2020;15(1):174. doi:10.1186/s13018-020-01690-x
- Molina CA, Theodore N, Ahmed AK, et al. Augmented reality-assisted pedicle screw insertion: a cadaveric proof-of-concept study. *J Neurosurg Spine*. 2019;31(1):139–146. doi:10.3171/2018.12.SPINE181142
- Molina CA, Phillips FM, Colman MW, et al. A cadaveric precision and accuracy analysis of augmented reality-mediated percutaneous pedicle implant insertion. *J Neurosurg Spine*. 2020;34(2):316–324. doi:10.3171/2020.6.SPINE20370
- Siemionow KB, Katchko KM, Lewicki P, Luciano CJ. Augmented reality and artificial intelligence-assisted surgical navigation: technique and cadaveric feasibility study. *J Craniovertebr Junction Spine*. 2020;11(2):81–85. doi:10.4103/jcvjs.JCVJS_48_20
- Farshad M, Spirig JM, Suter D, et al. Operator independent reliability of direct augmented reality navigated pedicle screw placement and rod bending. *N Am Spine Soc J*. 2021;8:100084. doi:10.1016/j.xnsj.2021.100084
- Yanni DS, Ozgur BM, Louis RG, et al. Real-time navigation guidance with intraoperative CT imaging for pedicle screw placement using an augmented reality head-mounted display: a proof-of-concept study. *Neurosurg Focus*. 2021;51(2):2021.5.FOCUS21209. doi:10.3171/2021.5.FOCUS21209
- Charles YP, Cazzato RL, Nachabe R, Chatterjea A, Steib J-P, Gangi A. Minimally invasive transforaminal lumbar interbody fusion using augmented reality surgical navigation for percutaneous pedicle screw placement. *Clin Spine Surg*. 2021;34(7):E415–E424. doi:10.1097/BSD.0000000000001132
- Yahanda AT, Moore E, Ray WZ, Pennicooke B, Jennings JW, Molina CA. First in-human report of the clinical accuracy of thoracolumbar percutaneous pedicle screw placement using augmented reality guidance. *Neurosurg Focus*. 2021;51(2):e1217. doi:10.3171/2021.5.FOCUS21217
- Butler AJ, Colman MW, Lynch J, Phillips FM. Augmented reality in minimally invasive spine surgery: early efficiency and complications of percutaneous pedicle screw instrumentation. *Spine J*. 2023;23(1):27–33. doi:10.1016/j.spinee.2022.09.008
- Burström G, Nachabe R, Persson O, Edström E, Elmi Terander A. Augmented and virtual reality instrument tracking for minimally invasive spine surgery: a feasibility and accuracy study. *Spine*. 2019;44(15):1097–1104. doi:10.1097/BRS.0000000000003006
- Edström E, Burström G, Omar A, et al. Augmented reality surgical navigation in spine surgery to minimize staff radiation exposure. *Spine*. 2020;45(1):E45–E53. doi:10.1097/BRS.0000000000003197
- Page MJ, McKenzie JE, Bossuyt PM, et al. The PRISMA 2020 statement: an updated guideline for reporting systematic reviews. *BMJ*. 2021;372:n71. doi:10.1136/bmj.n71
- Allam Y, Silbermann J, Riese F, Greiner-Perth R. Computer tomography assessment of pedicle screw placement in thoracic spine: comparison between free hand and a generic 3D-based navigation techniques. *Eur Spine J*. 2013;22(3):648–653. doi:10.1007/s00586-012-2505-7
- Alqurashi A, Alomar SA, Bakhaidar M, Alfiky M, Baesa SS. Accuracy of pedicle screw placement using intraoperative CT-guided navigation and conventional fluoroscopy for lumbar spondylosis. *Cureus*. 2021;13(8):e17431. doi:10.7759/cureus.17431
- Rampersaud YR, Pik JHT, Salonen D, Farooq S. Clinical accuracy of fluoroscopic computer-assisted pedicle screw fixation: a CT analysis. *Spine*. 2005;30(7):E183–E190. doi:10.1097/01.brs.0000157490.65706.38
- Learch TJ, Massie JB, Pathria MN, Ahlgren BA, Garfin SR. Assessment of pedicle screw placement utilizing conventional radiography and computed tomography: a proposed systematic approach

- to improve accuracy of interpretation. *Spine*. 2004;29(7):767–773. doi:10.1097/01.brs.0000112071.69448.a1
29. Kim T-H, Lee BH, Moon S-H, Lee S-H, Lee H-M. Comparison of adjacent segment degeneration after successful posterolateral fusion with unilateral or bilateral pedicle screw instrumentation: a minimum 10-year follow-up. *Spine J*. 2013;13(10):1208–1216. doi:10.1016/j.spinee.2013.07.431
30. Babu R, Park JG, Mehta AI, et al. Comparison of superior-level facet joint violations during open and percutaneous pedicle screw placement. *Neurosurgery*. 2012;71(5):962–970. doi:10.1227/NEU.0b013e31826a88c8
31. White IR. Network meta-analysis. *Stata J*. 2015;15(4):951–985. doi:10.1177/1536867X1501500403
32. Karamian BA, DiMaria SL, Sawires AN, et al. Clinical outcomes of robotic versus freehand pedicle screw placement after one-to three-level lumbar fusion. *Global Spine J*. 2023;13(7):1871–1877. doi:10.1177/21925682211057491
33. Higgins JPT, Green S, eds. 16.1.3.2 imputing standard deviations for changes from baseline. In: *The Cochrane Collaboration Cochrane Handbook for Systematic Reviews of Interventions*. The Cochrane Collaboration; 2011. www.handbook.cochrane.org.
34. Stang A. Critical evaluation of the newcastle-ottawa scale for the assessment of the quality of nonrandomized studies in meta-analyses. *Eur J Epidemiol*. 2010;25(9):603–605. doi:10.1007/s10654-010-9491-z
35. Higgins JP, Savović J, Page MJ, Elbers RG, Sterne JA. Assessing risk of bias in a randomized trial. In: Higgins JPT, Thomas J, Chandler J, et al, eds. *Cochrane Handbook for Systematic Reviews of Interventions*. Cochrane; 2019:205–228. doi:10.1002/9781119536604
36. Staartjes VE, Klukowska AM, Schröder ML. Pedicle screw revision in robot-guided, navigated, and freehand thoracolumbar instrumentation: a systematic review and meta-analysis. *World Neurosurg*. 2018;116:433–443. doi:10.1016/j.wneu.2018.05.159
37. Naik A, Smith AD, Shaffer A, et al. Evaluating robotic pedicle screw placement against conventional modalities: a systematic review and network meta-analysis. *Neurosurg Focus*. 2022;52(1):2021.10.FOCUS21509. doi:10.3171/2021.10.FOCUS21509
38. Müller F, Roner S, Liebmann F, Spirig JM, Fürnstahl P, Farshad M. Augmented reality navigation for spinal pedicle screw instrumentation using intraoperative 3D imaging. *Spine J*. 2020;20(4):621–628. doi:10.1016/j.spinee.2019.10.012
39. Baky FJ, Milbrandt T, Echternacht S, Stans AA, Shaughnessy WJ, Larson AN. Intraoperative computed tomography-guided navigation for pediatric spine patients reduced return to operating room for screw malposition compared with freehand/fluoroscopic techniques. *Spine Deformity*. 2019;7(4):S2212-134X(18)30290-9:577–581. doi:10.1016/j.jspd.2018.11.012
40. Bovonratwet P, Nelson SJ, Ondeck NT, Geddes BJ, Grauer JN. Comparison of 30-day complications between navigated and conventional single-level instrumented posterior lumbar fusion. *Spine*. 2018;43(6):447–453. doi:10.1097/BRS.0000000000002327
41. Budu A, Sims-Williams H, Radatz M, et al. Comparison of navigated versus fluoroscopic-guided pedicle screw placement accuracy and complication rate. *World Neurosurg*. 2020;144:e541–e545. doi:10.1016/j.wneu.2020.08.207
42. Crawford BD, Nchako CM, Rebehn KA, Israel H, Place HM. Transpedicular screw placement accuracy using the O-arm versus freehand technique at a single institution. *Global Spine J*. 2022;12(3):447–451. doi:10.1177/2192568220956979
43. De Biase G, Gassie K, Garcia D, et al. Perioperative comparison of robotic-assisted versus fluoroscopically guided minimally invasive transforaminal lumbar interbody fusion. *World Neurosurg*. 2021;149:e570–e575. doi:10.1016/j.wneu.2021.01.133
44. Du J, Gao L, Huang D, et al. Radiological and clinical differences between tinavi orthopedic robot and O-arm navigation system in thoracolumbar screw implantation for reconstruction of spinal stability. *Med Sci Monitor*. 2020;26:e924770. doi:10.12659/MSM.924770
45. Edström E, Burström G, Persson O, et al. Does augmented reality navigation increase pedicle screw density compared to free-hand technique in deformity surgery? single surgeon case series of 44 patients. *Spine*. 2020;45(17):E1085–E1090. doi:10.1097/BRS.00000000000003518
46. Elmi-Terander A, Burström G, Nachabé R, et al. Augmented reality navigation with intraoperative 3D imaging vs fluoroscopy-assisted free-hand surgery for spine fixation surgery: a matched-control study comparing accuracy. *Sci Rep*. 2020;10:707. https://doi.org/10.1038/s41598-020-57693-5.
47. Fan Y, Du J, Zhang J, et al. Comparison of accuracy of pedicle screw insertion among 4 guided technologies in spine surgery. *Med Sci Monitor*. 2017;23:5960–5968. doi:10.12659/msm.905713
48. Fayed I, Tai A, Triano M, et al. Robot-assisted percutaneous pedicle screw placement: evaluation of accuracy of the first 100 screws and comparison with cohort of fluoroscopy-guided screws. *World Neurosurg*. 2020;143:e492–e502. doi:10.1016/j.wneu.2020.07.203
49. Fraser J, Gebhard H, Irie D, Parikh K, Härtl R. Iso-C/3-dimensional neuronavigation versus conventional fluoroscopy for minimally invasive pedicle screw placement in lumbar fusion. *Minim Invasive Neurosurg*. 2010;53(4):184–190. doi:10.1055/s-0030-1267926
50. Fu T-S, Wong C-B, Tsai T-T, Liang Y-C, Chen L-H, Chen W-J. Pedicle screw insertion: computed tomography versus fluoroscopic image guidance. *Int Orthop*. 2008;32(4):517–521. doi:10.1007/s00264-007-0358-1
51. Gao S, Wei J, Li W, et al. Accuracy of robot-assisted percutaneous pedicle screw placement under regional anesthesia: A retrospective cohort study. *Pain Res Manag*. 2021;2021:6894001:6894001. doi:10.1155/2021/6894001
52. García-Fantini M, De Casas R. Three-dimensional fluoroscopic navigation versus fluoroscopy-guided placement of pedicle screws in L4-L5-S1 fixation: single-centre experience of pedicular accuracy and S1 cortical fixation of 810 screws. *J Spine Surg (Hong Kong)*. 2018;4(4):736–743. doi:10.21037/jss.2018.10.03
53. Good CR, Orosz L, Schroerlucke SR, et al. Complications and revision rates in minimally invasive robotic-guided versus fluoroscopic-guided spinal fusions: the MIS refresh prospective comparative study. *Spine*. 2021;46(23):1661–1668. doi:10.1097/BRS.00000000000004048
54. Gu Y, Yao Q, Xu Y, Zhang H, Wei P, Wang L. A clinical application study of mixed reality technology assisted lumbar pedicle screws implantation. *Med Sci Monitor*. 2020;26:e924982. doi:10.12659/MSM.924982
55. Han W, Zhong-li G, Jin-Cheng W, et al. Pedicle screw placement in the thoracic spine: A comparison study of computer-assisted navigation and conventional techniques. *Orthopedics*. 2010;33(8). doi:10.3928/01477447-20100625-14
56. Han X, Tian W, Liu Y, et al. Safety and accuracy of robot-assisted versus fluoroscopy-assisted pedicle screw insertion

in thoracolumbar spinal surgery: a prospective randomized controlled trial. *Journal of Neurosurgery*. 2019;30(5):615–622. doi:10.3171/2018.10.SPINE18487

57. Hyun S-J, Kim K-J, Jahng T-A, Kim H-J. Minimally invasive robotic versus open fluoroscopic-guided spinal instrumented fusions. *Spine*. 2017;42(6):353–358. doi:10.1097/BRS.0000000000001778

58. Ishikawa Y, Kanemura T, Yoshida G, Ito Z, Muramoto A, Ohno S. Clinical accuracy of three-dimensional fluoroscopy-based computer-assisted cervical pedicle screw placement: a retrospective comparative study of conventional versus computer-assisted cervical pedicle screw placement. *J Neurosurg*. 2010;13(5):606–611. doi:10.3171/2010.5.SPINE09993

59. Jin M, Liu Z, Liu X, et al. Does intraoperative navigation improve the accuracy of pedicle screw placement in the apical region of dystrophic scoliosis secondary to neurofibromatosis type I: comparison between O-arm navigation and free-hand technique. *Eur Spine J*. 2016;25(6):1729–1737. doi:10.1007/s00586-015-4012-0

60. Katsevan GA, Spencer RD, Daffner SD, et al. Robotic-navigated percutaneous pedicle screw placement has less facet joint violation than fluoroscopy-guided percutaneous screws. *World Neurosurg*. 2021;151:S1878-8750(21)00660-4:e731–e737. doi:10.1016/j.wneu.2021.04.117

61. Khanna AR, Yanamadala V, Coumans J-V. Effect of intraoperative navigation on operative time in 1-level lumbar fusion surgery. *J Clin Neurosci*. 2016;32:72–76. doi:10.1016/j.jocn.2016.02.033

62. Kim H, Jung W, Chang B, Lee C, Kang K, Yeom JS. A prospective, randomized, controlled trial of robot-assisted vs freehand pedicle screw fixation in spine surgery. *Int J Med Robot*. 2017;13(3). <https://onlinelibrary.wiley.com/toc/1478596x/13/3>. doi:10.1002/rcs.1779

63. Kim H, Kang K, Chun H, et al. Comparative study of 1-year clinical and radiological outcomes using robot-assisted pedicle screw fixation and freehand technique in posterior lumbar interbody fusion: A prospective, randomized controlled trial. *Int J Med Robot*. 2018;14(4). doi:10.1002/rcs.1917

64. Laine T, Lund T, Ylikoski M, Lohikoski J, Schlenzka D. Accuracy of pedicle screw insertion with and without computer assistance: a randomised controlled clinical study in 100 consecutive patients. *Eur Spine J*. 2000;9(3):235–240. doi:10.1007/s005860000146

65. Lai Y-P, Lin Y-H, Wu Y-C, et al. Robot-assisted pedicle screw placement led to lower screw loosening rate than fluoroscopy-guided technique in transforaminal lumbar interbody fusion for lumbar degenerative disease: a single-center retrospective study. *J Clin Med*. 2022;11(17):4989. doi:10.3390/jcm11174989

66. Laudato PA, Pierzchala K, Schizas C. Pedicle screw insertion accuracy using O-arm, robotic guidance, or free-hand technique. *Spine*. 2018;43(6):E373–E378. doi:10.1097/BRS.0000000000002449

67. Lau D, Terman SW, Patel R, La Marca F, Park P. Incidence of and risk factors for superior facet violation in minimally invasive versus open pedicle screw placement during transforaminal lumbar interbody fusion: a comparative analysis. *J Neurosurg*. 2013;18(4):356–361. doi:10.3171/2013.1.SPINE12882

68. Liounakos JI, Kumar V, Jamshidi A, et al. Reduction in complication and revision rates for robotic-guided short-segment lumbar fusion surgery: results of a prospective, multi-center study. *J Robot Surg*. 2021;15(5):793–802. doi:10.1007/s11701-020-01165-5

69. Li Z, Chen J, Zhu Q-A, et al. A preliminary study of a novel robotic system for pedicle screw fixation: a randomised controlled trial. *J Orthop Transl*. 2020;20:73–79. doi:10.1016/j.jot.2019.09.002

70. Lonjon N, Chan-Seng E, Costalat V, Bonnafoux B, Vassal M, Boetto J. Robot-assisted spine surgery: feasibility study through a prospective case-matched analysis. *Eur Spine J*. 2016;25(3):947–955. doi:10.1007/s00586-015-3758-8

71. Malham GM, Munday NR. Comparison of novel machine vision spinal image guidance system with existing 3D fluoroscopy-based navigation system: a randomized prospective study. *Spine J*. 2022;22(4):561–569. doi:10.1016/j.spinee.2021.10.002

72. Molliqaj G, Schatlo B, Alaid A, et al. Accuracy of robot-guided versus freehand fluoroscopy-assisted pedicle screw insertion in thoracolumbar spinal surgery. *Neurosurg Focus*. 2017;42(5):E14. doi:10.3171/2017.3.FOCUS179

73. Noshchenko A, Cain CMJ, Zaghoul K, et al. Pedicle screw placement assisted by 3D imaging (O-arm system with stealthstation® software) versus free-hand technique for multilevel posterior thoracolumbar fusion. *Curr Orthop Pract*. 2018;29(2):151–156. doi:10.1097/BCO.0000000000000601

74. Pendharkar AV, Rezaii PG, Ho AL, et al. Conventional versus stereotactic image-guided pedicle screw placement during posterior lumbar fusions. *Spine*. 2019;44(21):E1272–E1280. doi:10.1097/BRS.0000000000003130

75. Rajasekaran S, Vidyadhara S, Ramesh P, Shetty AP. Randomized clinical study to compare the accuracy of navigated and non-navigated thoracic pedicle screws in deformity correction surgeries. *Spine*. 2007;32(2):E56–E64. doi:10.1097/01.brs.0000252094.64857.ab

76. Ringel F, Stüer C, Reinke A, et al. Accuracy of robot-assisted placement of lumbar and sacral pedicle screws. *Spine*. 2012;37(8):E496–E501. doi:10.1097/BRS.0b013e31824b7767

77. Ruatti S, Dubois C, Chipon E, et al. Interest of intraoperative 3D imaging in spine surgery: a prospective randomized study. *Eur Spine J*. 2016;25(6):1738–1744. doi:10.1007/s00586-015-4141-5

78. Schatlo B, Molliqaj G, Cuvinciuc V, Kotowski M, Schaller K, Tessitore E. Safety and accuracy of robot-assisted versus fluoroscopy-guided pedicle screw insertion for degenerative diseases of the lumbar spine: a matched cohort comparison. *J Neurosurg*. 2014;20(6):636–643. doi:10.3171/2014.3.SPINE13714

79. Schizas C, Thein E, Kwiatkowski B, Kulik G. Pedicle screw insertion: robotic assistance versus conventional C-arm fluoroscopy. *Acta Orthopaedica Belgica*. 2012;78(2):240–245.

80. Shafi KA, Pompeu YA, Vaishnav AS, et al. Does robot-assisted navigation influence pedicle screw selection and accuracy in minimally invasive spine surgery? *Neurosurg Focus*. 2022;52(1):E4. doi:10.3171/2021.10.FOCUS21526

81. Shi B, Jiang T, Du H, Zhang W, Hu L, Zhang L. Application of spinal robotic navigation technology to minimally invasive percutaneous treatment of spinal fractures: A clinical, non-randomized, controlled study. *Orthop Surg*. 2021;13(4):1236–1243. doi:10.1111/os.12993

82. Shin M-H, Hur J-W, Ryu K-S, Park C-K. Prospective comparison study between the fluoroscopy-guided and navigation coupled with O-arm-guided pedicle screw placement in the thoracic and lumbosacral spines. *J Spinal Disord Tech*. 2015;28(6):E347–E351. doi:10.1097/BSD.0b013e31829047a7

83. Silbermann J, Riese F, Allam Y, Reichert T, Koepfert H, Gutberlet M. Computer tomography assessment of pedicle

screw placement in lumbar and sacral spine: comparison between free-hand and O-arm based navigation techniques. *Eur Spine J*. 2011;20(6):875–881. doi:10.1007/s00586-010-1683-4

84. Solomiichuk V, Fleischhammer J, Molliqaj G, et al. Robotic versus fluoroscopy-guided pedicle screw insertion for metastatic spinal disease: a matched-cohort comparison. *Neurosurg Focus*. 2017;42(5):E13. doi:10.3171/2017.3.FOCUS1710

85. Su X-J, Lv Z-D, Chen Z, et al. Comparison of accuracy and clinical outcomes of robot-assisted versus fluoroscopy-guided pedicle screw placement in posterior cervical surgery. *Global Spine J*. 2022;12(4):620–626. doi:10.1177/2192568220960406

86. Boon Tow BP, Yue WM, Srivastava A, et al. Does navigation improve accuracy of placement of pedicle screws in single-level lumbar degenerative spondylolisthesis? *J Spinal Disord Tech*. 2015;28(8):E472–E477. doi:10.1097/BSD.0b013e3182a9435e

87. Urbanski W, Jurasz W, Wolanczyk M, et al. Increased radiation but no benefits in pedicle screw accuracy with navigation versus a freehand technique in scoliosis surgery. *Clin Orthop Relat Res*. 2018;476(5):1020–1027. doi:10.1007/s11999.0000000000000204

88. Wang C, Zhang H, Zhang L, et al. Accuracy and deviation analysis of robot-assisted spinal implants: a retrospective overview of 105 cases and preliminary comparison to open freehand surgery in lumbar spondylolisthesis. *Int J Med Robot*. 2021;17(4). <https://onlinelibrary.wiley.com/doi/10.1002/rcs.2273>

89. Wang Y, Chen K, Chen H, et al. Comparison between free-hand and O-arm-based navigated posterior lumbar interbody fusion in elderly cohorts with three-level lumbar degenerative disease. *Int Orthop*. 2019;43(2):351–357. doi:10.1007/s00264-018-4005-9

90. Waschke A, Walter J, Duenisch P, Reichart R, Kalff R, Ewald C. CT-navigation versus fluoroscopy-guided placement of pedicle screws at the thoracolumbar spine: single center experience of 4,500 screws. *Eur Spine J*. 2013;22(3):654–660. doi:10.1007/s00586-012-2509-3

91. Wu H, Gao Z, Wang J, Li Y, Xia P, Jiang R. Pedicle screw placement in the thoracic spine: a randomized comparison study of computer-assisted navigation and conventional techniques. *Chin J Trauma*. 2010;13(4):201–205.

92. Yang J-S, He B, Tian F, et al. Accuracy of robot-assisted percutaneous pedicle screw placement for treatment of lumbar spondylolisthesis: A comparative cohort study. *Med Sci Monitor*. 2019;25:2479–2487. doi:10.12659/MSM.913124

93. Yan K, Zhang Q, Tian W. Comparison of accuracy and safety between second-generation trobot-assisted and free-hand thoracolumbar pedicle screw placement. *BMC Surg*. 2022;22(1):275. doi:10.1186/s12893-022-01723-8

94. Zhang J-N, Fan Y, He X, Liu T-J, Hao D-J. Comparison of robot-assisted and freehand pedicle screw placement for lumbar revision surgery. *Int Orthop*. 2021;45(6):1531–1538. doi:10.1007/s00264-020-04825-1

95. Zhang Q, Han X-G, Xu Y-F, et al. Robot-assisted versus fluoroscopy-guided pedicle screw placement in transforaminal lumbar interbody fusion for lumbar degenerative disease. *World Neurosurg*. 2019;125:e429–e434. doi:10.1016/j.wneu.2019.01.097

96. Zhang Q, Xu Y-F, Tian W, et al. Comparison of superior-level facet joint violations between robot-assisted percutaneous pedicle screw placement and conventional open fluoroscopic-guided pedicle screw placement. *Orthop Surg*. 2019;11(5):850–856. doi:10.1111/os.12534

97. Liu H, Wu J, Tang Y, et al. Percutaneous placement of lumbar pedicle screws via intraoperative CT image-based augmented reality-guided technology. *J Neurosurg Spine*. 2019;32(4):542–547. doi:10.3171/2019.10.SPINE19969

98. Cao B, Yuan B, Xu G, et al. A pilot human cadaveric study on accuracy of the augmented reality surgical navigation system for thoracolumbar pedicle screw insertion using a new intraoperative rapid registration method. *J Digit Imaging*. 2023;36(4):1919–1929. doi:10.1007/s10278-023-00840-x

99. Elmi-Terander A, Burström G, Nachabe R, et al. Pedicle screw placement using augmented reality surgical navigation with intraoperative 3d imaging: a first in-human prospective cohort study. *Spine*. 2019;44(7):517–525. doi:10.1097/BRS.0000000000002876

100. Molina CA, Sciubba DM, Greenberg JK, Khan M, Witham T. Clinical accuracy, technical precision, and workflow of the first in human use of an augmented-reality head-mounted display stereotactic navigation system for spine surgery. *Oper Neurosurg*. 2021;20(3):300–309. doi:10.1093/ons/opaa398

101. Siemionow KB, Forsthoefel CW, Foy MP, Gawel D, Luciano CJ. Autonomous lumbar spine pedicle screw planning using machine learning: a validation study. *J Craniovertebr Junction Spine*. 2021;12(3):223–227. doi:10.4103/jcvjs.jcvjs_94_21

102. Liu A, Jin Y, Cottrill E, et al. Clinical accuracy and initial experience with augmented reality-assisted pedicle screw placement: the first 205 screws. *J Neurosurg Spine*. 2022;36(3):351–357. doi:10.3171/2021.2.SPINE202097

103. Sumdani H, Aguilar-Salinas P, Avila MJ, Barber SR, Dumont T. Utility of augmented reality and virtual reality in spine surgery: a systematic review of the literature. *World Neurosurg*. 2022;161:e8–e17. doi:10.1016/j.wneu.2021.08.002

104. Schreiter J, Schott D, Schwenderling L, Hansen C, Heinrich F, Joeres F. AR-supported supervision of conditional autonomous robots: considerations for pedicle screw placement in the future. *J Imaging*. 2022;8(10):255. doi:10.3390/jimaging8100255

Funding: No funding was received for this study.

Disclosures: The authors report no disclosures or conflicts of interest.

Corresponding Author: Weerasak Singhatanadgige, 1873 Rama IV Rd, Pathumwan, Bangkok, Thailand 10330; dr.weerasaks@gmail.com

This manuscript is generously published free of charge by ISASS, the International Society for the Advancement of Spine Surgery. Copyright © 2024 ISASS. To see more or order reprints or permissions, see <http://ijssurgery.com>.