

## Outcomes and Spinopelvic Changes After Anterior Lumbar Interbody Fusion With a Novel Interbody Fusion Device: A Retrospective Study

Ankit Hirpara, Christina Koshak, Eric Marty, Christopher Gallus and Christopher Kleck

*Int J Spine Surg* published online 30 July 2024  
<https://www.ijssurgery.com/content/early/2024/07/29/8621>

This information is current as of July 30, 2024.

---

**Email Alerts** Receive free email-alerts when new articles cite this article. Sign up at:  
<http://ijssurgery.com/alerts>

# Outcomes and Spinopelvic Changes After Anterior Lumbar Interbody Fusion With a Novel Interbody Fusion Device: A Retrospective Study

ANKIT HIRPARA, BA<sup>1</sup>; CHRISTINA KOSHAK, MD, MPH, FRCSC<sup>2</sup>; ERIC MARTY, MD<sup>2</sup>; CHRISTOPHER GALLUS, DO<sup>2</sup>; AND CHRISTOPHER KLECK, MD<sup>2</sup>

<sup>1</sup>School of Medicine, Anschutz Medical Campus, University of Colorado, Aurora, CO, USA; <sup>2</sup>Department of Orthopedic Surgery, Anschutz Medical Campus, University of Colorado, Aurora, CO, USA

## ABSTRACT

**Background:** Interbody devices in anterior lumbar interbody fusion (ALIF) are currently a focus of innovation due to their potential to improve clinical outcomes. The purpose of the present study was to analyze complications and changes in spinopelvic parameters after ALIF with the novel Medacta MectaLIF interbody fusion device.

**Methods:** Patients aged 18 to 80 years who underwent multilevel ALIF using this novel implant were identified. Demographic and surgical data were collected. Patients were divided into short- and long-fusion cohorts. A comparison of outcomes between the short- and long-fusion groups was performed using the Student *t* test for continuous variables and Fisher's exact test and the  $\chi^2$  test for categorical variables. Analysis of the pre- vs postoperative radiographic data for the entire cohort was performed using the 2-tailed Student *t* test.

**Results:** One hundred and eight patients met the inclusion criteria. No significant postoperative change was observed in L1–4 lumbar lordosis (LL). L1–S1 LL increased to a mean of  $55.1 \pm 12.8$  (a mean change of  $10.7 \pm 14.5$ ), and L4–S1 LL increased to a mean of  $38.4 \pm 8.7$  (a mean increase of  $7.5 \pm 8.2$ ), with pelvic incidence LL mismatch changing from  $8.9 \pm 15.1$  to  $1.1 \pm 13.5$  ( $n = 102$ ). Related changes in sacral slope and pelvic tilt were also observed ( $33.0 \pm 11.0$  to  $37.6 \pm 10.9$  and  $19.6 \pm 9.5$  to  $18.2 \pm 9.1$  [ $n = 103$ ], respectively). Five patients (4.6%) experienced implant subsidence, 1 (0.9%) had implant migration, and 6 (5.6%) experienced a nonunion. There was no difference in the rates of complications associated with the novel implant in the short- and long-fusion cohorts.

**Conclusion:** This novel implant achieves correction of spinopelvic parameters with minimal complications. The ability to modify the implant intraoperatively based on the patient's anatomy can help achieve maximal contact area and therefore help reduce the risk of subsidence.

**Clinical Relevance:** This modular implant can achieve correction of spinopelvic parameters with minimal medical and surgical complications.

**Level of Evidence:** 4.

Lumbar Spine

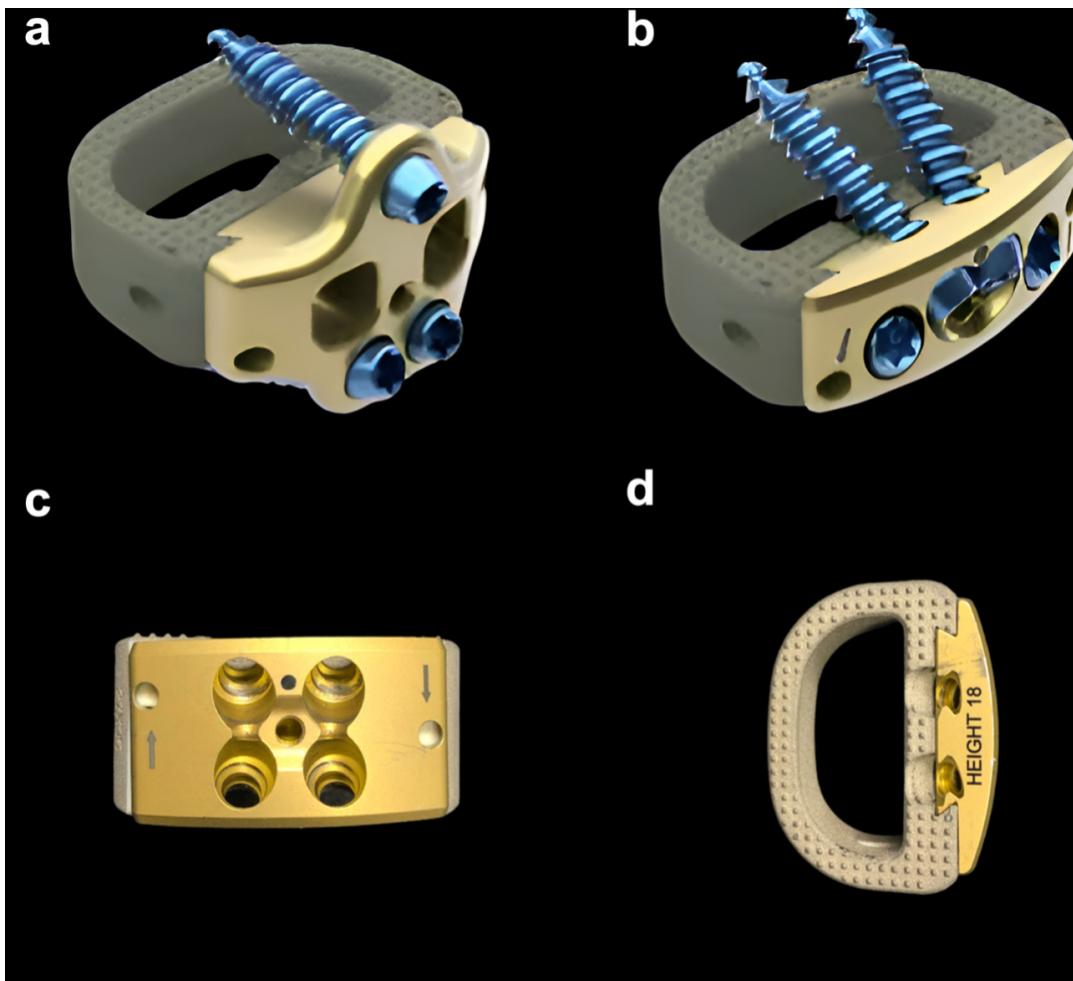
Keywords: ALIF, interbody fusion device, spinopelvic parameters, subsidence

## INTRODUCTION

Anterior lumbar interbody fusion (ALIF) is commonly performed for radiculopathy, neurogenic claudication, degenerative disc disease, pseudoarthrosis, and low-grade spondylolisthesis.<sup>1,2</sup> Interbody devices for ALIF are currently a focus of innovation.<sup>3–6</sup>

Interbody device implantation is thought to stabilize adjacent vertebral bodies, maintain proper disc height and lordosis, and improve pain.<sup>7</sup> The Medacta MectaLIF Anterior Interbody Fusion Device (Medacta International, Switzerland) combines the elements of a titanium-coated polyetheretherketone

cage with a modular titanium plate that allows the surgeon to construct multiple configurations intraoperatively to account for anatomical variations and specific pathologies (Figure 1). This includes the ability to change the number of points and placement of fixation through the plates as well as the size, angle, and height of the interbody cage. The indication-specific interbody fusion device combines divergent, convergent, and horizontal screw angles to provide additional stability, screw backout resistance, and 3-dimensional fixation. Horizontal angulation also transfers the load to the cortical bone and limits stress to the cancellous bone. Screws securely lock into the plate, eliminating the



**Figure 1.** Configuration and modularity of the novel MectaLIF implant. (A) Three-hole design that provides additional flexibility in order to accommodate the iliac artery bifurcation. (B) Flush construct with no anterior profile in order to reduce impact and irritation. (C) Anterior view of the implant showing the sterile-wrapped plate that can be disassembled in one click and replaced with another indication-specific plate. (D) Superior view of the implant demonstrating the large central bone graft area.

need for a separate antimigration system. Lastly, the device offers a large central area for the placement of graft and/or osteoinductive materials to promote fusion.

The purpose of this study was to examine complications and changes in spinopelvic parameters in patients undergoing surgery with this novel implant to determine its effectiveness and safety.

## MATERIALS AND METHODS

A retrospective analysis was conducted on patients who underwent surgery between November 2015 and October 2019. Institutional review board approval was obtained prior to study commencement. Patients were identified through a query of the University of Colorado Department of Orthopedic Surgery billing data using Current Procedural Terminology code 22585. Records were then reviewed

by A.H. and E.M. to identify patients who had undergone at least 2-level ALIF using the Medacta MectaLIF Anterior Interbody Fusion Device. Patients aged 18 to 80 years were included. Patients were not excluded based on preoperative diagnosis, presence or absence of a spinal deformity, or history of prior surgery such that the cohort would be representative of the typical patient population in which this novel implant is being used. Once all appropriate patients were identified, a third author (C.L.K.) reviewed the electronic medical records to collect demographic, surgical, and clinical data.

Preoperative and final follow-up radiographs were imported into the surgical planning program Surgimap version 2.3.2.1 (Globus Medical, Inc., Methuen, Massachusetts, USA). Two fellowship-trained spine surgeons (C.L.K. and C.A.G) used appropriate measurement tools to independently perform measurements

of the following radiographic variables: sagittal vertical axis (SVA), sacral slope (SS), pelvic tilt (PT), pelvic incidence (PI), L1-S1 lumbar lordosis (LL), L1-L4 LL, L4-S1 LL, and T4-T12 thoracic kyphosis (TK). PI-LL was calculated by manually subtracting the PI from the measured L1-S1 lordosis. A Cobb angle was used to manually measure the L1-4 lordosis. An example of these measurements is presented in Figure 2. Individual patient radiographic measurements were determined by taking the average of the 2 reviewers' measurements.

### Statistical Analysis

All data were entered into a Microsoft Excel spreadsheet. Patients were classified as having had a short fusion (localized to the lumbar spine only) or a long fusion (crossing the thoracolumbar junction). The analysis was performed for the entire cohort and for the short and long cohorts separately. A comparison of outcomes between the short- and long-fusion groups was performed using the Student *t* test for continuous variables and Fisher's exact test and the  $\chi^2$  test for categorical variables. Analysis performed on the radiographic variables was only done using patients who had both a preoperative and postoperative value for that specific measurement. Comparisons of the preoperative vs postoperative radiographic data were performed using the 2-tailed Student *t* test for paired data. This analysis was conducted using JMP Pro16.1.0 (SAS Institute, North Carolina, USA). The average improvement in LL for each level treated was calculated by dividing the mean change in L1-S1 lordosis by the mean number of implants placed per patient.

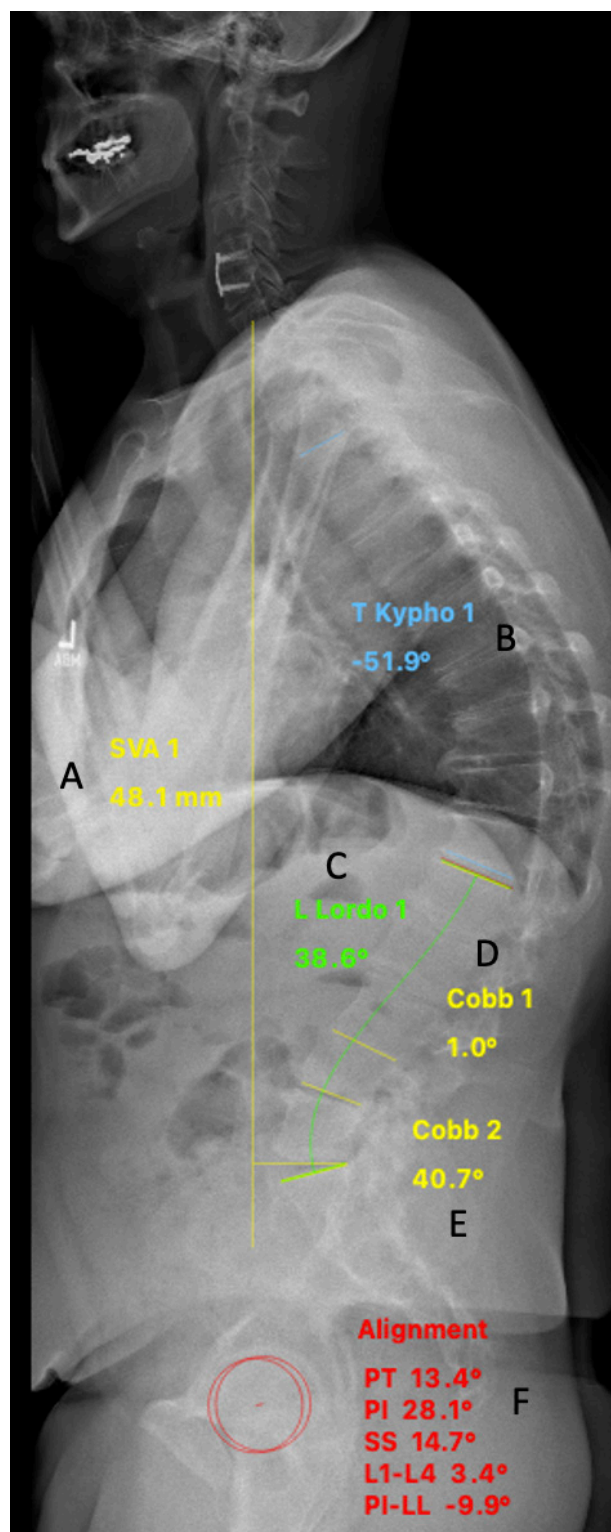
## RESULTS

### Patient Demographics

Between November 2015 and October 2019, a total of 108 patients who met study inclusion criteria underwent ALIF with placement of 2 or more implants at the University of Colorado Anschutz Medical Center. The mean age of the patients was  $59.8 \pm 28$  years, and the mean length of patient follow-up was 1.7 years (SD = 4.9, range 0.13–4.69 years). Additional demographic data can be found in Table 1.

### Surgical Data

The most common indication for surgery was degenerative disc disease ( $n = 104$ , 96.3%) with back pain ( $n = 100$ , 92.6%) (Table 2). Patients undergoing a short fusion were more likely to have a diagnosis of



**Figure 2.** Example of radiographic measurements. (A) Sagittal vertical axis (SVA) measured as the distance from the posterosuperior corner of S1 horizontally to a vertical line dropped from the center of the C7 vertebral body. (B) T4-12 kyphosis measured from the cranial endplate of T4 to the caudal endplate of T12. (C) L1-S1 lordosis measured from the superior endplate of L1 to the superior endplate of S1. (D) L1-4 lordosis measured from the cranial endplate of L1 to the caudal endplate of L4. (E) L4-S1 lordosis measured from the cranial endplate of L4 to the cranial endplate of S1. (F) PI-LL tool using the femoral heads and the cranial endplates of L1 and S1 to calculate pelvic tilt (PT), pelvic incidence (PI), and sacral slope (SS).

**Table 1.** Patient demographic data.

Variable	All	Short Fusion	Long Fusion	P
N (%)	108	68 (63.0)	40 (37.0)	N/A
Age, y				
Mean (SD)	59.8 (11.0)	58.1 (11.9)	62.9 (8.5)	0.027
Range	28–81	28–81	38–76	N/A
Sex, n (%)				
Men	51 (47.2)	34 (50.0)	17 (42.5)	0.451 <sup>a</sup>
Women	57 (52.8)	34 (50.0)	23 (57.5)	
Follow-up				
Days				
Mean (SD)	623.2 (353.9)	628.3 (366.8)	614.5 (335.2)	0.846
Range	48–1711	48–1711	85–1556	N/A
Years				
Mean (SD)	1.71 (0.97)	1.72 (1.0)	1.68 (0.92)	0.846
Range	0.13–4.69	0.13–4.69	0.23–4.26	N/A
Body mass index, kg/m <sup>2</sup>				
Mean (SD)	27.6 (4.87)	27.8 (4.6)	27.2 (5.3)	0.552
Range	17.4–40.0	17.7–40.0	17.5–38.1	N/A
Race, n (%)				
White/Caucasian	92 (85.2)	59 (86.8)	33 (82.5)	0.547 <sup>a</sup>
Black/African American	7 (6.5)	4 (5.9)	3 (7.5)	0.708
Native Hawaiian/Pacific Islander	2 (1.9)	0 (0.0)	2 (5.0)	0.135
Other/Asian	2 (1.9)	2 (2.9)	0 (0.0)	0.529
Other	5 (4.6)	3 (4.4)	2 (5.0)	>0.99
Ethnicity, n (%)				
Non-Hispanic/Latino(a)	102 (94.4)	64 (94.1)	37 (92.5)	0.708
Hispanic/Latino(a)	5 (4.6)	4 (5.9)	2 (5.0)	>0.99
Other	1 (0.9)	0 (0.0)	1 (2.5)	0.37
Smoking/nicotine, n (%)				
Current	9 (8.3)	5 (7.4)	4 (10.0)	0.284 <sup>a</sup>
Former	52 (48.1)	34 (50.0)	18 (45.0)	0.616 <sup>a</sup>
Never	47 (43.5)	29 (42.7)	18 (45.0)	0.812 <sup>a</sup>
Diabetes, n (%)				
Yes	11 (10.2)	8 (11.8)	3 (7.5)	0.479
No	97 (89.8)	60 (88.2)	37 (92.5)	
Osteoporosis, n (%)				
Yes	16 (12.0)	7 (10.3)	9 (22.5)	0.085
No	92 (88.0)	61 (89.7)	31 (77.5)	

Abbreviation: N/A, not applicable.

<sup>a</sup>Fisher's exact test was performed for comparison; all other comparisons of proportions were performed with the  $\chi^2$  test

spondylolisthesis (42.7% vs 22.5%,  $P = 0.034$ ), while those undergoing a long fusion were more likely to have a spinal deformity such as scoliosis (72.5% vs 17.7%,  $P < 0.001$ ).

In total, 278 implants were placed, with 164 implanted in the short cohort and 114 in the long cohort for a mean number per patient of 2.4 in the short and 2.9 in the long cohorts ( $P < 0.001$ ). L4-5 (97.2% of patients) and L5-S1 (95.4% of patients) were the most common levels at which implants were placed. Patients in the long cohort were significantly more likely to have had this novel implant placed at L3-4 (77.5% vs 41.2%,  $P < 0.001$ ).

In addition to the anterior fusion, 100% of the long and 89.7% of the short cohorts underwent a posterior procedure with instrumentation to augment the ALIF ( $P = 0.036$ ; Table 2). The mean number of levels fused posteriorly in the entire cohort was 5.1 (SD = 4.0). Estimated blood loss was significantly higher in the patients who had surgery across the thoracolumbar junction

(1573.8  $\pm$  1243.1 vs 432.1  $\pm$  535.3 mL,  $P < 0.001$ ). Length of stay was also significantly different between the short and long groups (4.9  $\pm$  2.5 vs 8.5  $\pm$  4.0 days,  $P < 0.001$ ).

### Complications

Acute blood loss anemia was the most common complication after surgery (77.8%). However, patients undergoing long fusion were significantly more likely to experience several medical complications, including acute blood loss anemia (95.0% vs 67.6%,  $P = 0.001$ ), ileus (32.5% vs 8.8%,  $P < 0.001$ ), and respiratory complications (37.5% vs 4.4%,  $P < 0.001$ ; Table 3).

The most common surgical complications were wound problems (infection or other wound problems,  $n = 5$ , 4.5% and  $n = 13$ , 12.0%; respectively) and adjacent segment disease ( $n = 21$ , 19.4%). Wound problems were much more likely to occur in patients undergoing a long fusion (10.0% vs 1.5%,  $P = 0.01$  for infection

**Table 2.** Patient diagnosis and surgical data.

Variable	All	Short Fusion	Long Fusion	P
Preoperative diagnosis, <i>n</i> (%)				
Degenerative disc disease	104 (96.3)	66 (97.1)	39 (97.5)	0.651 <sup>a</sup>
Stenosis	94 (87.0)	61 (89.7)	33 (82.5)	0.282
Spondylolisthesis	38 (35.2)	29 (42.7)	9 (22.5)	0.034
Radiculopathy	92 (85.2)	61 (89.7)	31 (77.5)	0.084
Neurogenic claudication	26 (24.1)	13 (19.1)	13 (32.5)	0.116
Back pain	100 (92.6)	60 (88.2)	40 (100.0)	0.024
Kyphosis	22 (20.4)	6 (8.8)	16 (40.0)	<0.001
Scoliosis	41 (38.0)	12 (17.7)	29 (72.5)	<0.001
Sagittal imbalance	24 (22.2)	8 (11.8)	16 (40.0)	0.001
Pseudarthrosis	8 (7.4)	7 (10.3)	1 (2.5)	0.135
Infection	1 (0.9)	0 (0.00)	1 (2.5)	0.37 <sup>a</sup>
Fracture	1 (0.9)	1 (0.9)	0 (0.0)	1.0
Novel implant device data				
Total number in cohort	278	164	114	
No. per patient, <i>n</i> (%)				
1-level	2 (1.9)	1 (1.5)	1 (2.5)	>0.99 <sup>a</sup>
2-level	50 (46.3)	42 (61.8)	8 (20.0)	<0.001
3-level	48 (44.4)	21 (30.9)	27 (67.5)	<0.001
4-level	8 (7.4)	4 (5.9)	4 (10.0)	0.465 <sup>a</sup>
Mean/patient (SD)	2.57 (0.66)	2.41 (0.63)	2.85 (0.62)	<0.001
Range	1–4	1–4	1–4	N/A
Levels, <i>n</i> (%)				
L2–L3	8 (7.4)	5 (7.4)	3 (7.5)	0.978
L3–L4	59 (54.6)	28 (41.2)	31 (77.5)	<0.001
L4–L5	105 (97.2)	65 (95.6)	40 (100)	0.294 <sup>a</sup>
L5–S1	104 (95.4)	65 (95.6)	39 (97.5)	>0.99 <sup>a</sup>
L5–L6/L6–S1	2 (1.9)	1 (1.5)	1 (2.5)	>0.99 <sup>a</sup>
Posterior fusion, <i>n</i> (%)				
Yes	101 (93.5)	61 (89.7)	40 (100.0)	0.036
No	7 (6.5)	7 (10.3)	0 (0.0)	0.045 <sup>a</sup>
No. of levels				
Mean (SD)	5.1 (4.0)	2.4 (1.1)	9.7 (2.7)	<0.001
Range	0–15	0–5	8–15	N/A
Estimated blood loss, mL				
Mean (SD)	858.9 (1027.1)	432.1 (535.3)	1573.8 (1243.1)	<0.001
Range	50–6150	50–3050	250–6150	N/A
Length of stay, d				
Mean (SD)	6.2 (3.6)	4.9 (2.5)	8.5 (4.0)	<0.001
Range	1–20	1–13	4–20	N/A

Abbreviation: N/A, not applicable.

<sup>a</sup>Fisher's exact test was performed for comparison; all other comparisons of proportions were performed with the  $\chi^2$  test.

and 22.5% vs 5.9%,  $P = 0.015$  for other wound complications). Adjacent segment degeneration was more likely to occur in patients having a short fusion (20.6% vs 17.5%,  $P = 0.022$ ), but there were higher rates of proximal junctional issues and rod fracture in patients

undergoing a long fusion (15.0% vs 2.9%,  $P = 0.05$  and 2.8% vs 0.0%,  $P = 0.07$ , respectively; Table 4)

Five patients experienced implant subsidence (1.8% of all implants), one had implant migration (0.4% of all implants), and 6 experienced a nonunion (2.2% of

**Table 3.** Summary of medical outcomes.

Medical Outcome, <i>n</i> (%)	All	Short Fusion	Long Fusion	P
Acute blood loss anemia	84 (77.8)	46 (67.6)	38 (95.0)	0.001
Urinary retention	11 (10.2)	6 (8.8)	5 (12.5)	0.542
Urinary tract infection/urosepsis	11 (10.2)	4 (5.9)	7 (17.5)	0.054
Acute kidney injury	6 (5.6)	3 (4.4)	3 (7.5)	0.668 <sup>a</sup>
Altered mental status	8 (7.4)	6 (8.8)	2 (5.0)	0.522
Hypotension	11 (10.2)	4 (5.9)	7 (17.5)	0.054
Cardiac arrhythmia	7 (6.5)	2 (2.9)	5 (20.0)	0.051
Ileus	19 (17.6)	6 (8.8)	13 (32.5)	<0.001
Clostridioides difficile	2 (1.9)	2 (2.9)	0 (0.0)	0.53 <sup>a</sup>
Respiratory complication	18 (16.7)	3 (4.4)	15 (37.5)	<0.001
Deep vein thrombosis/pulmonary embolism	3 (2.8)	1 (1.5)	2 (5.0)	0.554 <sup>a</sup>

<sup>a</sup>Fisher's exact test was performed for comparison; all other comparisons of proportions were performed with the  $\chi^2$  test.

**Table 4.** Summary of surgical outcomes.

Surgical Outcome, <i>n</i> (%)	All	Short Fusion	Long Fusion	<i>P</i>
Iliac vein injury	3 (2.8)	2 (2.9)	1 (2.5)	1.0 <sup>a</sup>
Dural tear	5 (4.6)	1 (1.5)	4 (10.0)	0.062 <sup>a</sup>
Posterior implant problem	2 (1.9)	2 (2.9)	0 (0.0)	0.53 <sup>a</sup>
Estimated blood loss >2500 mL	8 (7.4)	1 (1.5)	7 (17.5)	0.004 <sup>a</sup>
Neurological injury	1 (0.9)	1 (1.5)	0 (0.0)	1.0 <sup>a</sup>
Bone morphogenetic protein neuritis	4 (3.7)	4 (5.9)	0 (0.0)	0.294 <sup>a</sup>
Wound complications	13 (12.0)	4 (5.9)	9 (22.5)	0.015 <sup>a</sup>
Wound infection	5 (4.6)	1 (1.5)	4 (10.0)	0.01
Symptomatic hardware	6 (5.6)	3 (4.4)	3 (7.5)	0.668 <sup>a</sup>
Abdominal hernia	3 (2.8)	2 (2.9)	1 (2.5)	1.0 <sup>a</sup>
Sacroiliac joint dysfunction	2 (1.9)	2 (2.9)	0 (0.0)	0.53 <sup>a</sup>
Persistent radiculopathy	1 (0.9)	1 (1.5)	0 (0.0)	1.0 <sup>a</sup>
PJK/PJF/PJ	8 (7.4)	2 (2.9)	6 (15.0)	0.05 <sup>a</sup>
Adjacent segment degeneration	21 (19.4)	14 (20.6)	7 (17.5)	0.022
Rod fracture	3 (2.8)	0 (0.0)	3 (2.8)	0.07

Abbreviation: PJK/PJF/PJ, proximal junctional kyphosis/proximal junctional failure/proximal junctional fracture.

<sup>a</sup>Fisher’s exact test was performed for comparison; all other comparisons of proportions were performed with the  $\chi^2$  test.

implants). There was no difference in the rates of complications associated with the implant in the short- and long-fusion cohorts (Table 5).

### Readmissions and Reoperations

One-third (*n* = 36) of all patients included in this study required readmission to the hospital at a mean time of 1.6 years (SD = 1.46, range 0.01–4.8; Table 6) with no difference between the short- and long-fusion groups. The mean time to reoperation was 1.56 years (SD = 1.46, range 0.01–4.81) with no difference between the short- and long-fusion groups. The most common indication for reoperation was adjacent segment degeneration (*n* = 9, 8.3%).

Only 1 patient (0.9%) underwent surgical revision of a single implant due to implant migration leading

**Table 5.** Complications associated with the novel implant device.

Complications, <i>n</i> (%)	All	Short Fusion	Long Fusion	<i>P</i>
Subsidence				
Patients	5 (4.6)	4 (5.9)	1 (2.5)	0.649 <sup>a</sup>
All implants	5 (1.8)	4 (2.4)	1 (0.9)	0.649 <sup>a</sup>
Migration				
Patients	1 (0.9)	1 (1.5)	0 (0.0)	>0.99 <sup>a</sup>
All implants	1 (0.4)	1 (0.6)	0 (0.0)	>0.99 <sup>a</sup>
Nonunion				
Patients	6 (5.6)	2 (2.9)	4 (10.0)	0.191 <sup>a</sup>
All implants	6 (2.2)	2 (1.2)	4 (3.5)	0.191 <sup>a</sup>
Surgical revision				
Patients	1 (0.9)	1 (1.5)	0 (0.0)	>0.99 <sup>a</sup>
All implants	1 (0.4)	1 (0.6)	0 (0.0)	>0.99 <sup>a</sup>

<sup>a</sup>Fisher’s exact test was performed for comparison; all other comparisons of proportions were performed with the  $\chi^2$  test.

to recurrent radiculopathy (Figure 3). This occurred in a patient with a body mass index of 33.2 who underwent a 2-level ALIF and posterior instrumented fusion. Despite the apparent stability of the implant, revision of the implant to achieve complete superior endplate contact was indicated given the patient’s body habitus and preoperative SS of 36.4. One of the 5 patients (20.0%) with implant subsidence required reoperation for recurrent radiculopathy (Figure 4). Finally, 2 of the 6 patients diagnosed with a nonunion of 1 of their interbody implants underwent a reoperation for unrelated trauma during which the interbody implants were not revised.

### Radiographic Data

Only 42 patients (38.9%) had a complete set of preoperative and postoperative radiographic data (Table 7). The main reason for missing radiographic data was the failure to perform postoperative full-length spine radiographs preventing the measurement of T4-12 TK and SVA. A second common reason was the inability to properly visualize the femoral heads. For the 42 patients for whom TK data were available, the mean preoperative and postoperative T4-12 TK were 31.7 (SD = 14.7) and 55.1 (SD = 12.8), respectively. The mean change in TK of 13.6 was statistically significant (*P* < 0.001). SVA data were available for 44 patients (40.7%) for whom the mean preoperative SVA was 48.2 ± 56.8 mm and the mean postoperative SVA was 24.5 ± 55.3 mm. This was also a statistically significant change, with improvement of 23.8 mm (*P* < 0.001). The increase in TK aligns with the literature, which shows that TK can change after spinal deformity surgery with fusions stopping in the lumbar or lower thoracic spine.<sup>8,9</sup>

The mean preoperative L1-S1 LL was 44.4 ± 16.2, with the L1-4 LL measuring 19.7 ± 12.0 and the L4-S1 LL measuring 30.9 ± 10.3. There was no significant postoperative change in L1-4 LL (*P* = 0.1); however, the L1-S1 LL increased to a mean of 55.1 ± 12.8 (a mean change of 10.7 ± 14.5, *P* < 0.001), and the L4-S1 LL increased to a mean of 38.4 ± 8.7 (a mean increase of 7.5 ± 8.2, *P* < 0.001). In the 107 patients for whom data were available, this represented an increase in LL of 4.2 per implant placed. As a result of the mean increase in LL, a significant improvement in PI-LL mismatch was observed postoperatively with the mean PI-LL changing from 8.9 ± 15.1 to 1.1 ± 13.5 (*n* = 102, *P* < 0.001). The increase in angulation focused at L4-S1 is expected given that 97.2% of patients had the device implanted at L4-5 and 95.4% at L5-S1. Moreover, these segments

**Table 6.** Summary of readmissions and reoperations.

Outcome Measure	All	Short Fusion	Long Fusion	P
Readmission, n (%)				
Yes	36 (33.3)	19 (27.9)	17 (42.5)	0.12
No	72 (66.7)	49 (72.1)	23 (57.5)	
Time to readmission				
Days				
Mean (SD)	600.1 (531.4)	683.6 (651.3)	406.1 (316.2)	0.12
Range	2–1755	2–1755	9–1029	N/A
Years				
Mean (SD)	1.64 (1.46)	1.87 (1.78)	1.11 (0.87)	0.12
Range	0.01–4.81	0.01–4.81	0.02–2.82	N/A
Reoperation, n (%)				
Yes	33 (30.6)	18 (26.5)	15 (37.5)	0.23
No	75 (69.4)	50 (73.5)	25 (62.5)	
Time to reoperation				
Days				
Mean (SD)	570.9 (532.1)	665.6 (661.1)	457.3 (301.7)	0.162
Range	2–1755	2–1755	51–1029	N/A
Years				
Mean (SD)	1.56 (1.46)	1.82 (1.81)	1.25 (0.83)	0.162
Range	0.01–4.81	0.01–4.81	0.14–2.82	N/A
Reason for Reoperation, n (%), % of all reoperations				
Adjacent segment degeneration	9 (8.3), 27.3	7 (10.3), 38.9	2 (5.0), 13.3	0.48
Proximal junctional kyphosis/proximal junctional failure/proximal junctional fracture	4 (3.78), 12.1	0 (0.0), 0.0	4 (10.0), 26.7	0.017
Painful iliac bolts	5 (4.6), 15.2	3 (4.4), 16.7	2 (5.0), 13.3	1.0
Wound complication	6 (5.6), 18.2	2 (2.9), 11.1	4 (10.0), 26.7	0.191
Acute implant problem	3 (2.8), 9.1	3 (4.4), 16.7	0 (0.0), 0.0	0.294
Fracture/spinopelvic dissociation	2 (1.9), 6.1	0 (0.0), 0.0	2 (5.0), 13.3	0.135
Recurrent stenosis/radiculopathy	4 (3.7), 12.1	3 (4.4), 16.7	1 (2.5), 6.7	1.0
Nonunion/rod failure	2 (1.9), 6.1	0 (0.0), 0.0	2 (5.0), 13.3	0.135
Sacroiliac joint dysfunction	2 (1.9), 6.1	2 (2.9), 11.1	0 (0.0), 0.0	0.529
Device migration	1 (0.9), 3.0	1 (1.5), 5.6	0 (0.0), 0.0	1.0
Device subsidence	1 (0.9), 3.0	1 (1.5), 5.6	0 (0.0), 0.0	1.0

Abbreviation: N/A, not applicable.

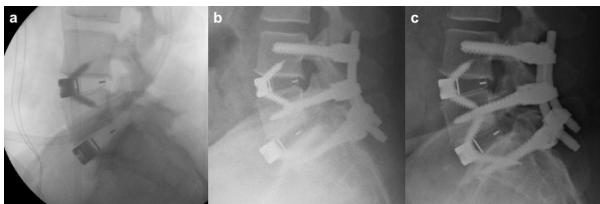
naturally experience greater motion with greater angulation.

## DISCUSSION

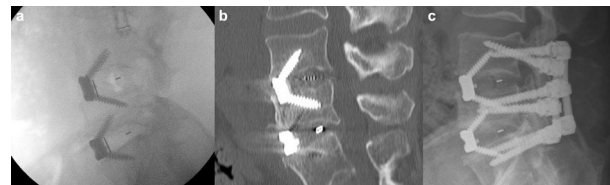The purpose of this retrospective cohort study was to evaluate the effectiveness and safety of this novel implant in a representative population of adult patients undergoing ALIF at 2 or more levels. Overall, the

implant was able to achieve significant changes with improvements in key sagittal parameters.

A systematic review of 27 studies examining ALIF using a variety of implants reported aggregate statistics for several sagittal parameters.<sup>10</sup> Seven reported a postoperative PI with a mean value of  $55.5^\circ \pm 1.8^\circ$ , compared with  $55.8^\circ$  with this implant. PT was reported in 9 studies with a mean improvement of  $4.3^\circ \pm 5.2^\circ$ , compared with  $1.4^\circ$  ( $P = 0.02$ ) in this study. Ten studies



**Figure 3.** Single patient requiring revision of the implant. (A) Intraoperative radiograph after index anterior procedure showing implant fixation with S1 screws and good opposition of the implant on L5 with a residual spondyloolisthesis. (B) After placement of posterior instrumentation and anatomic reduction of L5 on S1, the implant appears to have migrated but is in fact stable in position on S1 with loss of contact with L5. (C) Repeat postoperative radiograph after L5-S1 implant revision with the addition of L5 fixation. Anatomic reduction of L5 on S1 with full implant contact with both vertebrae has been achieved.



**Figure 4.** Patient requiring a reoperation with the placement of posterior instrumentation for recurrence of radiculopathy after implant subsidence. (A) Intraoperative radiograph showing good position of L4-5 and L5-S1 implants. (B) Computed tomography scan obtained after recurrence of L4 radiculopathy showing subsidence of L4-5 implant into the superior endplate of L4. (C) Postoperative radiograph showing placement of posterior instrumentation for stabilization. The anterior lumbar interbody fusion implant was not revised.



**Table 7.** Summary of radiographic data.

Variable	N	Mean (SD)			P
		Preoperative	Postoperative	Preoperative to Postoperative	
LL (°)					
L1–S1	107	44.4 (16.2)	55.1 (12.8)	10.7 (14.5)	<0.001
L1–L4	107	19.7 (12.0)	21.4 (10.8)	1.8 (10.8)	0.1
L4–S1	106	30.9 (10.3)	38.4 (8.7)	7.5 (8.2)	<0.001
T4–T12 Thoracic kyphosis (°)	42	31.7 (14.7)	45.4 (12.4)	13.6 (12.5)	<0.001
Spinopelvic parameters (°)					
Sacral slope	103	33.0 (11.0)	37.6 (10.9)	−4.7 (6.9)	<0.001
Pelvic tilt	103	19.6 (9.5)	18.2 (9.1)	1.4 (5.7)	0.02
PI	103	52.5 (12.3)	55.8 (12.9)	−3.3 (6.3)	<0.001
PI-LL	102	8.9 (15.1)	1.1 (13.5)	7.8 (14.2)	<0.001
Sagittal vertical axis, mm	44	48.2 (56.8)	24.5 (55.3)	23.8 (53.4)	0.005

Abbreviations: LL, lumbar lordosis; PI, pelvic incidence.

reported SS with a mean improvement of  $3.9^\circ \pm 4.5^\circ$ . Interestingly, our study showed a decline in SS by  $-4.7^\circ$ .

Of the 25 studies in the systematic review that reported change in LL, the mean improvement was  $10.6^\circ \pm 12.5^\circ$ .<sup>10</sup> However, the highest degrees of correction were reported in 2 studies specifically including patients with flatback deformity.<sup>11,12</sup> Without these studies, the average improvement in LL in the systematic review would be  $7.9^\circ$ . Our study showed a similar mean improvement in L1-S1 LL of  $10.7 \pm 14.5$ .

The improvement in global lordosis can be attributed to the significant change in L4-S1 LL.<sup>13</sup> In contrast, there was no significant change in L1-L4 LL. This is expected given that a vast majority of patients in this study received the implant at L4-L5 and L5-S1. LL also has an uneven distribution that increases in the lower segments and is characterized by the lordosis distribution index (LDI), which is the ratio of L4-S LL to global lordosis.<sup>14</sup> Normal LDI is between 50% and 80%.<sup>13</sup> Values outside this range are associated with higher rates of adjacent segment disease and revision surgery after lumbar fusion.<sup>14,15</sup> The average postoperative LDI in this study was 69.7%, which is within the normal range. A significant increase in L1-L4 LL would potentially increase the risk of hypolordotic maldistribution. As such, the minimal change in L1-L4 LL relative to L4-S1 LL is expected and preferred. Moreover, the overall rate of adjacent segment disease in this study was 19.4%, or 21 patients. Of these patients, 9 patients required reoperation. This aligns with the current literature on rates of adjacent segment disease following lumbar fusion, which range from 5.0% to 49%.<sup>16–20</sup>

The results of this study also demonstrate that this novel implant is associated with low rates of implant-related complications. Radiographic subsidence was observed in 4.6% (5/108) of the patients experienced, with a single patient (0.9%) requiring revision surgery. In a systematic review of 6 studies

evaluating radiographic subsidence following ALIF with a self-anchored stand-alone polyetheretherketone cage (ROI-A Oblique; LDR Medical), the lowest rate of radiographic subsidence reported was 7.1% at 2-year follow-up.<sup>21,22</sup> Other studies have reported higher rates ranging from 10.2% to 23.1%.<sup>23–27</sup> The aforementioned studies did not include patients who had simultaneous posterior instrumentation, unlike our study. However, Hsieh et al studied outcomes after ALIF in 32 patients, 26 of which received simultaneous posterior instrumentation. They reported a subsidence rate of 21.7%.<sup>28</sup> Kadam et al studied patients who underwent ALIF with posterior revision in 20 patients, 15% of which experienced subsidence. Kim et al reported that 9% of patients (3/35) who underwent single-level ALIF with posterior fixation experienced subsidence.<sup>29</sup> Several additional studies that either included or focused solely on patients undergoing ALIF with posterior instrumentation reported subsidence rates ranging from 9.8% to 29.2%.<sup>30–34</sup> The subsidence rates reported in this study were relatively lower. This may be attributed to the implant's modular design,<sup>30</sup> which may help increase the device's contact area and resistance to subsidence.

The most reported complication following ALIF in the systematic review by Formica et al was proximal junctional kyphosis at a rate of 5.1%.<sup>10</sup> Our study reported a rate of 7.4% for proximal junctional kyphosis, proximal junctional fracture, and proximal junctional failure combined. However, the combined rate for short fusions was only 2.9% compared with 15% for long fusions ( $P = 0.022$ ). The overall higher rate observed in our study is, therefore, likely due to the inclusion of patients undergoing long fusions.

Our study also analyzed medical complications after surgery. The current literature on lumbar fusion lacks consistent reporting of medical complications, making it difficult to compare the outcomes of our study.<sup>29,31,35–37</sup> For example, Kim et al studied complications following

single-level ALIF and only reported rates of subsidence, nonunion, vessel injury, hematoma collection, hydro-nephrosis, and retrograde ejaculation. Malham et al reported various complications following only single-level ALIF.<sup>37</sup> Of the complications that they reported, our short-fusion cohort, which had an average of 2.41 implants placed per patient, demonstrated similar rates. Systematic reporting of complications is, therefore, an area of improvement in the current literature.

Several studies have also explored risk factors for poor outcomes following ALIF. Smoking status, body mass index, osteoporosis, and diabetes have been shown to be associated with inferior outcomes after lumbar surgery.<sup>38–42</sup> Again, there is a lack of consistent and detailed reporting of comorbidities in the literature. However, our patient cohort had a higher mean body mass index than the cohort studied by Malham et al (27.6 vs 25.7).<sup>37</sup> Our cohort also had a higher rate of osteoporosis compared with the Kim et al study (12.0% vs 7.3%). These variables may be impacting outcomes in our study.

It is also important to note that the vast majority of our cohort underwent posterior instrumented fusion. The combined anterior-posterior approach has been associated with more complications.<sup>43</sup> Posterior instrumented fusion could have also impacted the postoperative sagittal parameters. As such, the correction in postoperative sagittal parameters cannot be attributed to this novel implant alone. However, the literature has shown that combined anterior and posterior fusion does not lead to statistically significant improvement in spinopelvic parameters compared with anterior fusion alone.<sup>10,44</sup>

A strength of this study is that the patient cohort is representative of the typical patient population in which a stand-alone ALIF implant is being used. Moreover, all radiographic measurements were performed by 2 fellowship-trained spine surgeons (CLK and CAG), and the final reported value was the average of 2 measurements.

The primary limitation was the lack of a standard postoperative imaging protocol. Furthermore, as it was not standard for patients to undergo flexion-extension radiographs or a postoperative computed tomography scan at a predetermined follow-up timepoint, it was impossible to evaluate for radiographic fusion. However, radiographic fusion does not definitively correlate to patient outcome,<sup>45–50</sup> and only 1 of the 6 patients diagnosed with a nonunion required a reoperation as a direct result of the fusion failure. Four of the patients were asymptomatic and did not undergo repeat

surgery, and 1 patient was found to have an L5-S1 nonunion at the time of revision surgery for an unrelated fracture. Since the need for revision surgery due to a nonunion is more clinically relevant than the rate of asymptomatic radiographic nonunion, we do not feel that this limitation negatively impacts the applicability of these study results.

The lack of a standard data collection form for complication-related data also introduces the risk of underreporting of complications.

Another limitation is that a majority of patients received the implant at L4-L5 and L5-S1. Only 7.4% of implants were placed at L2-L3. However, this may also be representative of the general patient population. For example, the review by Formica et al showed that 88.8% of surgeries in 19 studies were performed at the L4-S1 segments.<sup>10</sup>

Lastly, this study does not include patient-reported outcomes. Without such data, it is difficult to understand how the correction of sagittal parameters affects patient pain and function.

## CONCLUSION

This retrospective cohort study of 108 patients has demonstrated that the use of the novel MectaLIF implant appears to result in the correction of sagittal parameters, including L1-S1 LL, L4-S1 LL, PI-LL mismatch, SS, PI, PT, and SVA, in those who have undergone at least 2-level ALIF. Minimal rates of subsidence, implant migration, nonunion, and revision were noted, with no difference between the long- and short-fusion cohorts. Patients in the long-fusion cohort had higher rates of perioperative and long-term complications compared with those in the short-fusion cohort.

## REFERENCES

1. de Kunder SL, Rijkers K, Caelers IJM, de Bie RA, Koehler PJ, van Santbrink H. Lumbar interbody fusion: a historical overview and a future perspective. *Spine*. 2018;43(16):1161–1168. doi:10.1097/BRS.0000000000002534
2. Wang H, Chen W, Jiang J, Lu F, Ma X, Xia X. Analysis of the correlative factors in the selection of interbody fusion cage height in transforaminal lumbar interbody fusion. *BMC Musculoskeletal Disord*. 2016;17(1):9. doi:10.1186/s12891-016-0866-5
3. Brantigan JW, Steffee AD, Lewis ML, Quinn LM, Perse-naire JM. Lumbar interbody fusion using the brantigan I/F cage for posterior lumbar interbody fusion and the variable pedicle screw placement system: two-year results from a food and drug administration investigational device exemption clinical trial. *Spine*. 2000;25(11):1437–1446. doi:10.1097/00007632-200006010-00017
4. Ani N, Keppler L, Biscup RS, Steffee AD. Reduction of high-grade slips (grades III-V) with VSP instrumentation:report

- of a series of 41 cases. *Spine*. 1991;16(6 Suppl):S302–10. doi:10.1097/00007632-199106001-00025
5. Steffee AD, Biscup RS, Sitkowski DJ. Segmental spine plates with pedicle screw fixation: a new internal fixation device for disorders of the lumbar and thoracolumbar spine. *Clin Orthop Relat Res*. 1986;(203):45–53.
  6. Steffee AD, Sitkowski DJ. Posterior lumbar interbody fusion and plates. *Clin Orthop Relat Res*. 1988;227:99–102.
  7. Phan K, Mobbs RJ. Evolution of design of interbody cages for anterior lumbar interbody fusion. *Orthop Surg*. 2016;8(3):270–277. doi:10.1111/os.12259
  8. Yasuda T, Hasegawa T, Yamato Y, et al. Postoperative change of thoracic kyphosis after corrective surgery for adult spinal deformity. *Spine Surg Relat Res*. 2018;2(4):283–289. doi:10.22603/ssrr.2017-0081
  9. Jang JS, Lee SH, Min JH, Maeng DH. Influence of lumbar lordosis restoration on thoracic curve and sagittal position in lumbar degenerative kyphosis patients. *Spine*. 2009;34(3):280–284. doi:10.1097/BRS.0b013e318191e792
  10. Formica M, Quarto E, Zanirato A, et al. ALIF in the correction of spinal sagittal misalignment: a systematic review of literature. *Eur Spine J*. 2021;30(1):50–62. doi:10.1007/s00586-020-06598-y
  11. Choi MK, Kim SM, Jo DJ. Anterior lumbar interbody fusions combined with posterior column osteotomy in patients who had sagittal imbalance associated with degenerative lumbar flat-back deformity: a retrospective case series. *Neurosurg Rev*. 2020;43(4):1117–1125. doi:10.1007/s10143-019-01129-w
  12. Jang J-S, Lee S-H, Min J-H, Maeng DH. Changes in sagittal alignment after restoration of lower lumbar lordosis in patients with degenerative flat back syndrome. *SPI*. 2007;7(4):387–392. doi:10.3171/SPI-07/10/387
  13. Bari TJ, Heegaard M, Bech-Azeddine R, Dahl B, Gehrchen M. Lordosis distribution index in short - segment lumbar spine fusion - can ideal lordosis reduce revision surgery and iatrogenic deformity? *Neurospine*. 2021;18(3):543–553. doi:10.14245/ns.2040744.372
  14. Yilgor C, Sogunmez N, Yavuz Y, et al. Relative lumbar lordosis and lordosis distribution index: individualized pelvic incidence-based proportional parameters that quantify lumbar lordosis more precisely than the concept of pelvic incidence minus lumbar lordosis. *Neurosurg Focus*. 2017;43(6):E5. doi:10.3171/2017.8.FOCUS17498
  15. Zheng G, Wang C, Wang T, et al. Relationship between post-operative lordosis distribution index and adjacent segment disease following L4-S1 posterior lumbar interbody fusion. *J Orthop Surg Res*. 2020;15(1):129. doi:10.1186/s13018-020-01630-9
  16. Bagheri SR, Alimohammadi E, Zamani Froushani A, Abdi A. Adjacent segment disease after posterior lumbar instrumentation surgery for degenerative disease: incidence and risk factors. *J Orthop Surg*. 2019;27(2):2309499019842378. doi:10.1177/2309499019842378
  17. Zhong ZM, Deviren V, Tay B, Burch S, Berven SH. Adjacent segment disease after Instrumented fusion for adult lumbar spondylolisthesis: incidence and risk factors. *Clin Neurol Neurosurg*. 2017;156:S0303-8467(17)30055-0:29–34. doi:10.1016/j.clineuro.2017.02.020
  18. Hilibrand AS, Robbins M. Adjacent segment degeneration and adjacent segment disease: the consequences of spinal fusion? *Spine J*. 2004;4(6 Suppl):190S–194S. doi:10.1016/j.spinee.2004.07.007
  19. Okuda S, Nagamoto Y, Matsumoto T, Sugiura T, Takahashi Y, Iwasaki M. Adjacent segment disease after single segment posterior lumbar interbody fusion for degenerative spondylolisthesis: minimum 10 years follow-up. *Spine*. 2018;43(23):E1384–E1388. doi:10.1097/BRS.0000000000002710
  20. Park P, Garton HJ, Gala VC, Hoff JT, McGillicuddy JE. Adjacent segment disease after lumbar or lumbosacral fusion: review of the literature. *Spine*. 2004;29(17):1938–1944. doi:10.1097/01.brs.0000137069.88904.03
  21. Parisien A, Wai EK, ElSayed MSA, Frei H. Subsidence of spinal fusion cages: a systematic review. *Int J Spine Surg*. 2022;16(6):1103–1118. doi:10.14444/8363
  22. Kuang L, Wang B, Lü G. Transforaminal lumbar interbody fusion versus mini-open anterior lumbar interbody fusion with oblique self-anchored stand-alone cages for the treatment of lumbar disc herniation: a retrospective study with 2-year follow-up. *Spine*. 2017;42(21):E1259–E1265. doi:10.1097/BRS.0000000000002145
  23. Behrbalk E, Uri O, Parks RM, Musson R, Soh RCC, Boszczyk BM. Fusion and subsidence rate of stand alone anterior lumbar interbody fusion using PEEK cage with recombinant human bone morphogenetic protein-2. *Eur Spine J*. 2013;22(12):2869–2875. doi:10.1007/s00586-013-2948-5
  24. Lee N, Kim KN, Yi S, et al. Comparison of outcomes of anterior, posterior, and transforaminal lumbar interbody fusion surgery at a single lumbar level with degenerative spinal disease. *World Neurosurg*. 2017;101:S1878-8750(17)30140-7:216–226. doi:10.1016/j.wneu.2017.01.114
  25. Phan K, Ramachandran V, Tran T, Phan S, Rao PJ, Mobbs RJ. Impact of elderly age on complications and clinical outcomes following anterior lumbar interbody fusion surgery. *World Neurosurg*. 2017;105:503–509. doi:10.1016/j.wneu.2017.05.056
  26. Rao PJ, Phan K, Giang G, Maharaj MM, Phan S, Mobbs RJ. Subsidence following anterior lumbar interbody fusion (ALIF): a prospective study. *J Spine Surg*. 2017;3(2):168–175. doi:10.21037/jss.2017.05.03
  27. Tu Z, Li L, Wang B, Li Y, Lv G, Dai Y. Stand-alone Anterolateral interbody fusion versus extended posterior fusion for symptomatic adjacent-segment degeneration: a retrospective study of 2 years' follow-up. *World Neurosurgery*. 2018;115:e748–e755. doi:10.1016/j.wneu.2018.04.165
  28. Hsieh PC, Koski TR, O'Shaughnessy BA, et al. Anterior lumbar interbody fusion in comparison with transforaminal lumbar interbody fusion: implications for the restoration of foraminal height, local disc angle, lumbar lordosis, and sagittal balance. *J Neurosurg Spine*. 2007;7(4):379–386. doi:10.3171/SPI-07/10/379
  29. Kim CH, Chung CK, Park SB, Yang SH, Kim JH. A change in lumbar sagittal alignment after single-level anterior lumbar interbody fusion for lumbar degenerative spondylolisthesis with normal sagittal balance. *Clin Spine Surg*. 2017;30(7):291–296. doi:10.1097/BSD.0000000000000179
  30. Jackson KL, Yeoman C, Chung WM, Chappuis JL, Freedman B. Anterior lumbar interbody fusion: two-year results with a modular interbody device. *Asian Spine J*. 2014;8(5):591–598. doi:10.4184/asj.2014.8.5.591
  31. Lee DY, Lee SH, Maeng DH. Two-level anterior lumbar interbody fusion with percutaneous pedicle screw fixation: a minimum 3-year follow-up study. *Neurol Med Chir*. 2010;50(8):645–650. doi:10.2176/nmc.50.645
  32. Lee S-H, Kang B-U, Jeon SH, et al. Revision surgery of the lumbar spine: anterior lumbar interbody fusion followed

- by percutaneous pedicle screw fixation. *J Neurosurg Spine*. 2006;5(3):228–233. doi:10.3171/spi.2006.5.3.228
33. Liljenqvist U, O'Brien JP, Renton P. Simultaneous combined anterior and posterior lumbar fusion with femoral cortical allograft. *Eur Spine J*. 1998;7(2):125–131. doi:10.1007/s005860050042
34. Pavlov PW, Meijers H, van Limbeek J, et al. Good outcome and restoration of lordosis after anterior lumbar interbody fusion with additional posterior fixation. *Spine*. 2004;29(17):1893–1899. doi:10.1097/01.brs.0000137067.68630.70
35. Siepe CJ, Stosch-Wiechert K, Heider F, et al. Anterior stand-alone fusion revisited: a prospective clinical, X-ray and CT investigation. *Eur Spine J*. 2015;24(4):838–851. doi:10.1007/s00586-014-3642-y
36. Kapustka B, Kiwic G, Chodakowski P, et al. Anterior lumbar interbody fusion (ALIF): biometrical results and own experiences. *Neurosurg Rev*. 2020;43(2):687–693. doi:10.1007/s10143-019-01108-1
37. Malham GM, Parker RM, Blecher CM, Chow FY, Seex KA. Choice of approach does not affect clinical and radiologic outcomes: a comparative cohort of patients having anterior lumbar interbody fusion and patients having lateral lumbar interbody fusion at 24 months. *Global Spine J*. 2016;6(5):472–481. doi:10.1055/s-0035-1569055
38. Althoff AD, Kamalopathy P, Vatani J, Hassanzadeh H, Li X. Osteoporosis is associated with increased minor complications following single level ALIF and PSIF: an analysis of 7,004 patients. *J Spine Surg*. 2021;7(3):269–276. doi:10.21037/jss-21-29
39. Phan K, Fadhil M, Chang N, Giang G, Gragnaniello C, Mobbs RJ. Effect of smoking status on successful arthrodesis, clinical outcome, and complications after anterior lumbar interbody fusion (ALIF). *World Neurosurg*. 2018;110:S1878-8750(17)32090-9:e998–e1003. doi:10.1016/j.wneu.2017.11.157
40. Guzman JZ, Iatridis JC, Skovrlj B, et al. Outcomes and complications of diabetes mellitus on patients undergoing degenerative lumbar spine surgery. *Spine*. 2014;39(19):1596–1604. doi:10.1097/BRS.0000000000000482
41. Qin C, Kim JYS, Hsu WK. Impact of insulin dependence on lumbar surgery outcomes: an NSQIP analysis of 51,277 patients. *Spine*. 2016;41(11):E687–E693. doi:10.1097/BRS.0000000000001359
42. Feeley A, McDonnell J, Feeley I, Butler J. Obesity: an independent risk factor for complications in anterior lumbar interbody fusion. *Global Spine J*. 2022;12(8):1894–1903. doi:10.1177/21925682211072849
43. Strube P, Hoff E, Hartwig T, Perka CF, Gross C, Putzier M. Stand-alone anterior versus anteroposterior lumbar interbody single-level fusion after a mean follow-up of 41 months. *J Spinal Disord Tech*. 2012;25(7):362–369. doi:10.1097/BSD.0b013e3182263d91
44. Ahlquist S, Thommen R, Park HY, et al. Implications of sagittal alignment and complication profile with stand-alone anterior lumbar interbody fusion versus anterior posterior lumbar fusion. *J Spine Surg*. 2020;6(4):659–669. doi:10.21037/jss-20-595
45. Herkowitz HN, Kurz LT. Degenerative lumbar spondylolisthesis with spinal stenosis: a prospective study comparing decompression with decompression and intertransverse process arthrodesis. *J Bone Joint Surg Am*. 1991;73(6):802–808.
46. Lamberg TS, Remes VM, Helenius IJ, et al. Long-term clinical, functional and radiological outcome 21 years after posterior or posterolateral fusion in childhood and adolescence isthmic spondylolisthesis. *Eur Spine J*. 2005;14(7):639–644. doi:10.1007/s00586-004-0814-1
47. Bjarke Christensen F, Stender Hansen E, Laursen M, Thomsen K, Bünger CE. Long-term functional outcome of pedicle screw instrumentation as a support for posterolateral spinal fusion: randomized clinical study with a 5-year follow-up. *Spine*. date unknown;27(12):1269–1277. doi:10.1097/00007632-200206150-00006
48. France JC, Yaszemski MJ, Lauerman WC, et al. A randomized prospective study of posterolateral lumbar fusion: outcomes with and without pedicle screw instrumentation. *Spine*. date unknown;24(6):553–560. doi:10.1097/00007632-199903150-00010
49. Fritzell P, Hägg O, Wessberg P, Nordwall A. Chronic low back pain and fusion: a comparison of three surgical techniques: a prospective multicenter randomized study from the Swedish lumbar spine study group. *Spine*. date unknown;27(11):1131–1141. doi:10.1097/00007632-20020610-00002
50. Mardjetko SM, Connolly PJ. Degenerative lumbar spondylolisthesis: a meta-analysis of literature 1970-1993. *Spine*. 1994;19(20 Suppl):2265s. doi:10.1097/00007632-199410151-00002

**Funding:** This study received financial support from Medacta.

**Declaration of Conflicting Interests:** Christopher Kleck receives consulting fees from Medtronic, SeaSpine, Allosource, and Biocomposites. He receives research funding from Globus, Medtronic, SeaSpine, Medacta, Personalized Spine Study Group, Synergy, and SI Bone. Ankit Hirpara, Christina Koshak, Christopher Gallus, and Eric Marty receive research funding from Medacta.

**Institutional Review Board:** Approval from the institutional review board was obtained before conducting this study.

**Corresponding Author:** Christopher Kleck, University of Colorado Anschutz Medical Campus, 12631 E 17th Ave, Mail Stop B202, Room 4602, Aurora, CO 80045, USA; christopher.kleck@cuanschutz.edu

This manuscript is generously published free of charge by ISASS, the International Society for the Advancement of Spine Surgery. Copyright © 2024 ISASS. To see more or order reprints or permissions, see <http://ijssurgery.com>.