

Augmenting Endoscopic Transforaminal Spinal Decompression Surgery (Full Endoscopic Spine Surgery) Using Stimulated Electromyography Neuromonitoring Dilators

Dickson Hong Him Chau, Dhivakaran Gengatharan and Walter-Soon-Yaw Wong

Int J Spine Surg published online 6 December 2024
<https://www.ijssurgery.com/content/early/2024/12/05/8692>

This information is current as of December 11, 2024.

Email Alerts Receive free email-alerts when new articles cite this article. Sign up at:
<http://ijssurgery.com/alerts>

Augmenting Endoscopic Transforaminal Spinal Decompression Surgery (Full Endoscopic Spine Surgery) Using Stimulated Electromyography Neuromonitoring Dilators

DICKSON HONG HIM CHAU, MBBS, MRCS, MMED (ORTHO), FRCSED (ORTH)^{1,2}; DHIVAKARAN GENGATHARAN, MD¹; AND WALTER-SOON-YAW WONG, MBC_HB, MRCS¹

¹Department of Orthopedic Surgery, Sengkang General Hospital, Sengkang, Singapore; ²Department of Orthopaedics, SingHealth Duke-NUS Musculoskeletal Sciences, Academic Clinical Programme, Boulevard, Singapore

ABSTRACT

Background: Full endoscopic spine surgery via a transforaminal approach (FESS-TFA) offers a minimally invasive approach for spinal decompression. However, it carries a risk of nerve root irritation or injury. Existing intraoperative neuromonitoring primarily provides retrospective warnings of potential nerve disturbance.

Objective: To introduce the use of stimulated electromyography neuromonitoring dilators in FESS-TFA for proactive nerve protection, enhanced localization, and potential reduction in radiation exposure.

Methods: This technical note describes the first use of neuromonitoring dilators in FESS-TFA. A 6-mm dilator tipped with a stimulation electrode is introduced to provide real-time directional feedback regarding nerve proximity, allowing the surgeon to actively avoid accidental injury to the exiting nerve root. With the creation of a safe tract, subsequent introduction of working instruments would theoretically reduce the risk of neural injury.

Results: The technique was successfully applied in a case of T11/T12 severe spinal stenosis, facilitating safe instrument passage and nerve localization. We describe the surgical technique and provide illustrative intraoperative details.

Conclusion: Neuromonitoring dilators represent a promising innovation in FESS-TFA with the potential to enhance patient safety and possibly streamline the procedure. Larger-scale studies are warranted to quantify the true impact of this technique on complication rates, operative time, and radiation exposure.

Clinical Relevance: This technique highlights a significant advancement in reducing neural complications during minimally invasive spinal surgeries. By proactively preventing nerve irritation or injury and reducing radiation exposure, it contributes to optimizing surgical workflows and improving patient outcomes.

Level of Evidence: 5.

Endoscopic Minimally Invasive Surgery

Keywords: endoscopic spine surgery, neuromonitoring, nerve irritation

INTRODUCTION

Endoscopic transforaminal decompression, also known as full endoscopic spine surgery (FESS), is an emerging technique popularized by its minimal disruption to spinal tissue, direct visualization and access to compressive pathology, and reported shorter recovery times. It has proven itself to be an effective surgical technique.¹ The transforaminal approach (TFA) has been widely utilized since its introduction in 1972 by Kambin.² However, 1 of the primary concerns of this technique is the potential risk of irritation to the dorsal root ganglia, exiting nerve root, and the furcal nerve in the foraminal area. This risk has a reported incidence of up to 2% according to a meta-analysis of complications

of percutaneous endoscopic lumbar discectomy.^{3,4} The risk of such a complication is increased in older patients and those with severe disc degeneration.⁴

Efforts have been dedicated to reducing the risk of nerve root irritation and damage. Literature suggests considering open or microdiscectomy in cases where the exiting nerve root is positioned too low or if the distance between the exiting nerve root and facet is too narrow, aiming to reduce the risk of neural injury.⁵ Another commonly utilized approach is to use multi-modal intraoperative neuromonitoring (IONM) in the form of motor, somatosensory evoked potential, and electromyography to guide the operating surgeon as to when neural irritation occurs during FESS.^{6,7} However, a limitation of IONM is that it provides retrospective

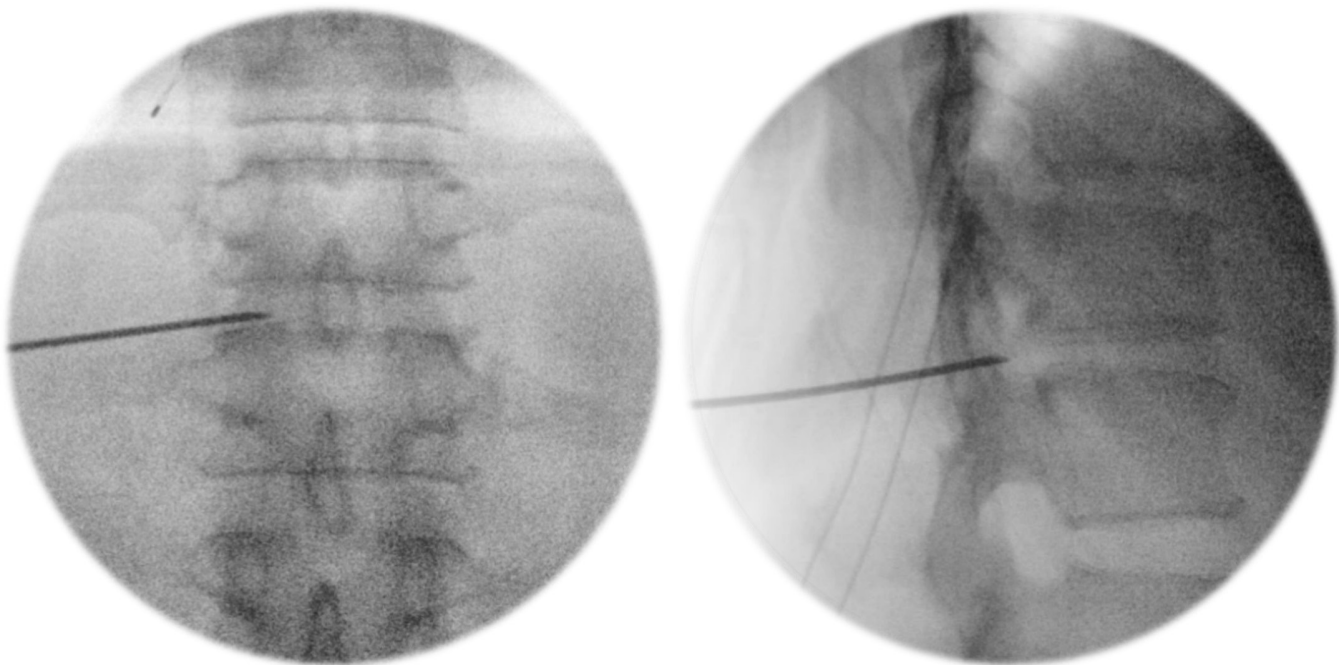


Figure 1. Guide-needle insertion through the neural foramen onto the T11–T12 disc, confirmed with fluoroscopy.

information; the signs of neural irritation and injury will only become apparent after the damage has been done.

As such, we wish to propose the use of stimulated electromyography (EMG) neuromonitoring dilators in FESS-TFA to aid in ensuring an adequate margin of clearance from neural tissue before the surgeon proceeds to safely introduce working instruments.

SURGICAL TECHNIQUE

The surgery was performed with a set of full endoscopic transforaminal uniportal surgical instruments (Richard Wolf [RiWo] GmbH—VERTEBRIS lumbar transforaminal endoscope). As per standard technique, a guide needle is passed under fluoroscopic guidance to dock on at the T11 to T12 intervertebral disc, through the Kambin's triangle. A guide wire is then passed through the guide needle and anchored in the disc (Figure 1).

This technique involves the use of a 6-mm neuromonitoring dilator (NuVasive, Inc.—NVM5 extreme lateral interbody fusion [XLIF] dilators) that allows for dynamically evoked electromyography (Figure 2 and Table). This stimulating probe applies pulsating electrical stimuli and delivers an electrical impulse near the nerve. A recording electrode will detect a resultant

muscle response of the corresponding myotome. By observing the amplitude of the EMG response detected, this technique allows us to determine the proximity of the instruments (stimulation probe and working cannula) to the nerve, providing active feedback during the initial instrumentation to adjust our trajectory and avoid nerve injury. The stimulation electrode is progressed through the neural foramen, while “real-time directionality” is achieved by rotating the dilator to direct the electrode tip toward the anticipated course of the exiting and traversing nerves. Feedback on the proximity to nervous tissue is provided as active amplitude (mA) readings.

In this case, upon setting the dilator tip within the neural foramen and directing the electrode cranially toward the T11 pedicle and T11 exiting nerve root, as well as dorsally away from the disc and toward the traversing nerve root, both returned an adequate amplitude of 12 mA (Figures 3–5).

With the assurance that instrumentation is adequately positioned away from neural tissue, a standard RiWo metal dilator and cannula were gently malleted and secured onto the annulus, following which a conventional FESS-TFA decompression and discectomy was completed.




Figure 2. A 6-mm neuromonitoring dilator, use adapted from the NuVasive NVM5 nerve monitoring system.

Table. Design features of the NVM5 6-mm dilator that render it suitable for FESS.

Design Feature	Intraoperative Applicability
Cannulated design 6-mm diameter	Easily passes over the guide wire. Snug fit with the endoscopic cannula, which is introduced without pinching tissue.
Carbon material isolating the electrode tip (white triangle)	“Real-time directionality”; receives signals only where electrode points. Carbon is brittle and needs to be swapped out for a metal dilator if malleting is required.

CASE PRESENTATION

An active 47-year-old woman presented with occasional radiculopathy to her lateral left thigh and calf, along with a neurogenic claudication pattern of a gluteal cramp after an average of 20 to 30 minutes of brisk walking. She suffered 6 months of progressing symptoms before presenting at our clinic, being mainly bothered by the claudication, which hampered her pastime of taking long walks for exercise.

Neurologically she retained full lower limb power and sensation, as well as normal autonomic functions. Lower limb pulses were normal without features suggestive of vascular disease.

Images of her spine (Figure 6) revealed a partially calcified diffuse disc bulge causing severe spinal canal stenosis, indenting on the conus as well as contributing to bilateral lateral recess stenosis at T11 to T12. There was no other appreciable significant stenosis in the rest of her spine.

Despite a trial of nonoperative management, the patient’s symptoms persisted for several months, and surgical intervention was discussed. Posterior decompression with far lateral access and potential facet resection requiring instrumentation and fusion was discussed; however, due to work commitments and the wish to avoid downtime, patient was keen for FESS-TFA decompression of the right side, accepting potential futility and secondary surgery to undergo a less invasive procedure. The distortion due to the partial calcifications was of some concern, which was attempted to be addressed with the technique described above.

The patient underwent a right T11/T12 transforaminal FESS with modifications as described above and illustrated in Figure 7. Intraoperative monitoring EMG activity was evoked from the anterolateral abdominal musculature (rectus and transversus abdominis).^{8,9} Postoperatively, the patient had no neurological injury and was able to return to her desired lifestyle of participating in prolonged brisk walking without any radicular symptoms or claudication.

DISCUSSION

The use of neuromonitoring dilators in FESS-TFA represents a novel, largely unexplored approach with the potential to optimize the safety and efficiency of this procedure. Our technical note documents the first use of this strategy to proactively avoid nerve root irritation and injury. Traditionally, the procedure involves

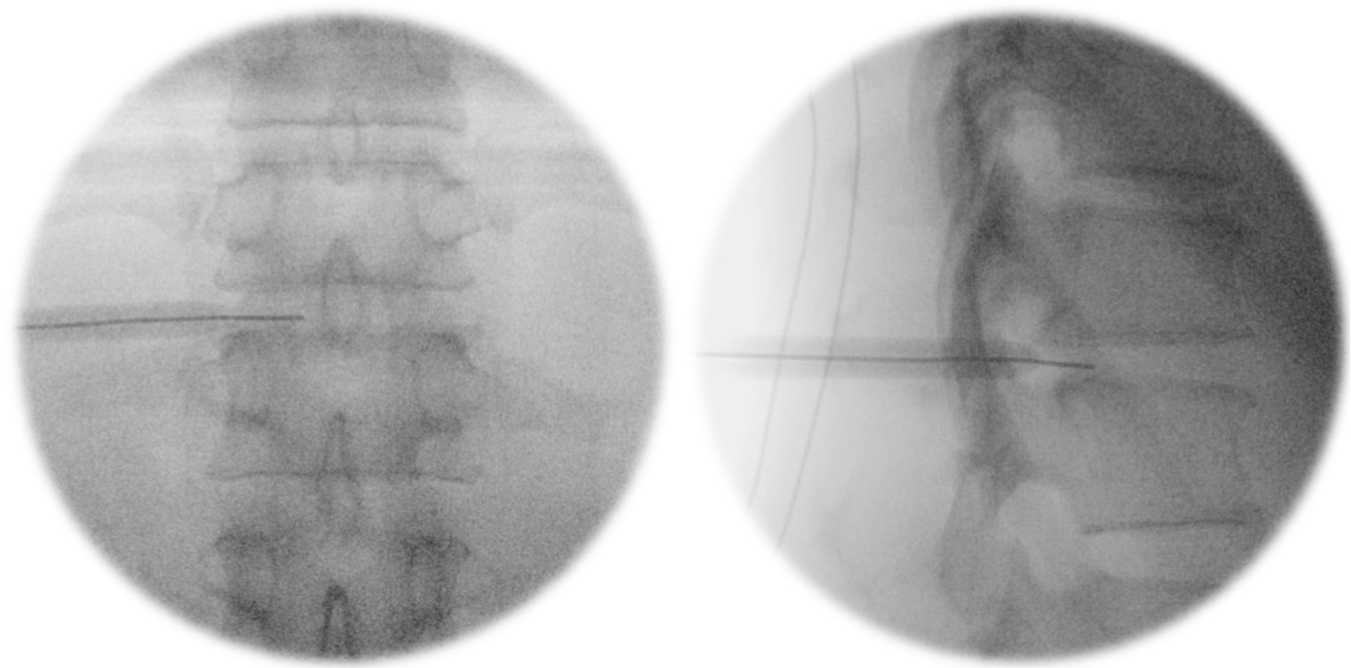


Figure 3. Passing the neuromonitoring dilator over the guidewire into the foramen.

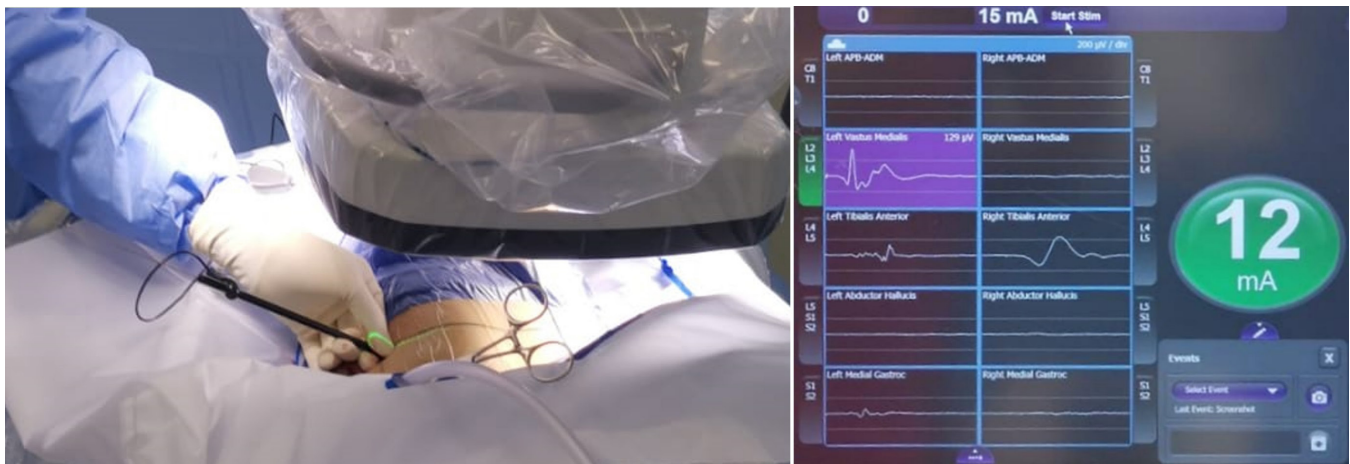

Figure 4. Rotating the electrode tip cranially and medially to obtain readings corresponding to neural tissue proximity.

the insertion of a fluoroscopy-guided wire followed by nonaugmented dilators, with IONM primarily indicating potential nerve disturbances after they might have occurred.^{6,10,11} In contrast, neuromonitoring dilators offer the advantage of proactive nerve protection. By providing real-time feedback on nerve proximity, they allow the surgeon to adjust instrument placement accordingly, instead of reacting retrospectively to injury caused. This technique may be particularly useful considering that IONM has shown that 72.7% of patients experienced compression of the exiting nerve root's DRG during initial transforaminal placement of the working cannula.⁶

Moreover, neuromonitoring dilators can enhance intraoperative localization. Their dynamic feedback assists in precise identification of the nerve root and helps delineate the extent of foraminal stenosis. This enhanced visualization translates to multiple potential benefits, including streamlined surgical workflow and potentially reduced time spent meticulously navigating near critical neural structures. This follows principles similar to the neuromonitoring probe and finger electrodes used for XLIF cases to reduce their rate of neural injury.^{12–14}

An additional potential advantage of neuromonitoring dilators is a possible reduction of radiation exposure.

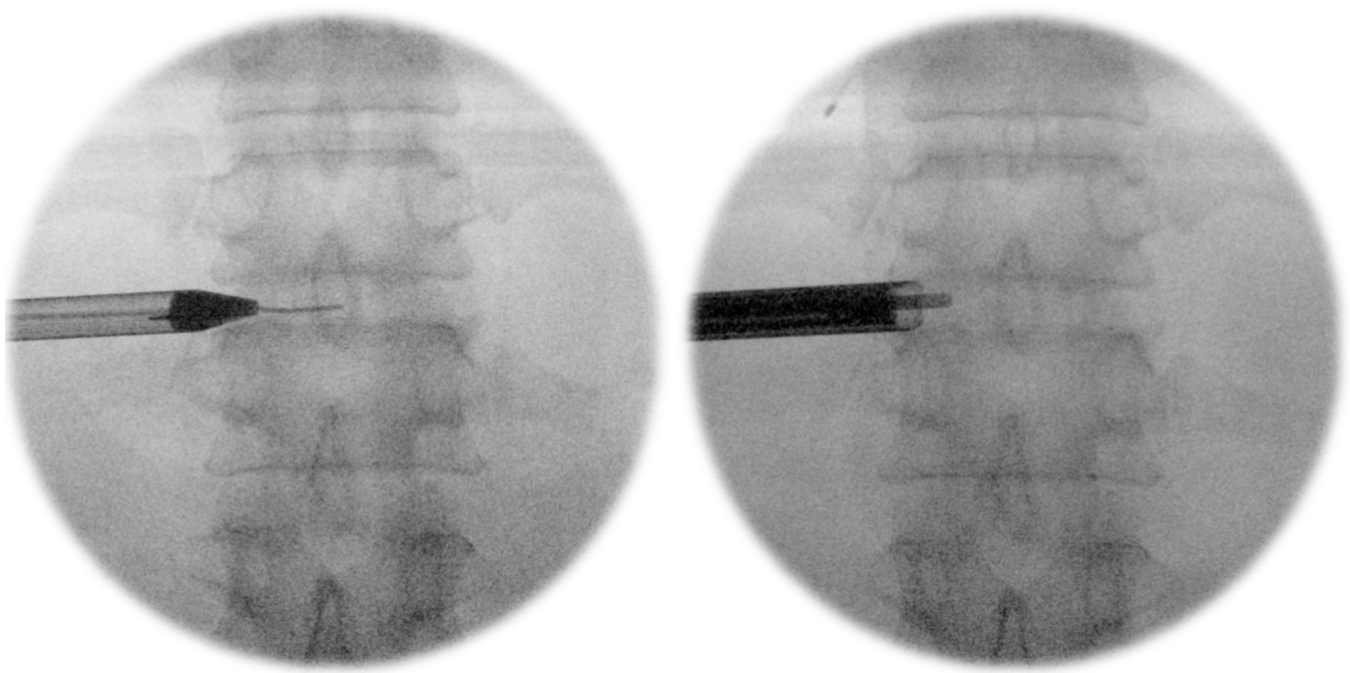


Figure 5. Insertion of transforaminal endoscopic instruments via the “safe tract.”

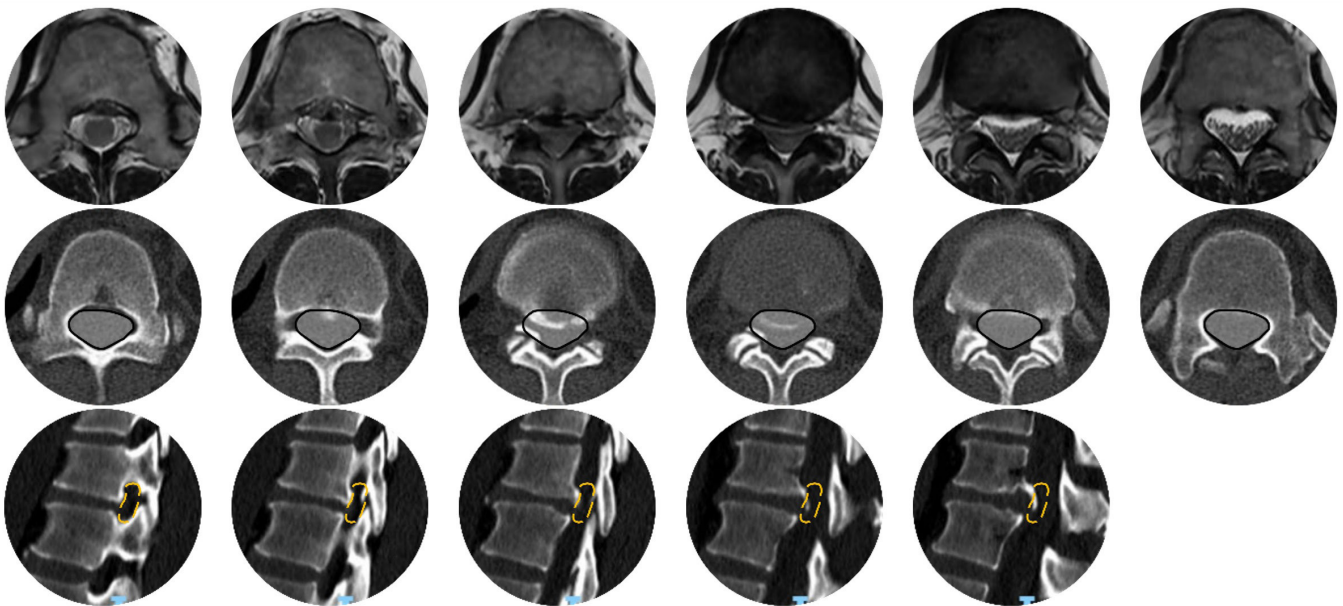
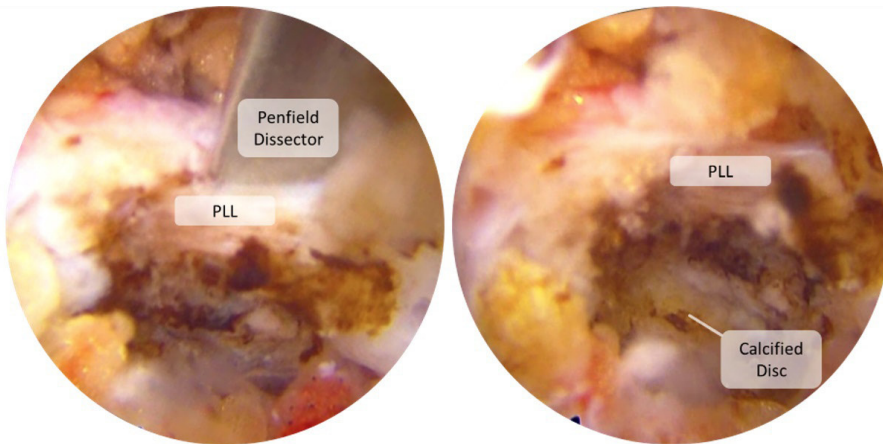
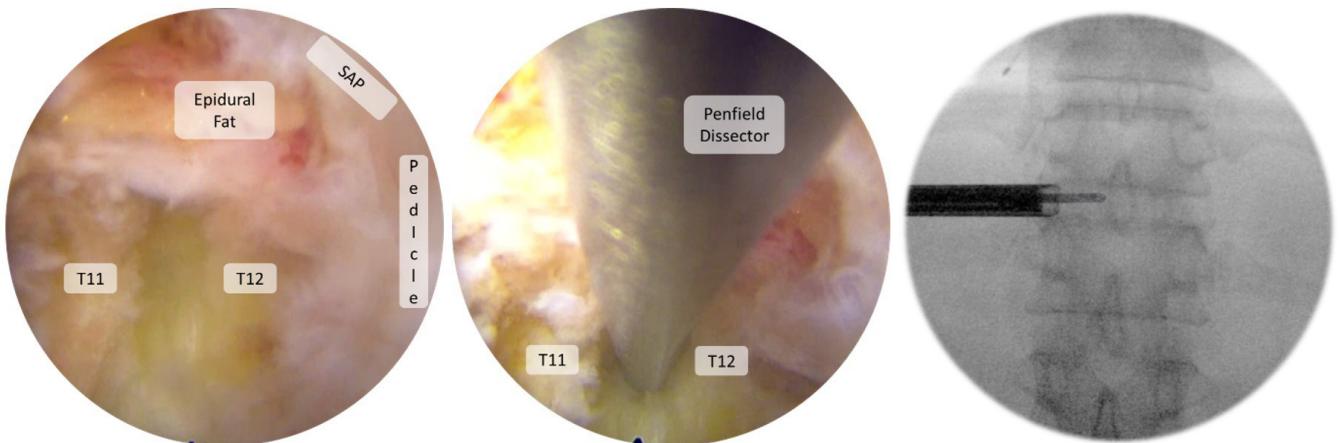


Figure 6. Images showing a T11/T12 partially calcified disc causing spinal canal stenosis. Top row: Magnetic resonance imaging axial cuts. Middle row: Corresponding computed tomography (CT) axial cuts. Bottom row: CT sagittal cuts (left).



Pre-decompression endoscopic views of the PLL, and of the calcified disc encroaching on the neural structures.



Post-decompression endoscopic views, with the Penfield dissector freely approaching midline.

Figure 7. Endoscopic views pre- and postdecompression. Top: Predecompression endoscopic views of the posterior longitudinal ligament (PLL) and of the calcified disc encroaching on the neural structures. Bottom: Postdecompression endoscopic views, with the Penfield dissector freely approaching midline.

By providing continuous feedback on instrument position, they could decrease the need for repeated fluoroscopic imaging during surgery, minimizing radiation for both the patient and surgical team.

While further research is needed to fully quantify these benefits, this technique signals a promising refinement of the FESS-TFA approach. Larger-scale studies will be crucial in determining the impact of neuromonitoring dilators on complication rates, operative time, and cost-effectiveness. These studies will help determine whether the potential advantages of this technique justify its integration into routine FESS-TFA practice.

CONCLUSION

This technical note showcases the first use of neuromonitoring dilators in FESS. With this new technique, we hope that a shorter surgical time along with a lower risk of nerve root damage can be achieved.

REFERENCES

1. Lokhande PV. Full endoscopic spine surgery. *J Orthop.* 2023;40:74–82. doi:10.1016/j.jor.2023.04.010
2. Kambin P, Sampson S. Posterolateral percutaneous suction-excision of herniated lumbar intervertebral discs. Report of interim results. *Clin Orthop Relat Res.* 1986;(207):37–43.
3. Jitpakdee K, Liu Y, Kotheeranurak V, Kim J-S. Transforaminal versus interlaminar endoscopic lumbar discectomy for lumbar disc herniation: a systematic review and meta-analysis. *Glob Spine J.* 2023;13(2):575–587. doi:10.1177/21925682221120530
4. Fan N, Yuan S, Du P, et al. Complications and risk factors of percutaneous endoscopic transforaminal discectomy in the treatment of lumbar spinal stenosis. *BMC Musculoskelet Disord.* 2021;22(1):1041. doi:10.1186/s12891-021-04940-z
5. Choi I, Ahn JO, So WS, Lee SJ, Choi II, Kim H. Exiting root injury in transforaminal endoscopic discectomy: preoperative image considerations for safety. *Eur Spine J.* 2013;22(11):2481–2487. doi:10.1007/s00586-013-2849-7
6. de Carvalho PST, Ramos MRF, da Silva Meireles AC, et al. Feasibility of using intraoperative neuromonitoring in the prophylaxis of dysesthesia in transforaminal endoscopic discectomies of the lumbar spine. *Brain Sci.* 2020;10(8). doi:10.3390/brainsci10080522
7. Chen Y, Luo C, Wang J, et al. Roles of multimodal intraoperative neurophysiological monitoring (IONM) in percutaneous endoscopic transforaminal lumbar interbody fusion: a case series of 113 patients. *BMC Musculoskelet Disord.* 2021;22(1):989. doi:10.1186/s12891-021-04824-2
8. Fahim DK, Kim SD, Cho D, Lee S, Kim DH. Avoiding abdominal flank bulge after anterolateral approaches to the thoracolumbar spine: cadaveric study and electrophysiological investigation. *J Neurosurg Spine.* 2011;15(5):532–540. doi:10.3171/2011.7.SPINE10887
9. Raynor BL, Lenke LG, Kim Y, et al. Can triggered electromyograph thresholds predict safe thoracic pedicle screw placement? *Spine.* 2002;27(18):2030–2035. doi:10.1097/00007632-200209150-00012
10. Wu PH, Kim HS, Lee YJ, et al. Uniportal full endoscopic posterolateral transforaminal lumbar interbody fusion with endoscopic disc drilling preparation technique for symptomatic foraminal stenosis secondary to severe collapsed disc space: a clinical and computer tomographic study with technical note. *Brain Sci.* 2020;10(6). doi:10.3390/brainsci10060373
11. Ju CI. Technical considerations of the transforaminal approach for lumbar disk herniation. *World Neurosurg.* 2021;145:597–611. doi:10.1016/j.wneu.2020.08.229
12. Narita W, Takatori R, Arai Y, et al. Prevention of neurological complications using a neural monitoring system with a finger electrode in the extreme lateral interbody fusion approach. *J Neurosurg Spine.* 2016;25(4):456–463. doi:10.3171/2016.1.SPINE151069
13. Epstein NE. Many intraoperative monitoring modalities have been developed to limit injury during extreme lateral interbody fusion (XLIF/MIS XLIF): does that mean XLIF/MIS XLIF are unsafe? *Surg Neurol Int.* 2019;10:233. doi:10.25259/SNI_563_2019
14. Arnold PM, Anderson KK, McGuire RA Jr. The lateral transposas approach to the lumbar and thoracic spine: a review. *Surg Neurol Int.* 2012;3(Suppl 3):S198–S215. doi:10.4103/2152-7806.98583

Funding: The authors received no financial support for the research, authorship, and/or publication of this article.

Declaration of Conflicting Interests: The authors report no conflicts of interest in this work.

Author Contributions: Conceptualization: W.W. and D.H.H.C. Methodology: W.W. and W.H.H.C. Resources: D.G. and D.H.H.C. Writing—original draft preparation: D.G. and D.H.H.C. Writing—review and editing: W.W. Supervision: D.H.H.C. and W.W. Project administration: W.W. All authors have read and agreed to the published version of the manuscript.

Corresponding Author: Dr Walter-Soon-Yaw Wong, Department of Orthopaedic Surgery, Sengkang General Hospital, 110 Sengkang E. Way, Sengkang, Singapore 544886, Singapore; walterwongsy@gmail.com

This manuscript is generously published free of charge by ISASS, the International Society for the Advancement of Spine Surgery. Copyright © 2024 ISASS. To see more or order reprints or permissions, see <http://ijssurgery.com>.