

Minimally Invasive SI Joint Fusion Procedures for Chronic SI Joint Pain: Systematic Review and Meta-Analysis of Safety and Efficacy

Peter G. Whang, Vikas Patel, Bradley Duhon, Bengt Sturesson, Daniel Cher, W. Carlton Reckling, Robyn Capobianco and David Polly

Int J Spine Surg 2023, 17 (6) 794-808

doi: <https://doi.org/10.14444/8543>

<http://ijssurgery.com/content/17/6/794>

This information is current as of May 21, 2024.

Email Alerts Receive free email-alerts when new articles cite this article. Sign up at:
<http://ijssurgery.com/alerts>

Minimally Invasive SI Joint Fusion Procedures for Chronic SI Joint Pain: Systematic Review and Meta-Analysis of Safety and Efficacy

PETER G. WHANG, MD¹; VIKAS PATEL, MD²; BRADLEY DUHON, MD³; BENGT STURESSON, MD, PhD⁴; DANIEL CHER, MD⁵; W. CARLTON RECKLING, MD⁵; ROBYN CAPOBIANCO, PhD⁵; AND DAVID POLLY, MD⁶

¹Department of Orthopedics and Rehabilitation, Yale University School of Medicine, New Haven, CT, USA; ²Department of Orthopedics and Spine Surgery, University of Colorado, Aurora, CO, USA; ³Front Range Spine and Neurosurgery, Lone Tree, CO, USA; ⁴Department of Orthopedics, Ängelholm Hospital, Ängelholm, Sweden; ⁵SI-BONE, Inc., Santa Clara, CA, USA; ⁶Department of Orthopedics, University of Minnesota, Minneapolis, MN, USA

ABSTRACT

Background: Sacroiliac (SI) joint fusion is increasingly used to treat chronic SI joint pain. Multiple surgical approaches are now available.

Methods: Data abstraction and random effects meta-analysis of safety and efficacy outcomes from published patient cohorts. Patient-reported outcomes (PROs) and safety measures were stratified by surgical technique: transiliac, including lateral transiliac (LTI) and posterolateral transiliac (PLTI), and posterior interpositional (PI) procedures.

Results: Fifty-seven cohorts of 2851 patients were identified, including 43 cohorts (2126 patients) for LTI, 6 cohorts (228 patients) for PLTI, and 8 cohorts (497 patients) for PI procedures. Randomized trials were only available for LTI. PROs were available for pain (numeric rating scale) in 57 cohorts (2851 patients) and disability (Oswestry Disability Index [ODI]) in 37 cohorts (1978 patients).

All studies with PROs showed improvement from baseline after surgery. Meta-analytic improvements in pain scores were highest for LTI (4.8 points [0–10 scale]), slightly lower for PLTI (4.2 points), and lowest for PI procedures (3.8 points, $P = 0.1533$). Mean improvements in ODI scores were highest for LTI (25.9 points), lowest for PLTI procedures (6.8 points), and intermediate for PI (16.3 points, $P = 0.0095$).

For safety outcomes, acute symptomatic implant malposition was 0.43% for LTI, 0% for PLTI, and 0.2% for PI procedures. Wound infection was reported in 0.15% of LTI, 0% of PLTI, and 0% of PI procedures. Bleeding requiring surgical intervention was reported in 0.04% of LTI procedures and not reported for PLTI or PI. Breakage and migration were not reported for any device. Radiographic imaging evaluation reporting implant placement accuracy and fusion was only available for LTI.

Discussion: Literature support for SI joint fusion is growing. The LTI procedure contains the largest body of available evidence and shows the largest improvements in pain and ODI. Only LTI procedures have independent radiographic evidence of fusion and implant placement. The adverse event rate for all procedures was low.

Level of Evidence: 1.

Minimally Invasive Surgery

Keywords: sacroiliac joint, sacroiliac joint fusion, lateral transiliac, systematic review, meta-analysis

INTRODUCTION

The sacroiliac (SI) joint is a common cause of chronic low back pain (15%–30%).^{1,2} In patients with low back pain following lumbar fusion, SI joint pain may be a more common cause (as high as 40%).³ Nonsurgical treatments for SI joint pain include physical therapy, pain medications, SI joint injections (corticosteroids or other substances), and radiofrequency ablation.

Fusion of the SI joint was first reported in the early 1900s.⁴ While several technical variations on open SI joint fusion have been reported,⁵ open fusion techniques solely to address discrete SI joint pain are now rarely performed due to significant operative and postoperative

morbidity.⁶ The American Medical Association (AMA) assigned a Current Procedural Technology (CPT) to the open SI joint fusion procedure in the 1980s and refined the description in 2014.

In the early 2000s, minimally invasive transiliac procedures for SI joint stabilization and fusion were developed. These procedures follow the lateral trajectory described by Routt for the stabilization of traumatic injuries involving the SI joint.⁷ The earliest (and most common) version of this procedure involves the placement of metallic devices laterally to medially through the ilium, across the SI joint and into the sacrum (Figure 1). The term lateral transiliac (LTI) is used here to describe this procedure. Although standard

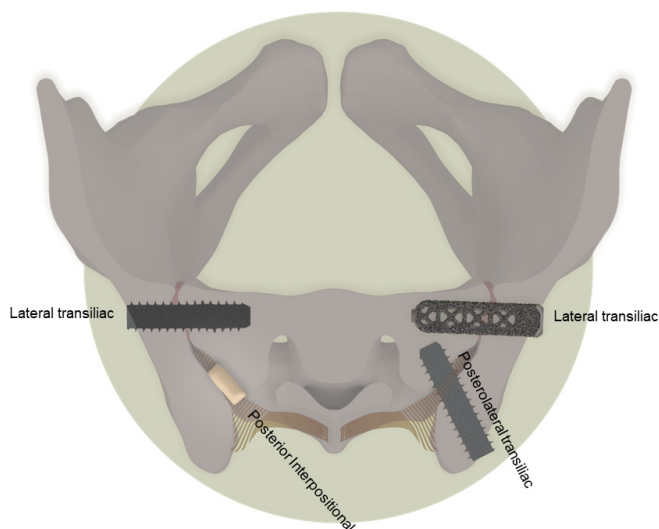


Figure 1. Diagram of trajectories for minimally invasive sacroiliac joint fusion.

bone screws were used initially, in the late 2000s, triangular titanium implants (TTI) (iFuse Implant System, SI-BONE, Santa Clara, CA) were designed specifically for SI joint fusion procedures using an LTI approach. Typically, 3 devices are placed such that the implants traverse 3 bony cortices and terminate near or at the sacral body. Termination at or near the sacral body is advantageous as the body has superior bone quality compared with the ala.^{8,9} These implants stabilize the SI joint acutely through their triangular shape, which resists rotation within bone, as well as forming multiple points of fixation. Long-term (permanent) stabilization is achieved via bone growth onto the implant surface and through the implant fenestrations and across the SI joint. Several biomechanical studies provide additional support for these implants.^{10–12} Early studies of the use of TTI for SI joint fusion via the LTI procedure showed that this approach provides immediate and sustained improvement in pain and related disability, with improvements that exceeded those of nonsurgical treatment.^{13–15} With accumulating evidence, AMA CPT published a code (27279) that describes minimally invasive SI joint fusion using this LTI approach. Subsequently, and not surprisingly, additional metallic devices were developed and cleared for SI joint fusion by the US Food and Drug Administration.

More recently, a variation of the LTI procedure, in which the devices are placed at a posterior lateral angle across the SI joint (see Figure 1), was developed. Here, this is referenced as a posterolateral transiliac (PLTI) procedure. Examples of US Food and Drug Administration–cleared devices for PLTI procedures include RIALTO (Medtronic), Sacrofuse (Sacrix), SI-LOK (Globus Medical), and Transloc (Foundation Fusions

Systems). As these procedures involve placement of devices through the ilium across the SI joint into the sacrum, they are considered a variant on transiliac procedures described by CPT 27279. In contrast to LTI, the PLTI technique has a more posterior starting point and takes an oblique trajectory across the SI joint. It was developed to lower the risk of injury/irritation of the S1 and S2 nerves within the foramina and to the branches of the superior gluteal artery.

Another procedure involves placing implants (either structural bone allografts or metallic devices) directly into the SI joint from a posterior approach without transfixing the joint, that is, a posterior interpositional or intra-articular (PI) approach. Examples of metallic devices include NADIA (Ilion Medical) and DIANA (SIGNUS). The same PI procedure can be performed with structural allografts, which are available from multiple vendors. The PI procedure relies on ligamentotaxis for early/short-term SI joint stabilization and distraction arthrodesis (DA) for long-term SI joint fusion. The AMA CPT panel provided clarification that such PI procedures are fundamentally different than transiliac procedures (LTI and PLTI), and a new tracking code (0775T) was assigned. A new AMA CPT Category I code for minimally invasive SI joint fusion with a PI procedure will become effective on 1 January 2024.

Finally, some recently marketed devices are placed in a posterior procedure with device elements that span or bridge the SI joint and engage in both the medial ilium and the lateral sacrum. Examples of such devices include Catamaran (Tenon) and Transfix (Aurora). Published clinical literature describing the safety and/or effectiveness of this type of device and this procedure variation is currently lacking.

Previous meta-analyses of the safety and effectiveness of various procedures for minimally invasive SI joint fusion have been published. To date, no meta-analysis has characterized minimally invasive SI joint fusion safety and effectiveness on the basis of implant placement procedure using the most recently updated AMA CPT procedural descriptions. In the present article, we identify and analyze published clinical cohorts of patients undergoing minimally invasive SI joint fusion using transiliac (LTI and PLTI) procedures and PI procedures.

METHODS

The reporting of this systematic review was guided by the standards of the Preferred Reporting Items for Systematic Review and Meta-Analysis Statement.

Table 1. Summary of data abstraction from each identified study.

Characteristic	Variable Type	Choices/Comment
Study design	Binary	Prospective vs retrospective
Procedure type	Nominal	Transiliac (either lateral or posterolateral) or posterior interpositional
Device/allograft used	Nominal	Name of device
Number of patients treated	Integer	
Number of patients with follow-up scores	Integer	
Baseline and last follow-up pain score (visual analog scale or numeric pain rating scale)	Continuous	Converted to 0- to 10-point scale
Baseline and last ODI	Continuous	For both pain score and ODI, when multiple scheduled follow-up visits were available, the last available reported mean score was extracted.
Safety outcomes:	Integer	Fracture defined as involving both cortices of the ilium or sacrum and displacement of a significant fragment of bone.
<ul style="list-style-type: none"> ● Symptomatic implant malposition—typically resulting in new onset acute radicular pain—requiring surgical intervention. ● Symptomatic implant malposition causing bowel/bladder perforation. ● Implant breakage. ● Implant migration. ● Late removal—typically for ongoing or recurrent pain. ● Dislodgement of bone fragment into foramen during placement. ● Fracture (sacral or ilial) during placement. ● Wound infection requiring notable treatment such as wound exploration or implant removal. ● Bleeding requiring surgical intervention. 		

Abbreviation: ODI, Oswestry Disability Index.

Literature Search

Published literature describing cohorts of patients undergoing SI joint fusion was identified through structured Medline searching using the search term “sacroiliac joint fusion” or “sacroiliac joint arthrodesis.” Articles published between January 2010 and June 2023 were included. A literature search was performed on 28 March 2023 and updated in July 2023. Studies were included if they included patients seeking operative care for chronic SI joint pain diagnosed via medical history, physical examination, and diagnostic SI joint block and reported operative and/or long-term (>3 months) outcomes after minimally invasive SI joint fusion using metallic devices or allografts. Studies with incomplete reporting, or those reporting only follow-up scores (e.g., Beck¹⁶), were excluded. Where possible, duplicate reports of the same cohort were excluded.

Data Abstraction

Abstracts from Medline searches were reviewed, and relevant full-text articles were obtained. Studies were reviewed by at least 2 authors. Any discrepancies in data abstraction were resolved by discussion. For each article, information shown in Table 1 was reviewed and extracted into an Excel worksheet. Results from studies reporting the use of more than 1 device were, where possible, extracted separately. Hence, reporting is on the basis of cohorts, not studies.

Study design is a potentially important source of bias. Studies that noted prospective capture of data but no systematic reporting of follow-up data (eg, number withdrawn, loss to follow-up, etc) were deemed retrospective.

Statistical Analysis

Excel data were imported into and analyzed in R on the RStudio platform. Random effects meta-analysis and meta-regression were performed using the *metafor* library.¹⁷ Meta-regression focused on change scores only. Graphical analysis was performed using the *ggplot2* library.

Poolability was assessed on the basis of the combination of study design, target patient population, interventions, and data reporting. Although study reporting was not all complete, all identified studies appeared to target the same patient population and use similar approaches to data capture.

Many studies did not report change scores or measures of variation (ie, SD). Missing SDs were imputed as the average of available reported SDs. Studies not reporting baseline scores were generally excluded. For those studies using more than 1 device that reported outcomes separately, results were separately abstracted. When duplicate studies were identified, only the latest study was used for abstraction. Funnel plots were examined within procedure type to detect evidence of

Table 2. Summary of available studies for efficacy (pain scores and ODI).

Procedure	Device	Cohorts	Patients	
Studies reporting SI				
Joint Pain Scores				
LTI	HMA screw	3	79	
	iFuse	31	1605	
	Sacrofuse	1	3	
	SI-LOK	3	136	
	Simmerty	4	288	
	Torpedo	1	15	
	Total	43	2126	
	PLTI	Rialto	3	122
		Sacrix	1	19
		SI-LOK	1	36
Total		6	228	
PI	DIANA	2	190	
	LINQ	4	237	
	Threaded cage	1	13	
	Total	8	497	
Total		57	2851	
Studies reporting ODI				
LTI	HMA screw	1	9	
	iFuse	23	1161	
	Sacrofuse	1	3	
	SI-LOK	2	72	
	Simmerty screw	3	269	
	Torpedo	1	15	
	Simmerty, Corelink, or LnK	1	55	
	Total	32	1584	
	PLTI	Rialto	2	135
	PI	DIANA threaded cage	2	190
LINQ		1	69	
Total		3	259	
Total		37	1978	

Abbreviations: HMA, hollow modular anchor; LTI, lateral transiliac; ODI, Oswestry Disability Index; PI, posterior interpositional; PLTI, posterolateral transiliac.

publication bias. Data are available upon reasonable request.

RESULTS

Dataset

The literature search resulted in 464 hits. After review of abstracts and addition of 4 previously known cohorts not identified via Medline hits, a total of 122 full-text articles were obtained and reviewed, of which 56 met eligibility criteria. An additional literature search in July 2023 revealed 5 additional relevant cohorts. One study of placement of plates (not minimally invasive) or implants placed in a sacroalar iliac trajectory (not commonly performed in the United States and Europe) was excluded.¹⁸

Efficacy

Efficacy results were reported in 57 cohorts (2851 patients, Table 2) for pain scores and 37 cohorts (1978 patients) for Oswestry Disability Index (ODI). The largest number of studies involved use of iFuse Implant

Table 3. Proportion of studies noted to be prospective.

Procedure	Studies Reporting Pain Scores		Studies Reporting Oswestry Disability Index	
	N/Total	%	N/Total	%
LTI	9/43	21%	8/32	25%
PLTI	0/6	0%	0/2	0%
PI	3/8	38%	2/3	67%
Total	12/57	21%	10/37	27%

Abbreviations: LTI, lateral transiliac; ODI, Oswestry Disability Index; PI, posterior interpositional; PLTI, posterolateral transiliac.

System (SI-BONE, Inc., Santa Clara, CA, USA), placed through the LTI procedure. There were fewer PI studies reporting pain or ODI scores, but these studies were more likely to be prospective (Table 3).

Baseline (green) and last follow-up (blue) mean scores for each cohort are shown in Figure 2 for pain scores and Figure 3 for ODI.

ODI was reported in 31 LTI cohorts (1584 patients), 2 PLTI cohorts (135 patients), and 3 PI cohorts (259 patients). Prospective study designs were used in 25% of LTI cohorts, 0% of PLTI cohorts, and 67% of PI cohorts. Meta-analytic mean scores at baseline and last follow-up were as follows: for LTI procedure, 56.2 (52.5–60) and 30.9 (26.8–34.9); for PLTI procedure, 51.5 (47.4–55.6) and 44.8 (39.3–50.3), and for the PI procedure, 54.6 (48.3–60.9) and 40.6 (28.2–53.1).

Change scores for pain ratings and ODI are shown in Figure 4 and Figure 5. These figures similarly show that meta-analytic mean improvements for pain scores were larger for LTI procedures (4.8 points, 95% CI 4.5–5.2), slightly lower with PLTI (4.2 points, 2.6–5.8), and lowest with PI procedures (3.8 points, 2.9–4.7, analysis of variance [ANOVA] $P = 0.1533$). Similarly, ODI scores were larger for LTI procedures (25.8, 22.8–28.9) vs PLTI (6.8, 4.0–9.6) and PI (16.3, 12.0–20.6, analysis of variance $P = 0.0095$) procedures. This analysis was limited as only 2 PLTI studies and 3 PI studies included ODI. Funnel plots (not shown) did not indicate publication bias.

Meta-regression showed no impact of study design (ie, prospective vs retrospective studies) on change scores for either SI joint pain or ODI.

Safety

Safety outcomes by procedure and study are shown in Table 4. In total, 63 cohorts reported outcomes on 3162 patients (Table 5). Prospective designs were used in 9/47 (19%) of LTI cohorts, 0/8 (0%) of PLTI cohorts, and 3/8 (38%) of PI cohorts. Most published studies involved LTI placement of metal implants (47 cohorts and 2348 patients). In the LTI category, iFuse Implant

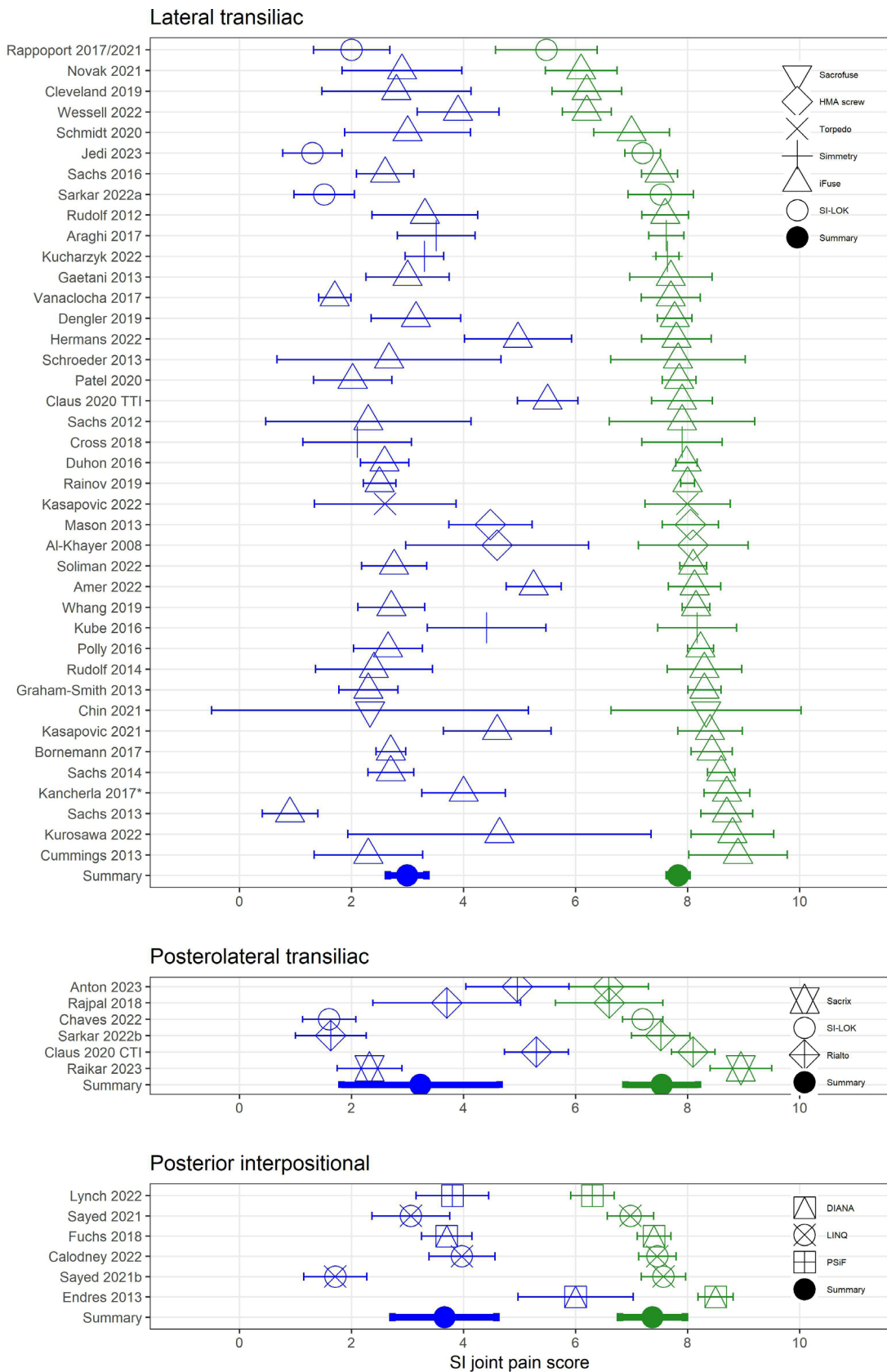


Figure 2. Baseline and last follow-up sacroiliac (SI) joint pain scores by procedure, study, and device. Baseline scores are shown in green, and last follow-up scores are shown in blue. Sarkar reported (a) lateral transiliac and (b) posterolateral transiliac cohorts. Wider lines represent random effects meta-analytic means and 95% CIs. Sarkar reported (a) lateral transiliac and (b) posterolateral transiliac cohorts. Sayed 2021b refers to reference 87. *Cohort contained mostly TTI (n = 36) with some screws (n = 9). TTI, triangular titanium implants; CTI, cylindrical titanium implants.

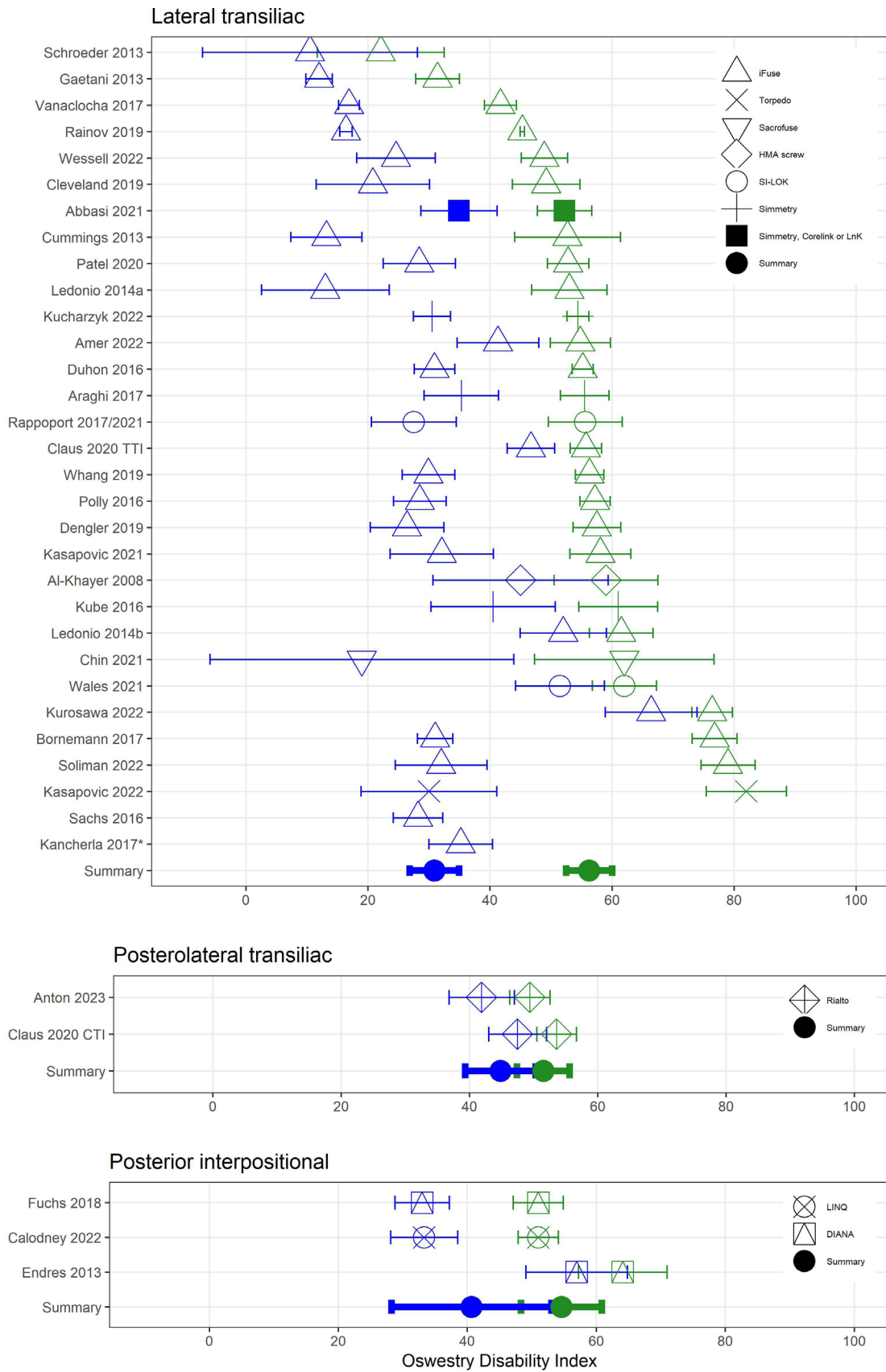


Figure 3. Baseline and last follow-up Oswestry Disability Index scores by procedure, study, and device. Baseline scores are shown in green; last follow-up scores are shown in blue. Wider lines represent random effects meta-analytic means and 95% CIs. Ledonio 2014a refers to reference 64 and Ledonio 2014b refers to reference 65. *Cohort contained mostly TTI (n = 36) with some screws (n = 9). TTI, triangular titanium implants; CTI, cylindrical titanium implants.

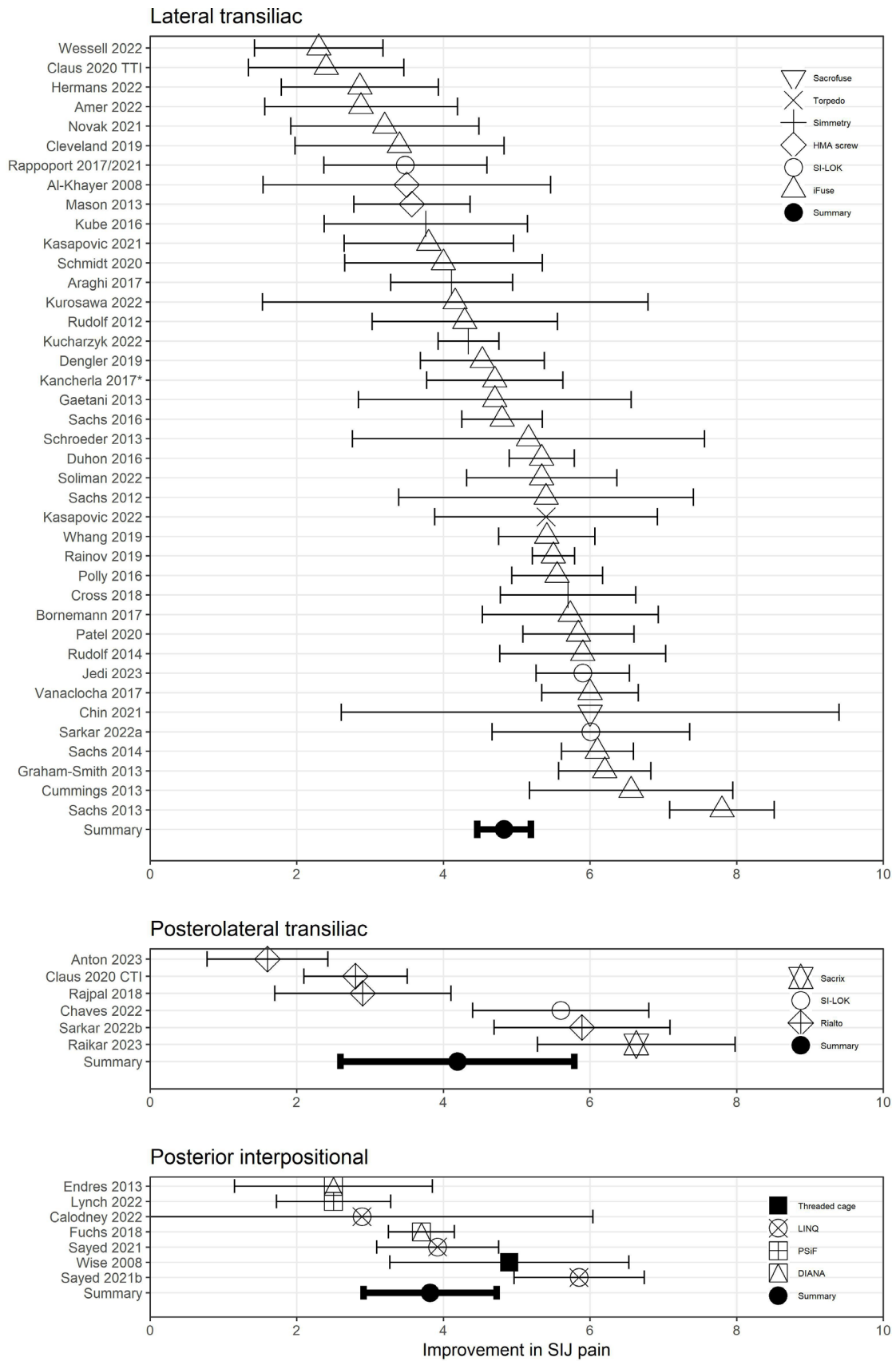


Figure 4. Improvement in sacroiliac (SI) joint pain score by procedure and device. Sarkar reported (a) lateral transiliac and (b) posterolateral transiliac cohorts. Sayed 2021 refers to reference 86 and Sayed 2021b refers to 87. *Cohort contained mostly TTI ($n = 36$) with some screws ($n = 9$). CTI, cylindrical titanium implants; TTI, triangular titanium implants.

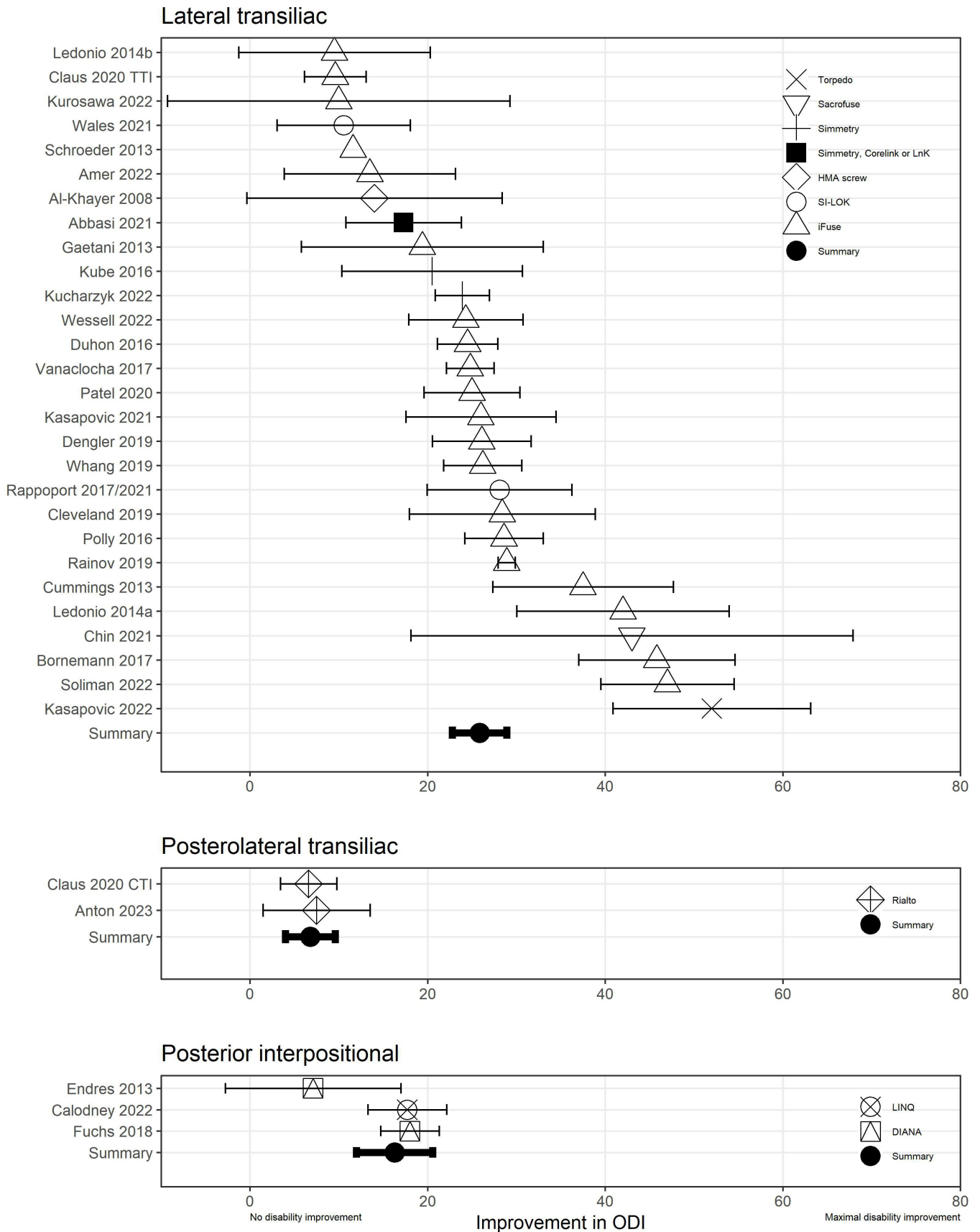


Figure 5. Improvement in Oswestry Disability Index score by procedure and device. Ledonio 2014a refers to reference 64 and Ledonio 2014b refers to reference 65. CTI, cylindrical titanium implants; TTI, triangular titanium implants.

Table 4. Safety outcomes by procedure, device, and study design.

Procedure	Device	Design	Author, Year	N	Mean Follow-Up, mo	Acute Symptomatic Malposition	Breakage	Migration	Bowel/Bladder Perforation	Late Removal	Dislodgement of Bone			Wound Infection	Bleeding Requiring Surgical Intervention
											Fracture	Fragment Into Foramen	Fracture		
Lateral transiliac	HMA screw	Retro	Al-Khayr, 2008 ¹⁹	9	40	0	0	0	0	0	0	0	0	0	0
	HMA screw	Prosp	Mason, 2013 ²⁰	55	36	2	0	0	0	0	0	0	0	0	0
	HMA screw	Retro	Khurana, 2009 ²¹	15	17	0	0	0	0	0	0	0	0	0	0
	iFuse	Retro	Bornemann, 2017 ²²	24	24	0	0	0	0	0	0	0	0	0	0
	iFuse	Retro	Cummings, 2013 ²³	18	12	1	0	0	0	0	0	0	0	0	0
	iFuse	Prosp	Dengler, 2019 ¹⁴	52	24	1	0	0	0	0	0	0	0	0	1
	iFuse	Prosp	Duhon, 2016 ¹⁵	172	24	2	0	0	0	0	0	0	0	6	1
	iFuse	Retro	Novak, 2021 ²⁴	21	12	0	0	0	0	0	0	0	0	0	0
	iFuse	Prosp	Patel, 2020 ²⁵	51	12	0	0	0	0	0	0	0	0	0	0
	iFuse	Prosp	Polly, 2016 ¹³	102	24	1	0	0	0	0	1	0	0	0	0
	iFuse	Retro	Rudolf, 2014 ²⁶	17	60	0	0	0	0	0	0	0	0	0	1
	iFuse	Prosp	Whang, 2019 ²⁷	103	60	0	0	0	0	0	0	0	0	0	0
	iFuse	Retro	Amer, 2022 ²⁸	20	20	2	0	0	0	0	0	0	0	0	0
	iFuse	Retro	Bejjk, 2021 ²⁹	16	36	1	0	0	0	0	0	0	0	0	0
	iFuse	Retro	Claus, 2020 ^{30a}	82	12	0	0	0	0	0	2	0	0	0	0
	iFuse	Retro	Cleveland, 2019 ³¹	57	9	0	0	0	0	0	0	0	0	0	1
	iFuse	Retro	Gaetani, 2013 ³²	12	10	0	0	0	0	0	0	0	0	0	0
	iFuse	Retro	Graham-Smith, 2013 ³³	113	24	3	0	0	0	0	0	0	0	0	0
	iFuse	Retro	Hermans, 2022 ³⁴	29	12	0	0	0	0	0	0	0	0	0	0
	iFuse	Retro	Kasapovic, 2021 ³⁵	26	48	0	0	0	0	0	0	0	0	0	0
	iFuse	Retro	Kurosawa, 2022 ³⁶	5	36	0	0	0	0	0	0	0	0	0	0
	iFuse	Retro	Ledonio, 2014 ³⁷	17	12	1	0	0	0	0	0	0	0	0	1
	iFuse	Retro	Ledonio, 2014 ³⁸	22	14	0	0	0	0	0	2	0	0	0	0
	iFuse	Retro	Rainov, 2018 ³⁹	160	7	0	0	0	0	0	0	0	0	0	0
	iFuse	Retro	Rudolf, 2012 ⁴⁰	50	24	3	0	0	0	0	0	0	0	0	0
	iFuse	Retro	Sachs, 2012 ⁴¹	11	12	0	0	0	0	0	0	0	0	0	0
	iFuse	Retro	Sachs, 2013 ⁴²	40	12	0	0	0	0	0	0	0	0	0	0
	iFuse	Retro	Sachs, 2014 ⁴³	144	16	1	0	0	0	0	0	0	0	0	0
	iFuse	Retro	Sachs, 2016 ⁴⁴	107	44	1	0	0	0	0	2	0	0	0	0
	iFuse	Retro	Schmidt, 2020 ⁴⁵	19	58	0	0	0	0	0	0	0	0	0	0
	iFuse	Retro	Schroeder, 2013 ⁴⁶	6	10	0	0	0	0	0	0	0	0	0	0
	iFuse	Retro	Soliman, 2022 ⁴⁷	33	44	0	0	0	0	0	0	0	0	0	0
	iFuse	Retro	Vanaelchea, 2017 ⁴⁸	27	41	0	0	0	0	0	0	0	0	0	0
iFuse	Retro	Wessel, 2022 ⁴⁹	45	12	0	0	0	0	0	0	0	0	0	0	
iFuse	Retro	Kancherla, 2017 ⁵⁰	36	7	1	0	0	0	0	0	0	0	0	0	
Samba	Retro	Kancherla, 2017 ⁵⁰	9	7	2	0	0	0	0	0	0	0	0	0	
SI-LOK	Prosp	Rappoport, 2017/2021 ^{51,52}	32	24	0	0	0	0	0	0	0	0	0	0	
SI-LOK	Retro	Wales, 2020 ⁵³	40	12	0	0	0	0	0	4	0	0	0	0	
Simmetry	Prosp	Araghi, 2017 ⁵⁴	50	6	1	0	0	0	0	0	0	0	0	0	
Simmetry	Retro	Cross, 2018 ⁵⁵	19	24	0	0	0	0	0	0	0	0	0	0	
Simmetry	Prosp	Kucharczyk, 2022 ⁵⁶	201	12	0	0	0	0	0	0	0	0	0	0	
Simmetry	Retro	Kube, 2016 ⁵⁷	18	12	0	0	0	0	0	0	0	0	0	0	
Simmetry	Retro	Kasapovic, 2022 ⁵⁸	15	6	0	0	0	0	0	0	0	0	0	0	
Simmetry, Corelink, and Lnk	Retro	Abbasi, 2021 ⁵⁹	62	12	0	0	0	0	0	0	0	0	0	0	
Posterolateral transiliac	Rialto	Retro	Claus, 2020 ³⁰	74	12	0	0	0	0	6	0	0	0	0	
	Rialto	Retro	Rajpal, 2018 ⁶⁰	24	19	0	0	0	0	0	0	0	0	0	
	Rialto	Retro	Sarkar, 2022 ⁶¹	24	13	0	0	0	0	0	0	0	0	0	
	Sacrofuse	Retro	Chin, 2021 ⁶²	3	24	0	0	0	0	0	0	0	0	0	
	SI-LOK	Retro	Chaves, 2022 ⁶³	36	13	0	0	0	0	0	0	0	0	0	
	SI-LOK	Retro	Sarkar, 2022 ⁶¹	19	13	0	0	0	0	1	0	0	0	0	
	DIANA	Retro	Endres, 2013 ⁶⁴	19	13	0	0	0	0	0	0	0	0	0	
	DIANA	Prosp	Fuchs, 2018 ⁶⁵	171	24	4	0	0	0	3	0	0	0	0	
	LIHQ	Prosp	Calodney, 2022 ⁶⁶	69	6	0	NR	NR	NR	NR	NR	NR	NR	NR	
	LIHQ	Retro	Deer, 2021 ⁶⁷	111	3	NR	NR	NR	NR	NR	NR	NR	NR	NR	
	LIHQ	Retro	Sayed, 2021 ⁶⁸	50	12	0	0	0	0	0	0	0	0	0	
	LIHQ	Retro	Sayed, 2022 ⁶⁹	7	10	NR	NR	NR	NR	NR	NR	NR	NR	NR	
	Threaded cage	Prosp	Wise, 2008 ⁷⁰	13	30	0	0	0	0	1	0	0	0	0	

Abbreviations: HMA, hollow modular anchor; NR, not reported; Prosp, prospective study; Retro, retrospective study.
^aLateral cohort.

Table 5. Summary of available studies for safety outcomes.

Procedure	Device	Cohorts	Patients
Posterior interpositional	DIANA	2	190
	LINQ	4	237
	PSiF	1	57
	Threaded cage	1	13
	Total	8	497
Lateral transiliac	Hollow modular anchor screw	3	79
	iFuse	32	1637
	Samba	1	9
	SI-LOK	3	157
	Simmetry	4	288
	Torpedo	1	15
	Various	2	101
	Simmetry, Corelink, and Lnk	1	62
	Total	47	2348
	Posterolateral transiliac	Rialto	4
Posterolateral transiliac	Sacrix	1	19
	Sacrofuse	1	3
	SI-LOK	2	55
	Total	8	317
All	Total	63	3162

System was the most commonly reported device used (32 cohorts and 1637 patients). The PLTI procedure was reported in 8 cohorts (317 patients). The PI procedure (with placement of structural allograft[s] or metallic implants) was reported in 8 cohorts (497 patients).

The rate of selected safety outcomes is shown in Table 6. Acute implant malposition was reported in 0.43% of patients undergoing placement of devices in the LTI procedure, 0% in the PLTI procedure, and 0.2% in the PI procedure. In the PI procedure, malposition was reported for a metallic device but not for structural allografts (though radiographic assessment was not performed in any PI allograft study).⁶⁵ Several outcomes were not reported in any study (fracture, dislodgment of bone into the foramen, implant breakage, or bowel perforation). Bleeding requiring surgery was reported in 6 LTI studies (1 patient each, meta-analytic rate of 0.039% [95% CI 0%–0.163%]) but not in any PLTI or PI report. Device removal for pain was reported for all procedures (rates of 0.06% for LTI, 1.1% for PLTI, and 0.48% for PI). Wound infections were reported in LTI studies only (rate of 0.15%).

Table 6. Meta-analytic summary of safety outcomes.

Outcome	Lateral Transiliac			Posterolateral Transiliac			Posterior Interpositional		
	PE	LCL	UCL	PE	LCL	UCL	PE	LCL	UCL
Acute symptomatic malposition	0.429	0.156	0.836	0.000	0.000	0.303	0.2	0.000	1.42
Breakage	0.000	0.000	0.041	0.000	0.000	0.303	0.000	0.000	0.253
Migration	0.000	0.000	0.041	0.000	0.000	0.303	0.035	0.000	0.476
Bowel perforation	0.000	0.000	0.043	0.000	0.000	0.303	0.00	0.000	0.253
Removal for pain	0.059	0.002	0.199	1.11	0.000	3.83	0.48	0.000	1.72
Dislodgment of bone	0.001	0.000	0.054	0.000	0.000	0.303	0.000	0.000	0.253
Fracture	0.002	0.000	0.063	0.000	0.000	0.303	0.000	0.000	0.253
Wound infection	0.145	0.015	0.408	0.000	0.000	0.303	0.000	0.000	0.253
Bleeding requiring surgery	0.039	0.000	0.163	0.000	0.000	0.303	0.000	0.000	0.253

Abbreviations: LCL, lower 95% confidence limit; PE, point estimate; UCL, upper 95% confidence limit.

Including all studies, meta-regression showed that study design (prospective vs retrospective) did not statistically significantly impact safety outcome estimates. Similarly, study design did not have any effect on safety estimates within LTI studies. Meta-regression was not done for PLTI and PI studies due to the small number of reports.

Within LTI studies, meta-regression showed that device type was significantly associated with 2 of 9 safety outcomes. Acute malposition occurred more commonly with the Samba screw (2/9 cases in one study,⁵⁰ $\chi^2 P < 0.0001$). Late removal due to pain occurred more commonly with SI-LOK (4/157 cases, 2.5%, $\chi^2 P = 0.0165$); this result was driven by a single study⁵³ reporting 4 removals in 40 patients. Analysis across device types was not performed for PI and PLTI studies due to the low number of cohorts.

DISCUSSION

Evidence for the safety and efficacy of minimally invasive SI joint fusion has grown substantially over the past decade. Multiple procedural approaches are now available, including LTI, PLTI, and PI (less common). However, previous meta-analyses have not distinguished outcomes by procedure type. This distinction is key as the procedural approaches differ in their approach to acute and long-term stabilization and fusion of the complex SI joint. Thus, the clinical outcomes and safety data for the different procedures should not be generalized; they are fundamentally different. These fundamental differences have been recognized by the AMA, resulting in separate CPT codes to describe the procedures.

The evidence base for minimally invasive SI joint fusion is fairly large. However, the great majority of published evidence involves the LTI procedure. The LTI procedure was based, in part, on previous reports of percutaneous screw fixation for sacral fractures as well as early results of an identical procedure for the treatment

of chronic SI joint pain. Within the LTI procedure, the most commonly reported device (constituting approximately 3 quarters of all LTI patients reported) was triangular titanium implants (iFuse Implant System, SI-BONE). The evidence base for PLTI and PI procedures (7.6% and 15.2% of all patients with follow-up pain scores) was far less.

Our results generally suggest that minimally invasive SI joint fusion provides high levels of pain relief and disability improvement (as reflected by improvements in ODI) along with a reasonable safety profile. Of note, no cohort showed mean worsening of pain and/or disability. Meta-regression provided evidence to suggest that improvements in pain and disability were highest in LTI procedures and lower in the other procedures. In the PLTI procedure, implants are placed obliquely across the SI joint axis of rotation. A biomechanical study showed that this approach provided less stability compared with placement of implants parallel to the axis of rotation (as done with the LTI procedure).⁷¹ This decreased stability may be due in part to less bony engagement in the sacrum and implant termination point in the sacral ala vs nearer the sacral body. Moreover, because implants placed in the PLTI trajectory traverse the ligamentous portion of the joint, bone surfaces may be separated by several millimeters of ligamentous tissue, which is not conducive to new bone formation.⁷² In a comparative study, PLTI procedures had a higher incidence of persistent SI joint pain with radiographic evidence of lucency and nonunion compared with LTI.³⁰

LTI procedures also appeared to show superior efficacy (pain and ODI response) compared with PI procedures. The PI procedure relies on DA, namely stabilization of the SI joint through ligamentotaxis achieved by distracting the joint with an implant. DA was previously used in the lumbar spine, but the technique is now rarely used due to substantial rates of implant subsidence, low rates of permanent fusion, and poor overall responses.⁷³⁻⁷⁵ Rather, current practices in the lumbar spine involve full preparation of the disc space with complete removal of disc material, preparation of the endplate, and stabilization of the motion segment with rigid anterior and/or posterior instrumentation. In the SI joint, DA with metallic devices was successful at achieving fusion only when the joint was thoroughly prepared and augmented with off-label use of rh-BMP.^{64,65} In early PI studies using metallic implants, the rate of poor implant position was high (5/19⁶⁴ and “large percentage”).⁶⁵ Also note that DA of the SI joint relies on accurate intra-articular placement of implants; a recent case series suggests a high rate of structural allograft placements outside the joint with consequent lack of joint fusion.⁷⁶

The rates of some events (major bleeding and symptomatic implant malposition) have been called into question, especially for the LTI procedure.⁷⁷ Our results suggest that event rates are low across all procedures, including the LTI. Implant malposition causing symptoms resulting from inadvertent nerve root irritation is more likely in the LTI procedure compared with other procedures as implants are directed toward the sacral foramina. However, the rate of this outcome was low in the LTI procedure (0.43%). This rate is consistent with postmarket surveillance reported by the manufacturer,^{78,79} including a decrease in rate over time.⁷⁹ This rate is also consistent with the reported symptomatic malposition/revision rate for pedicle screws during lumbar fusion placed freehand (0.8%–3.25%).^{80,81} The rate of implant malposition varied across LTI device types, but this finding was driven by only 2 studies. Symptomatic malposition was reported in some PI procedure studies but no PLTI procedure studies. Direct comparisons of adverse event rates across procedures are generally not available. A single-center retrospective comparison of LTI and PLTI procedures published in an abstract only suggests a lower rate of adverse events with the PLTI approach.⁸² Detailed analyses of revision rates (mostly for implant malposition) have been reported for triangular implants only.^{78,79} Information on implant location in SI joint fusion procedures has not been fully evaluated. Symptom recurrence with implant malposition after PI procedures (allografts) has been reported.⁷⁶

The rates of other outcomes (implant removal, dislodgment of bone fragments into the sacral foramina, fracture, wound infection, and bleeding requiring surgery) were low in all groups. The rate of LTI implant removal varied across device types, but these results were driven by a small number of studies. No study reported breakage or migration of implants. In studies of the PI procedure using structural allograft, follow-up radiographic assessment was not performed. This prevents assessment of migration, subsidence, fracture of the structural allograft, or fusion status.

Implants for SI joint fusion are likely effective only if placed accurately in the target location. Placement accuracy as assessed by implant engagement length into the sacrum was reported in one LTI study.¹⁴ Placement accuracy was indirectly assessed in other LTI studies of the iFuse Implant System through independent radiographic analysis of fusion outcomes.²⁷ No other studies reported implant

placement accuracy. Inaccurate placement of structural allografts leading to revision surgeries has been reported.⁷⁶ To our knowledge, prospective studies of PI allograft placement have not included radiographic assessment. Only studies of iFuse implants have used independent radiologists for assessment.

Other than for some LTI devices, published studies of SI joint fusion have not extensively evaluated radiographic joint fusion. Whang et al reported high joint fusion rates (88%) for iFuse implants based on independent radiographic analysis.²⁷ Some studies reported high joint fusion rates but without independent assessment.^{55,62} Other studies reported “probable fusion” on the basis of clinical findings (absence of loosening on x-ray plus symptom improvement).⁵¹ As noted above, some studies excluded all radiographic assessment, including fusion.⁶⁶ There appears to be no consensus on the definition of fusion of the SI joint. Successful fusion of the lumbar spine appears to predict increased improvement in pain and disability scores.⁸³ The rate of SI joint fusion across procedures, as well as the correlation between SI joint fusion and symptom relief, remains under-explored.

Overall literature quality was moderate. A minority of included cohorts were prospective, that is, a higher level of study design. Most studies were retrospective case series. No prospective studies were available for the PLTI procedure. Only LTI included randomized trials. Except for one peer-reviewed cohort showing no differences between an LTI and a PLTI procedure,³⁰ prospective comparative data are not available.

Of interest is the difference between metallic devices and structural allografts. Whether head-to-head studies need to be executed is a matter of discussion.

Detailed per-study information was not sufficient to determine with confidence whether pooling results across studies was reasonable. However, it appears that the same diagnostic algorithm was used for diagnosis in most studies (history, physical examination with the use of 3 or more physical examination tests that provoke typical pain near the PSIS, and diagnostic intra-articular SI joint block using a small amount of local anesthetic). Moreover, all studies showed improvement in one or both efficacy parameters (pain and ODI), and all studies showed low overall adverse event rates, suggesting the observation of similar phenomena across studies. Funnel plots showed no systematic bias.

Other aspects of SI joint fusion procedures remain underexamined. For example, cost-effectiveness has been estimated only for triangular titanium implants.⁸⁴ Opioid consumption is reported in a minority of studies (not reviewed further here) with variable results (some showing reduced opioid use²⁵ and others showing no reduction⁴⁹).

CONCLUSIONS

Substantial literature supports the safety and effectiveness of minimally invasive SI joint fusion. The evidence base for the LTI procedure is largest and of the highest quality. However, only one implant (iFuse) has level 1 evidence and independent radiographic assessment of joint fusion. Studies reporting outcomes with the LTI procedure show larger improvements in pain and disability compared with those on PLTI or PI procedures. All procedures appeared to have low rates of safety outcomes; direct comparisons are not available; such studies are potentially limited by event rarity. Outstanding issues for PLTI and PI procedures include implant placement accuracy, fusion rates, and impact on opioid use. No information is available for devices placed posteriorly that span the joint.

REFERENCES

1. Sembrano JN, Polly DW. How often is low back pain not coming from the back? *Spine (Phila Pa 1976)*. 2009;34(1):E27–E32. doi:10.1097/BRS.0b013e31818b8882
2. Bernard T. The role of the sacroiliac joints in low back pain: basic aspects of pathophysiology, and management. In: *Movement, Stability, and Low Back Pain: The Essential Role of the Pelvis*. New York: Churchill Livingstone; 1997:73–88.
3. Liliang P-C, Lu K, Liang C-L, Tsai Y-D, Wang K-W, Chen H-J. Sacroiliac joint pain after lumbar and lumbosacral fusion: findings using dual sacroiliac joint blocks. *Pain Med*. 2011;12(4):565–570. doi:10.1111/j.1526-4637.2011.01087.x
4. Painter CF. Excision of the os innominatum. Arthrodesis of the sacro-iliac synchondrosis. *The Boston Medical and Surgical Journal*. 1908;159(7):205–208. doi:10.1056/NEJM190808131590703
5. Stark JG, Fuentes JA, Fuentes TI, Idemmili C. The history of sacroiliac joint arthrodesis: a critical review and introduction of a new technique. *Curr Orthop Pract*. 2011;22(6):545–547. doi:10.1097/BCO.0b013e31823563d3
6. Buchowski JM, Kebaish KM, Sinkov V, Cohen DB, Sieber AN, Kostuik JP. Functional and radiographic outcome of sacroiliac arthrodesis for the disorders of the sacroiliac joint. *Spine J*. 2005;5(5):520–528. doi:10.1016/j.spinee.2005.02.022
7. Chip Routt ML, Meier MC, Kregor PJ, Mayo KA. Percutaneous iliosacral screws with the patient supine technique. *Operative Techniques in Orthopaedics*. 1993;3(1):35–45. doi:10.1016/S1048-6666(06)80007-8

8. Peretz AM, Hipp JA, Heggeness MH. The internal bony architecture of the sacrum. *Spine (Phila Pa 1976)*. 1998;23(9):971–974. doi:10.1097/00007632-199805010-00001
9. Richards AM, Coleman NW, Knight TA, Belkoff SM, Mears SC. Bone density and cortical thickness in normal, osteopenic, and osteoporotic sacra. *J Osteoporos*. 2010;2010:504078. doi:10.4061/2010/504078
10. Lindsey DP, Perez-Orribo L, Rodriguez-Martinez N, et al. Evaluation of a minimally invasive procedure for sacroiliac joint fusion - an in vitro biomechanical analysis of initial and cycled properties. *Med Devices (Auckl)*. 2014;7:131–137. doi:10.2147/MDER.S63499
11. Lindsey DP, Kiapour A, Yerby SA, Goel VK. Sacroiliac joint fusion minimally affects adjacent lumbar segment motion: a finite element study. *Int J Spine Surg*. 2015;9:64. doi:10.14444/2064
12. Soriano-Baron H, Lindsey DP, Rodriguez-Martinez N, et al. The effect of implant placement on sacroiliac joint range of motion: posterior versus transarticular. *Spine (Phila Pa 1976)*. 2015;40(9):E525–E530. doi:10.1097/BRS.0000000000000839
13. Polly DW, Swofford J, Whang PG, et al. Two-year outcomes from a randomized controlled trial of minimally invasive sacroiliac joint fusion vs. non-surgical management for sacroiliac joint dysfunction. *Int J Spine Surg*. 2016;10:28. doi:10.14444/3028
14. Dengler J, Kools D, Pflugmacher R, et al. Randomized trial of sacroiliac joint arthrodesis compared with conservative management for chronic low back pain attributed to the sacroiliac joint. *J Bone Joint Surg Am*. 2019;101(5):400–411. doi:10.2106/JBJS.18.00022
15. Duhon BS, Bitan F, Lockstadt H, et al. Triangular titanium implants for minimally invasive sacroiliac joint fusion: 2-year follow-up from a prospective multicenter trial. *Int J Spine Surg*. 2016;10:13. doi:10.14444/3013
16. Beck CE, Jacobson S, Thomasson E. A retrospective outcomes study of 20 sacroiliac joint fusion patients. *Cureus*. 2015;7(4):e260. doi:10.7759/cureus.260
17. Viechtbauer W. Conducting meta-analyses in R with the metafor package. *J Stat Softw*. 2010;36(3):1–48. doi:10.18637/jss.v036.i03
18. Kurosawa D, Murakami E, Aizawa T, Watanabe T. Surgical outcomes of patients with sacroiliac joint pain: an analysis of patients with poor results regarding activities of daily living. *Spine Surg Relat Res*. 2021;5(3):189–195. doi:10.22603/ssrr.2020-0214
19. Al-Khayer A, Hegarty J, Hahn D, Grevitt MP. Percutaneous sacroiliac joint arthrodesis: a novel technique. *J Spinal Disord Tech*. 2008;21(5):359–363. doi:10.1097/BSD.0b013e318145ab96
20. Mason LW, Chopra I, Mohanty K. The percutaneous stabilization of the sacroiliac joint with hollow modular anchorage screws: a prospective outcome study. *Eur Spine J*. 2013;22(10):2325–2331. doi:10.1007/s00586-013-2825-2
21. Khurana A, Guha AR, Mohanty K, Ahuja S. Percutaneous fusion of the sacroiliac joint with hollow modular anchorage screws: clinical and radiological outcome. *J Bone Joint Surg Br*. 2009;91(5):627–631. doi:10.1302/0301-620X.91B5.21519
22. Bornemann R, Roessler PP, Strauss AC, et al. Two-year clinical results of patients with sacroiliac joint syndrome treated by arthrodesis using a triangular implant system. *Technol Health Care*. 2017;25(2):319–325. doi:10.3233/THC-161272
23. Cummings J, Capobianco RA. Minimally invasive sacroiliac joint fusion: one-year outcomes in 18 patients. *Ann Surg Innov Res*. 2013;7(1):12. doi:10.1186/1750-1164-7-12
24. Novák V, Wanek T, Hrabálek L, Stejskal P. Minimally invasive sacroiliac joint stabilization. *Acta Chir Orthop Traumatol Cech*. 2021;88(1):35–38.
25. Patel V, Kovalsky D, Meyer SC, et al. Prospective trial of sacroiliac joint fusion using 3D-printed triangular titanium implants. *Med Devices (Auckl)*. 2020;13:173–182. doi:10.2147/MDER.S253741
26. Rudolf L, Capobianco R. Five-year clinical and radiographic outcomes after minimally invasive sacroiliac joint fusion using triangular implants. *Open Orthop J*. 2014;8:375–383. doi:10.2174/1874325001408010375
27. Whang PG, Darr E, Meyer SC, et al. Long-term prospective clinical and radiographic outcomes after minimally invasive lateral transiliac sacroiliac joint fusion using triangular titanium implants. *Med Devices (Auckl)*. 2019;12:411–422. doi:10.2147/MDER.S219862
28. Amer MH, Elnahal WA, Khaled SA, et al. Minimally invasive sacroiliac fusion, a case series, and a literature review. *SICOT J*. 2022;8:42. doi:10.1051/sicotj/2022042
29. Beijik I, Knoef R, van Vugt A, Verra W, Nellensteijn J. Sacroiliac joint fusion in patients with ehlers danlos syndrome: a case series. *N Am Spine Soc J*. 2021;8:100082. doi:10.1016/j.xnsj.2021.100082
30. Claus CF, Lytle E, Kaufmann A, et al. Minimally invasive sacroiliac joint fusion using triangular titanium versus cylindrical threaded implants: a comparison of patient-reported outcomes. *World Neurosurg*. 2020;133:e745–e750. doi:10.1016/j.wneu.2019.09.150
31. Cleveland AW, Nhan DT, Akiyama M, Kleck CJ, Noshchenko A, Patel VV. Mini-open sacroiliac joint fusion with direct bone grafting and minimally invasive fixation using intraoperative navigation. *J Spine Surg*. 2019;5(1):31–37. doi:10.21037/jss.2019.01.04
32. Gaetani P, Miotti D, Risso A, et al. Percutaneous arthrodesis of sacro-iliac joint: a pilot study. *J Neurosurg Sci*. 2013;57(4):297–301.
33. Smith AG, Capobianco R, Cher D, et al. Open versus minimally invasive sacroiliac joint fusion: a multi-center comparison of perioperative measures and clinical outcomes. *Ann Surg Innov Res*. 2013;7(1):14. doi:10.1186/1750-1164-7-14
34. Hermans SMM, Knoef RJH, Schuermans VNE, et al. Double-center observational study of minimally invasive sacroiliac joint fusion for sacroiliac joint dysfunction: one-year results. *J Orthop Surg Res*. 2022;17(1):570. doi:10.1186/s13018-022-03466-x
35. Kasapovic A, Ali T, Jaenisch M, et al. Minimally invasive arthrodesis of the sacroiliac joint (SIJ). *Oper Orthopädie Traumatol*. 2021.
36. Kurosawa D, Murakami E, Koga H, Ozawa H. Three-year clinical outcomes after minimally invasive sacroiliac joint arthrodesis using triangular implants in Japan: a pilot study of five cases. *Spine Surg Relat Res*. 2022;6(1):71–78. doi:10.22603/ssrr.2021-0028
37. Ledonio CGT, Polly DW, Swiontkowski M. Minimally invasive versus open sacroiliac joint fusion: a comparison of outcomes in propensity matched cohorts. *Spine J*. 2014.
38. Ledonio CGT, Polly DW, Swiontkowski MF, Cummings JT. Comparative effectiveness of open versus minimally invasive sacroiliac joint fusion [Internet]. *Med Devices Evid Res*. 2014. <http://www.dovepress.com/getfile.php?fileID=20329>.
39. Rainov NG, Schneiderhan R, Heidecke V. Triangular titanium implants for sacroiliac joint fusion. *Eur Spine J*. 2018.

40. Rudolf L. Sacroiliac joint arthrodesis-MIS technique with titanium implants: report of the first 50 patients and outcomes. *Open Orthop J.* 2012;6:495–502. doi:10.2174/1874325001206010495
41. Sachs D, Capobianco R. One year successful outcomes for novel sacroiliac joint arthrodesis system. *Ann Surg Innov Res.* 2012;6(1):13. doi:10.1186/1750-1164-6-13
42. Sachs D, Capobianco R. Minimally invasive sacroiliac joint fusion: one-year outcomes in 40 patients. *Adv Orthop.* 2013;2013:536128. doi:10.1155/2013/536128
43. Sachs D, Capobianco R, Cher D, et al. One-year outcomes after minimally invasive sacroiliac joint fusion with a series of triangular implants: a multicenter, patient-level analysis [Internet]. *Med Devices Evid Res.* 2014. <http://www.dovepress.com/getfile.php?fileID=21392>.
44. Sachs D, Kovalsky D, Redmond A, et al. Durable intermediate-to long-term outcomes after minimally invasive transiliac sacroiliac joint fusion using triangular titanium implants. *Med Devices (Auckl).* 2016;9:213–222. doi:10.2147/MDER.S109276
45. L Schmidt G, Bologna M, Schorr R. Patient reported clinical outcomes of minimally invasive sacroiliac joint arthrodesis. *Orthop Surg.* 2021;13(1):71–76. doi:10.1111/os.12832
46. Schroeder JE, Cunningham ME, Ross T, Boachie-Adjei O. Early results of sacro-iliac joint fixation following long fusion to the sacrum in adult spine deformity. *HSS J.* 2014;10(1):30–35. doi:10.1007/s11420-013-9374-4
47. Soliman O, Pflugmacher R, Koch EM, et al. One-year results of minimally invasive fusion surgery of the sacroiliac joint as an alternative treatment after failed endoscopic thermal coagulation. *Technol Health Care.* 2022;30(5):1125–1138. doi:10.3233/THC-213183
48. Vanaclocha V, Herrera JM, Sáiz-Sapena N, Rivera-Paz M, Verdú-López F. Minimally invasive sacroiliac joint fusion, radiofrequency denervation, and conservative management for sacroiliac joint pain: 6-year comparative case series. *Neurosurgery.* 2018;82(1):48–55. doi:10.1093/neuros/nyx185
49. Wessell NM, Wolverton E, Ross P, Akiyama M, Lindley E, Patel V. Opioid prescription monitoring in preoperative and postoperative sacroiliac joint fusion patients. *Int J Spine Surg.* 2022;16(3):498–504. doi:10.14444/8240
50. Kancherla VK, McGowan SM, Audley BN, Sokunbi G, Puccio ST. Patient reported outcomes from sacroiliac joint fusion. *Asian Spine J.* 2017;11(1):120–126. doi:10.4184/asj.2017.11.1.120
51. Rappoport LH, Luna IY, Joshua G. Minimally invasive sacroiliac joint fusion using a novel hydroxyapatite-coated screw: preliminary 1-year clinical and radiographic results of a 2-year prospective study. *World Neurosurg.* 2017;101:493–497. doi:10.1016/j.wneu.2017.02.046
52. Rappoport LH, Helsper K, Shirk T. Minimally invasive sacroiliac joint fusion using a novel hydroxyapatite-coated screw: final 2-year clinical and radiographic results. *J Spine Surg.* 2021;7(2):155–161. doi:10.21037/jss-20-627
53. Wales E, Agarwal R, Mohanty K. Are hydroxyapatite-coated screws a good option for sacroiliac joint stabilization? A prospective outcome study. *World Neurosurg.* 2021;148:e164–e171. doi:10.1016/j.wneu.2020.12.104
54. Araghi A, Woodruff R, Colle K, et al. Pain and opioid use outcomes following minimally invasive sacroiliac joint fusion with decortication and bone grafting: the evolution clinical trial. *Open Orthop J.* 2017;11(1):1440–1448. doi:10.2174/1874325001711011440
55. Cross WW, Delbridge A, Hales D, Fielding LC. Minimally invasive sacroiliac joint fusion: 2-year radiographic and clinical outcomes with a principles-based SIJ fusion system. *Open Orthop J.* 2018;12:7–16. doi:10.2174/1874325001812010007
56. Kucharzyk D, Colle K, Boone C, Araghi A. Clinical outcomes following minimally invasive sacroiliac joint fusion with decortication: the evolution clinical study. *Int J Spine Surg.* 2022;16(1):168–175. doi:10.14444/8185
57. Kube RA, Muir JM. Sacroiliac joint fusion: one year clinical and radiographic results following minimally invasive sacroiliac joint fusion surgery. *Open Orthop J.* 2016;10:679–689. doi:10.2174/1874325001610010679
58. Kasapovic A, Ali T, Jaenisch M, et al. Minimally invasive arthrodesis of the sacroiliac joint (SIJ). *Oper Orthop Traumatol.* 2022;34(2):98–108. doi:10.1007/s00064-021-00738-3
59. Abbasi H, Storlie N, Rusten M. Perioperative outcomes of minimally invasive sacroiliac joint fusion using hollow screws through a lateral approach: a single surgeon retrospective cohort study. *Cureus.* 2021;13(7):e16517. doi:10.7759/cureus.16517
60. Rajpal S, Burneikiene S. Minimally invasive sacroiliac joint fusion with cylindrical threaded implants using intraoperative stereotactic navigation. *World Neurosurgery.* 2019;122:e1588–e1591. doi:10.1016/j.wneu.2018.11.116
61. Sarkar M, Maalouly J, Ruparel S, Choi J. Sacroiliac joint fusion: fusion rates and clinical improvement using minimally invasive approach and intraoperative navigation and robotic guidance. *Asian Spine J.* 2022;16(6):882–889. doi:10.31616/asj.2021.0058
62. Chin KR, Pencle FJ, Seale JA, Pandey DK. CT scan and clinical outcomes of novel lateral-oblique percutaneous sacroiliac joint (SIJ) fixation: technique and literature review. *Cureus.* 2021;13(7):e16408. doi:10.7759/cureus.16408
63. Chaves JPG, Maalouly J, Choi JYS. Clinical results following robotic navigation guidance for sacroiliac joint fusion in 36 patients. *Neurosurg Focus.* 2022;52(1):2021.10.FOCUS21523. doi:10.3171/2021.10.FOCUS21523
64. Endres S, Ludwig E. Outcome of distraction interference arthrodesis of the sacroiliac joint for sacroiliac arthritis. *Indian J Orthop.* 2013;47(5):437–442. doi:10.4103/0019-5413.118197
65. Fuchs V, Ruhl B. Distraction arthrodesis of the sacroiliac joint: 2-year results of a descriptive prospective multi-center cohort study in 171 patients. *Eur Spine J.* 2018;27(1):194–204. doi:10.1007/s00586-017-5313-2
66. Calodney AK, Azeem N, Buchanan P, et al. Six month interim outcomes from secure: a single arm, multicenter, prospective, clinical study on a novel minimally invasive posterior sacroiliac fusion device. *Expert Rev Med Devices.* 2022;19(5):451–461. doi:10.1080/17434440.2022.2090244
67. Deer TR, Rupp A, Budwany R, et al. Pain relief salvage with a novel minimally invasive posterior sacroiliac joint fusion device in patients with previously implanted pain devices and therapies. *J Pain Res.* 2021;14:2709–2715. doi:10.2147/JPR.S325059
68. Sayed D, Balter K, Pyles S, Lam CM. A multicenter retrospective analysis of the long-term efficacy and safety of a novel posterior sacroiliac fusion device. *J Pain Res.* 2021;14:3251–3258. doi:10.2147/JPR.S326827
69. Sayed D, Khatri N, Rupp A, et al. Salvage of failed lateral sacroiliac joint fusion with a novel posterior sacroiliac fusion device: diagnostic approach, surgical technique, and multicenter case series. *J Pain Res.* 2022;15:1411–1420. doi:10.2147/JPR.S357076

70. Wise CL, Dall BE. Minimally invasive sacroiliac arthrodesis: outcomes of a new technique. *J Spinal Disord Tech*. 2008;21(8):579–584. doi:10.1097/BSD.0b013e31815ecc4b
71. Bruna-Rosso C, Arnoux P-J, Bianco R-J, Godio-Rabouet Y, Fradet L, Aubin C-É. Finite element analysis of sacroiliac joint fixation under compression loads. *Int J Spine Surg*. 2016;10:16. doi:10.14444/3016
72. Payne C, Jaffee S, Swink I, et al. Comparative analysis of the lateral and posterolateral trajectories for fixation of the sacroiliac joint—a cadaveric study. *J Orthop Surg Res*. 2020;15(1):489. doi:10.1186/s13018-020-02013-w
73. Beutler WJ, Poppelman WC. Anterior lumbar fusion with paired BAK standard and paired BAK proximity cages: subsidence incidence, subsidence factors, and clinical outcome. *Spine J*. 2003;3(4):289–293. doi:10.1016/s1529-9430(03)00061-5
74. Button G, Gupta M, Barrett C, Cammack P, Benson D. Three- to six-year follow-up of stand-alone BAK cages implanted by a single surgeon. *Spine J*. 2005;5(2):155–160. doi:10.1016/j.spinee.2004.06.021
75. McAfee PC, Cunningham BW, Lee GA, et al. Revision strategies for salvaging or improving failed cylindrical cages. *Spine (Phila Pa 1976)*. 1999;24(20):2147–2153. doi:10.1097/00007632-199910150-00015
76. Kranenburg A, Garcia-Diaz G, Cook JH, et al. Revision of failed sacroiliac joint posterior interpositional structural allograft stabilization with lateral porous titanium implants: a multicenter case series. *Med Devices (Auckl)*. 2022;15:229–239. doi:10.2147/MDER.S369808
77. Rahl MD, Weistroffer J, Dall BE. Analysis of complications in sacroiliac joint fusions using FDA 510(K) cleared devices. *Clin Spine Surg*. 2022;35(3):E363–E367. doi:10.1097/BSD.0000000000001264
78. Cher D, Wroe K, Reckling WC, Yerby S. Postmarket surveillance of 3D-printed implants for sacroiliac joint fusion. *Med Devices (Auckl)*. 2018;11:337–343. doi:10.2147/MDER.S180958
79. Cher DJ, Reckling WC, Capobianco RA. Implant survivorship analysis after minimally invasive sacroiliac joint fusion using the iFuse implant system®. *Med Devices (Auckl)*. 2015;8:485–492. doi:10.2147/MDER.S94885
80. Parker SL, McGirt MJ, Farber SH, et al. Accuracy of free-hand pedicle screws in the thoracic and lumbar spine: analysis of 6816 consecutive screws. *Neurosurgery*. 2011;68(1):170–178. doi:10.1227/NEU.0b013e3181fdaf4
81. Caelers I, Rijkers K, van Kuijk SMJ, van Santbrink H, de Bie RA, van Hemert WLW. Neurological events due to pedicle screw malpositioning with lateral fluoroscopy-guided pedicle screw insertion. *J Neurosurg Spine*. 2020;33(6):806–811. doi:10.3171/2020.5.SPINE20550
82. MajdME. Wednesday September 26, 2018 1:00 PM – 2:00 PM what's new in MIS: 38. retrospective analysis of sacroiliac joint (SIJ) fusions comparing the percutaneous transgluteal approach to the posterior oblique approach. *Spine J*. 2018;18(8, Supplement):S18–S19. doi:10.1016/j.spinee.2018.06.047
83. Noshchenko A, Lindley EM, Burger EL, Cain CMJ, Patel VV. What is the clinical relevance of radiographic nonunion after single-level lumbar interbody arthrodesis in degenerative disc disease? A meta-analysis of the YODA project database. *Spine (Phila Pa 1976)*. 2016;41(1):9–17. doi:10.1097/BRS.0000000000001113
84. Cher DJ, Frasco MA, Arnold RJG, Polly DW. Cost-effectiveness of minimally invasive sacroiliac joint fusion. *Clinicoecon Outcomes Res*. 2016;8:1–14. doi:10.2147/CEOR.S94266
85. Heiney J, Capobianco R, Cher D. A systematic review of minimally invasive sacroiliac joint fusion utilizing a lateral transarticular technique. *Int J Spine Surg*. 2015;9:40. doi:10.14444/2040
86. Hermans SMM, Droeghaag R, Schotanus MGM, Santbrink H van, van Hemert WLW, Curfs I. Minimally invasive sacroiliac joint fusion vs conservative management in patients with sacroiliac joint dysfunction: a systematic review and meta-analysis. *Int J Spine Surg*. 2022;16(3):472–480. doi:10.14444/8241
87. Shamrock AG, Patel A, Alam M, Shamrock KH, Al Maaieh M. The safety profile of percutaneous minimally invasive sacroiliac joint fusion. *Global Spine J*. 2019;9(8):874–880. doi:10.1177/2192568218816981

Funding: The authors received no financial support for the research, authorship, and/or publication of this article.

Declaration of Conflicting Interests: Three authors are employees of a device manufacturer whose implant is included in the systematic review, 5 authors are consultants for various implant manufacturers included in this paper.

Disclosures: P.W. reports grants/contracts from Bioventus and OssDsign; consulting fees from SI-BONE, Bioventus, Boston Scientific, Medtronic, Orthofix, and Stryker; speakers bureau for SI-BONE, Medtronic, Orthofix, and Stryker; Advisory Boards for Centinel Spine, Cerapedics, Empirical Spine, NuVasive, Providence Medical Technologies, and OssDsign. V.P. reports consulting fees from DePuy Synthes, Mainstay Medical, Zimmer, Stryker, Medtronic, Aesculap, Spine Welding AG, Orthobond, J&J, Baxter, and SI-BONE, Inc. B.D. reports consulting from SI-BONE, Inc. and Intrinsic Therapeutics. B.S. reports consulting from SI-BONE and SRL. DC, CR, and RC are employees of SI-BONE, Inc. D.P. reports consulting from Globus, SI-BONE, and Alexion and royalties from SI-BONE.

Corresponding Author: Robyn Capobianco, SI-BONE, Inc., 471 El Camino Real, Suite 100, Santa Clara, CA 95050, USA; robyn.capobianco@si-bone.com

Published 03 October 2023

This manuscript is generously published free of charge by ISASS, the International Society for the Advancement of Spine Surgery. Copyright © 2023 ISASS. To see more or order reprints or permissions, see <http://ijssurgery.com>.