

Are We Finally Ready for Total Joint Replacement of the Spine? An Extension of Charnley's Vision

S. Craig Humphreys, Scott D. Hodges, J. Alex Sielatycki, Ahilan Sivaganesan and Jon E. Block

Int J Spine Surg 2024, 18 (1) 24-31

doi: <https://doi.org/10.14444/8538>

<http://ijssurgery.com/content/18/1/24>

This information is current as of April 27, 2024.

Email Alerts Receive free email-alerts when new articles cite this article. Sign up at:
<http://ijssurgery.com/alerts>

Are We Finally Ready for Total Joint Replacement of the Spine? An Extension of Charnley's Vision

S. CRAIG HUMPHREYS, MD¹; SCOTT D. HODGES, DO²; J. ALEX SIELATYCKI, MD³; AHILAN SIVAGANESAN, MD⁴; AND JON E. BLOCK, PhD⁵

¹Kenai Spine, Soldotna, AK, USA; ²Center for Sports Medicine and Orthopedics, Chattanooga, TN, USA; ³Steamboat Orthopedic and Spine Institute, Steamboat Springs, CO, USA; ⁴Thomas Jefferson University, Philadelphia, PA, USA; ⁵Independent Consultant, San Francisco, CA, USA

ABSTRACT

Professor Sir John Charnley has been rightfully hailed as a visionary innovator for conceiving, designing, and validating the *Operation of the Century*—the total hip arthroplasty. His groundbreaking achievement forever changed the orthopedic management of chronically painful and dysfunctional arthritic joints. However, the well-accepted surgical approach of completely removing the diseased joint and replacing it with a durable and anatomically based implant never translated to the treatment of the degenerated spine. Instead, decompression coupled with fusion evolved into the workhorse intervention. In this commentary, the authors explore the reasons why arthrodesis has remained the mainstay over arthroplasty in the field of spine surgery as well as discuss the potential shift in the paradigm when it comes to treating degenerative lumbar disease.

Novel Techniques & Technology

Keywords: stenosis, motion, joint replacement, lumbar, osteotomy

INTRODUCTION

Instantly recognizable, the S-shaped sagittal profile of the human spine has inspired both artistic representation and scientific inquiry with equal historical importance, fervor, and deference. A remarkable bio-architectural design, the human spine is a contiguous series of 24 individual motion segments, working in harmony to allow the upper body to move in 3 dimensions, a kinematic phenomenon unique to the axial skeleton.^{1,2} Each spinal motion segment consists of adjacent vertebrae and the intervening nonosseous joint elements, which include the intervertebral disc and 2 posterior facet joints, to facilitate the articulation between adjacent segments. This elegant design allows the segments to be stacked vertically, with each vertebra acting as a component of the motion segment both superiorly and inferiorly. The repetition of motion segments, combined with the overlying muscular envelope, allows for powerful, coordinated, and instinctual motions throughout the vertebral column that provide the functional flexibility and efficiency necessary for daily activities.

Paradoxically, the curved and flexible spinal column is an adaptive anatomical feature not present at birth where the spine is C-shaped from being in utero.³ Cervical lordosis originates at 3 months, when the infant begins consistently lifting their head, and lumbar lordosis develops by 9 months, consistent with the initiation of sitting and standing maneuvers. As infants mature

to toddlers and begin to ambulate in a bipedal fashion with habitual orthograde posture, the spine adapts and assumes its classic serpentine configuration of natural kyphosis and lordosis to accommodate this transformation from crawling to walking.

Unfortunately, while upright bipedalism is a remarkable and defining human characteristic, it has the adverse impact of placing the body in a distinctly unfavorable biomechanical and functional position.⁴ Orthograde ambulation, and transitioning from standing to sitting, produce unusually high axial compressive loads that are consequential in the development and progression of age-related arthritic degeneration of the large synovial joints of the lower appendicular skeleton as well as the spine.^{5,6} The degenerative effects of axial loading are experienced particularly profoundly in the lumbar spine, where radiographic features of osseoligamentous deterioration are nearly ubiquitous among elderly adults, the end-product of decades of compressive forces acting on the vertebral column.^{7–11}

No portion of the spinal motion segment's 3-joint complex is spared by the age-related degenerative spondylosis caused by repetitive axial loading.^{10,12–15} Consequently, the degenerated spine exhibits a mosaic of pathoanatomical features, including classic synovial joint osteoarthritis of the facet joints^{16–19} coupled with more widespread osseoligamentous deterioration.²⁰ This includes disc degeneration with neural

impingement, ligamentum flavum hypertrophy, and buckling, as well as osteophyte and spur formation causing central canal, lateral recess, and/or foraminal stenosis.^{7,21-23} In fact, there has been a growing appreciation of the biomechanical interdependence of degeneration across the 3-joint complex, with disc degeneration and facet arthrosis typically occurring in tandem with considerable pathophysiological overlap.²⁴ The optimal treatment of the degenerated spine remains elusive, but the solution may be to appreciate, emulate, and adopt the surgical methods and approaches proven to be successful in other degenerative joint conditions. These newer treatments tend to mimic normal anatomy and thus provide more natural motions.

THE EVOLUTION OF ARTHRODESIS TO ARTHROPLASTY

Entire tomes have been expertly authored that detail the extraordinary life and scientific accomplishments of Professor Sir John Charnley, including the classic biography *John Charnley: The Man and the Hip*, by William Waugh.²⁵⁻³⁴ Among all the well-deserved accolades, there has been perhaps no higher praise for Charnley's revolutionary invention of total hip arthroplasty (THA) than offered by T.G. Thomas in his poignant review of Waugh's book, asserting that THA "has resulted in a glorious Indian summer for millions of arthritis sufferers."³⁵ The safety, effectiveness, and durability of the surgery have been so uniformly accepted in the medical community that it has been coined "The Operation of the Century"—not simply in orthopedics but in all realms of surgery.³²

Prior to the advent of THA, arthrodesis was a surgical option for managing severely degenerated arthritic joints by stabilizing the joint to reduce pain, but the functional outcomes were extremely poor. As the largest and simplest synovial joint, with its ball-and-socket configuration, the hip was considered as a living laboratory for the development of an approach that replaced a destroyed or malfunctioning joint as opposed to fusing it.³³ This approach would not only ameliorate pain but also restore functionality. Charnley was destined through his training and circumstances for this ultimate challenge.

Like many great contributors to the field of orthopedics, Charnley was an engineer, craftsman, and inventor at heart.²⁸ Whereas others were initiating the pursuit of biophysiological treatment approaches to cartilage restoration in arthritis, Charnley envisioned and devised the development of a sturdy medical device that mimicked

the anatomy of the femoral and acetabular components of the joint to serve as a total replacement implant.²⁹ His surgical approach did not "tinker around the edges." The extensive operative procedure includes osteotomy of the greater trochanter to accommodate the femoral stem within the medullary canal and replacement of the acetabular cup.²⁸ These insights illustrate his extensive, detailed knowledge of the hip and its transmission of forces from the extremity to the pelvis and trunk. The entire system was meant to replicate the natural ball-and-socket configuration, and Charnley's intuitive facility with biomechanics brought the implant to life.

Charnley always acknowledged the importance of serendipity—one of his favorite aphorisms was, "You have got to be able to see where others do not appreciate, the importance of fortuitous facts."²⁸ Indeed, when Charnley's original experimental acetabular component (composed of polytetrafluoroethylene [PTFE]) exhibited significant wear debris, extreme foreign body reaction, and an unacceptable failure rate, an astute engineering intern, Harry Craven, serendipitously presented Charnley with test results of ultra-high molecular weight polyethylene (UHMWP), which show excellent wear resistance, low friction, and high impact strength. Indeed, UHMWP was manyfold more durable, and the wear characteristics were far superior to results achieved with PTFE. Although Charnley had initially been reluctant to evaluate UHMWP, these findings convinced Charnley that the wear debris associated with PTFE, and the commensurate risk of revision, could be obviated with UHMWP. Hence, he eagerly adopted UHMWP for the acetabular cup and married it with a one-piece stainless steel femoral stem and head. Finally, to prevent loosening, polymethylmethacrylate bone cement, which was utilized by dentists of the day, was used to secure the femoral stem within the medullary canal.³³

Charnley performed the first THA surgery with this novel, low-friction system on 22 November 1962. From his clinical research base at Wrightington hospital near Manchester, England, he spent the next 2 decades refining his surgical technique to also include effective intraoperative infection control, introducing the innovative use of laminar airflow in the operating suite and designing specialized surgical suits that directed airflow toward the surgeon's feet and away from the patient. In the end, Charnley's legacy as the father of THA was established, and the procedure became the gold standard for the treatment of the severely arthritic hip as well as for expanded indications that included younger active patients, forming the basis of all

derivative implant designs and future innovations in hip arthroplasty.^{29,36–38} But, perhaps even more importantly, Charnley's breakthrough provided the inspiration and impetus to tackle degenerative articular disease in other major appendicular joints.

EXPANSION OF INDICATIONS FOR ARTHROPLASTY

Because of the success with hip replacement, research began on total knee arthroplasty, but not without the perseverance required over several decades to understand the additional intricacies associated with this large lower extremity joint complex.³⁹ A tremendously robust research, development, and clinical adoption effort in total knee arthroplasty has yielded an impressive 25-year implant survival rate in excess of 80%.⁴⁰ These results continue to improve with the use of patient-specific implants, preoperative planning with advanced imaging, intraoperative image guidance, and robotics.

While the etiology and disease mechanism differ in the shoulder and ankle joints compared with the hip and knee, with arthritic degeneration occurring secondary to trauma in most cases, the successful application of arthroplasty as an effective treatment option has also continued to improve and thrive for these conditions.^{41,42} In the ensuing years since Charnley's inaugural THA procedure in the early 1960s, total joint replacement has become a mainstay procedure for the treatment of all large damaged or dysfunctional synovial joints.

THE SPINAL FUSION PARADIGM

While joint replacement approaches and implants became more refined and flourished in the treatment of severely degenerated joints in the appendicular skeleton, the surgical management of age-related spinal degeneration followed a distinctly dissimilar path.^{43,44}

Due to the proximity of important neural structures in the spine, the deterioration of the 3-joint complex of each lumbar motion segment can produce intractable symptoms of low back pain, radiculopathy, and/or neurogenic claudication due to compression of the spinal cord, nerve roots, and/or exiting nerves.^{13,45} Thus, unlike the total joint replacement approach to the treatment of the large arthritic synovial joints of the appendicular skeleton, bony and ligamentous surgical decompression of the offended neural elements has been the primary surgical objective in the spine, first and foremost.

Unfortunately, the very act of surgically removing bone to relieve the impinged neural elements has the

untoward consequence of disrupting the natural biomechanical stability of the spinal motion segment.⁴⁶ The wider the decompression, the greater the instability.⁴⁷ Although perhaps shortsighted, the logical answer to this dilemma was to restore stability to the affected segment.⁴³ As early as the late 1940s, pioneering spine surgeon Ralph Bingham Cloward (1908–2000), who is justly credited as the inventor of the posterior lumbar interbody fusion technique and anterior cervical discectomy and fusion, championed the use of allograft bone to facilitate a mechanically solid endplate-to-endplate arthrodesis across the motion segment.⁴⁸ While fusion initially gained acceptance for treating scoliotic spinal deformity and unstable fractures, the widespread clinical adoption of decompression coupled with fusion progressively expanded to include the surgical management of a wide array of lumbar disorders, including degenerative disc disease, spinal stenosis, and spondylolisthesis, as well as the nebulously defined “nonspecific chronic low back pain.”^{49,50}

However, it was the introduction of metallic instrumentation, particularly pedicle screws, that “sealed the deal” for the burgeoning growth of the spine industry.^{51,52} The surgeon now had the armamentarium to provide immediate stabilization to the surgically decompressed motion segment using an ever-growing variety of spinal implant systems. Indeed, the down-classification of pedicle screws by the US Food and Drug Administration (FDA), from class III to class II, in the 1990s paved the way for the unprecedented proliferation of small spinal implant companies attempting to capitalize on the utilization of metallic instrumentation.^{43,51} Requiring a less onerous 510(k) premarket notification route resulted in an abundance of interbody cage and screw systems being approved by the FDA.

Why did fusion take hold as an acceptable treatment preference in the surgical management of the aging spine when it was eschewed as an option in the appendicular joints? Had not Charnley proved that total joint arthroplasty, not arthrodesis, was the answer to restoring pain-free function to the patient? One of the primary reasons was that the effects of arthrodesis on the hip joint were so noticeably and immediately profound and unacceptable to the patient. This included an awkward gait and concomitant stress amplification on the low back and knees, which produced a cascade of additional problems, so much so that the procedure was essentially abandoned after Charnley's success. Alternatively, in the spine, the functional impact of fusing 1 or 2 lumbar

motion segments was almost imperceptible in the short term to the patients who experienced immediate symptom relief as a result of the neural decompression procedure.

However, despite spinal arthrodesis being embedded in the surgical arsenal as a viable treatment option, the consequences of fusing a motion segment and fundamentally altering its biomechanics began to be appreciated over time. Because of the stress associated with rigid fixation and fusion, a new condition, *adjacent segment disease*, emerged.^{53,54} Additionally, the persistent concern of instrumentation failure, implant subsidence, and pedicle screw breakage with recurrent symptoms developed.⁵⁵⁻⁵⁷ Most importantly perhaps is the growing body of evidence suggesting that instrumented spinal fusion in many cases does not offer additional patient benefit above and beyond that provided by decompression alone.^{50,58-60}



Figure 1. The facade of Wrightington Hospital appears today very much the same as it did in the time of Sir John Charnley.

THE EMERGENCE OF MOTION PRESERVATION IN THE SPINE

Recognizing the potential shortcomings of undertaking a surgical procedure that irreversibly eliminated the natural functional flexibility of the spine, a new paradigm was proposed by spine experts that was grounded in the concept of *motion preservation*. To much fanfare and excitement in the public media, the world was introduced to the concept of total disc replacement.⁶¹ The first artificial disc (Charité) was implanted in the United States in 2000, and FDA approval followed in 2004. There was so much initial fervor surrounding the discovery of a new surgical option that might eliminate the need for fusion and restore natural motion, reminiscent of THA, that an entire society, the Spine Arthroplasty Society (SAS), was established in 2000 to offer a dedicated platform and independent venue for medical professionals devoted to this concept. The first international meeting of the SAS was convened in Munich, Germany in 2001 with 400 attendees. The society also launched its own journal, the *SAS Journal*.

But headwinds were strong. Unlike interbody cage devices, the FDA required that artificial discs undergo the lengthy and expensive premarket approval process. In sharp contrast to the enormous number of cage approvals, regulatory clearances for disc systems have been exceedingly rare, particularly in the lumbar spine. Most importantly, because this surgical application focused primarily on disc pathology, its indications for use were restricted to younger patients with suspected focal degenerative disc disease. For the much more broad, older patient population, this procedure was contraindicated due to the presence of advanced spinal deterioration across the entire 3-joint complex. To add insult to injury, obtaining reimbursement for the disc replacement procedure was onerous as third-party payers were unconvinced by the evidence that disc arthroplasty, or fusion for that matter, was a required or necessary treatment option for young patients with isolated disc disease.

In fewer than 10 years, the wind was out of the sails. The SAS was renamed the International Society for the Advancement of Spine Surgery in 2011, the *SAS Journal* struggled (and was subsequently rebranded as the *International Journal of Spine Surgery*), and the early promise of replacing lumbar fusion with artificial disc replacement was a distant memory.⁶²

This unfortunate series of events stymied any further developmental efforts aimed at motion preservation that would address the substantial number of older patients with advanced spinal degeneration, and fusion remained

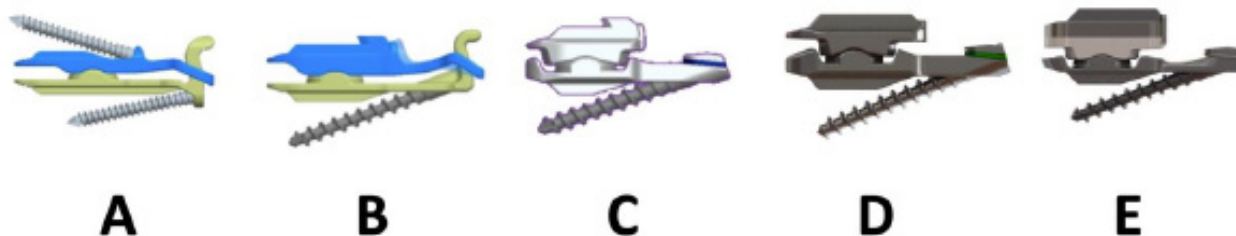


Figure 2. Historical timeline for the development of the total joint replacement implant. Commencing in 2004 (A), initial concept (B), removal of superior screw (C), removal of tail and optimizing and finalizing the materials (D and E).

the mainstay.⁶³ Indeed, in their chapter "The Future of Motion Preservation," Hochschuler and Ohnmeiss⁶⁴ give but scant mention in the subsection entitled "Combined Motion-Preserving Technologies" to the possibility of total joint replacement of the spine, stating: "Just as there became a role for combined anterior/posterior fusion, there will likely be a role of combined anterior/posterior dynamic stabilization. No clinical application of combined motion retaining technologies, however, has been found."

TOTAL JOINT REPLACEMENT OF THE SPINE

In January 2023, the first author (S.C.H.) visited the Wrightington hospital to draw insight from the vast experience of an extraordinary team, long dedicated to promulgating the work of Charnley (Figure 1). Meeting with orthopedic staff who had worked side-by-side with the revered surgeon offered the unique opportunity to caucus about the challenges associated with adapting the concept of total joint replacement to the spine. Indeed, no other group in the world has a greater depth and breadth of know-how in the development and clinical application of arthroplasty.

However, this meeting was not purely a conceptual discussion. Much work on the development of total joint replacement in the spine had already been accomplished over the previous 20 years. Working initially with posterior interbody cages, the advantages

of the transforaminal lumbar interbody fusion (TLIF) approach over posterior lumbar interbody fusion with respect to requiring less neural traction and intraoperative blood loss were identified.^{65,66} With tutelage from Professor Juergen Harms, further modifications were made to the TLIF approach by including a facetectomy over Kambin's triangle, which allowed for a more direct approach to the disc space. The radical idea of total joint replacement was conceived and evolved empirically based on the advantage of a posterior approach to lumbar pathology and the commitment to return and preserve normal motion. Taking inspiration from Charnley, this procedure did not "tinker around the edges"—the concept was to simultaneously replace the entire 3-joint complex of a degenerated spinal motion segment with a sturdy implant that restored normal biomechanics and full functionality to the joint. This requires removal of the intervertebral disc and both facets as well as extensive neural decompression and disc space preparation. The implant, which evolved over the ensuing 2 decades, was optimized to mimic the kinematic characteristics of the 3-joint complex, where the disc and facets work in harmony to provide constrained 3-dimensional motion (Figure 2). The implant acquired the apt Latin-derived homonym, MOTUS, meaning a *movement, motion*, or an *advance progress* (Figure 3).

Biomechanical testing of the implant demonstrated that it was able to mimic the physiological motion and intradiscal pressures of the native spine during sitting, standing, flexion, and extension.⁶⁷ Thus, total joint replacement of the spine may allow for preservation of lumbar segment motion, permitting the patient's lumbar spine to move into more lordosis during standing or relative kyphosis during sitting and thus may protect the physiological motion cascade during these postures of daily living.⁶⁸

Initial clinical results with this implant have been encouraging. In a propensity-matched study comparing 156 TLIF-treated patients with 52 implant-treated



Figure 3. The MOTUS device (3Spine, Chattanooga, TN, USA).

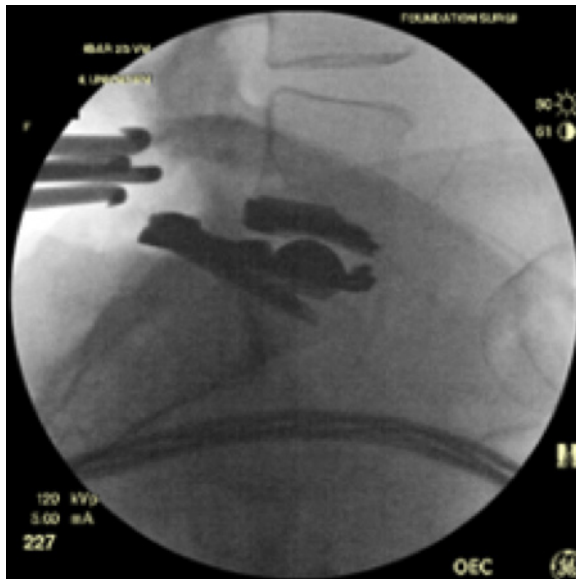


Figure 4. Intraoperative fluoroscopic image confirming final implant placement showing the rectangular device resting on posterior superior S1 with the L5 to S1 segment in lordosis. The wedge-shaped pedicle vertebral body osteotomy of S1 allows the device to rest in the disc space while maintaining segmental lordosis.

patients, Sielatycki et al⁶⁸ reported comparative Oswestry Disability Index responder rates for back function of 72% and 90%, respectively. Additionally, the FDA granted MOTUS a “Breakthrough Device Designation.” This is a formal identification by the FDA that a device in development should be expedited for patient access because it has a reasonable chance of providing more effective treatment than the standard of care for the treatment or diagnosis of life-threatening or irreversibly debilitating human diseases or conditions. Figure 4 shows the total joint replacement implant in situ.

Is this the end of the beginning? Will Charnley’s vision be fulfilled? Will total joint replacement render arthrodesis obsolete for the treatment of the degenerated spine? Indeed, we have evolved a new appreciation of the interrelationship of arthritic degeneration across the entire 3-joint complex, including the disc and the facets.^{24,69} However, clinical adoption of total joint replacement in the spine may face an uphill battle given our decades-long devotion to the utilization of fusion devices and instrumentation. That said, we gain confidence that with Charnley’s tacit imprimatur, we can finally roll the boulder over the top of the hill.

REFERENCES

1. DeSai C, Reddy V, Agarwal A. Anatomy, back, vertebral column. In: *StatPearls*. Treasure Island (FL); 2022.

2. Christenson PC. The radiologic study of the normal spine: cervical, thoracic, lumbar, and sacral. *Radiol Clin North Am*. 1977;15(2):133–154.

3. Schwend RM, Hennrikus WL. Anatomy of the pediatric spine. In: Schwend RM, Hennrikus WL, eds. *Back Pain in the Young Child and Adolescent*. Springer Cham; 2021:21–32. doi:10.1007/978-3-030-50758-9

4. Pennisi E. Evolutionary biology. The burdens of being a biped. *Science*. 2012;336(6084):974. doi:10.1126/science.336.6084.974

5. Brandt KD, Dieppe P, Radin E. Etiopathogenesis of osteoarthritis. *Med Clin North Am*. 2009;93(1):1–24. doi:10.1016/j.mcna.2008.08.009

6. Filler AG. Emergence and optimization of upright posture among hominiform hominoids and the evolutionary pathophysiology of back pain. *Neurosurg Focus*. 2007;23(1):E4. doi:10.3171/foc.2007.23.1.4

7. Botwin KP, Gruber RD. Lumbar spinal stenosis: anatomy and pathogenesis. *Phys Med Rehabil Clin N Am*. 2003;14(1):1–15. doi:10.1016/s1047-9651(02)00063-3

8. Curry WH, Pintar FA, Doan NB, et al. Lumbar spine end-plate fractures: biomechanical evaluation and clinical considerations through experimental induction of injury. *J Orthop Res*. 2016;34(6):1084–1091. doi:10.1002/jor.23112

9. Stefanakis M, Luo J, Pollintine P, Dolan P, Adams MA. ISSLS prize winner: mechanical influences in progressive intervertebral disc degeneration. *Spine (Phila Pa 1976)*. 2014;39(17):1365–1372. doi:10.1097/BRS.0000000000000389

10. Szpalski M, Gunzburg R. Lumbar spinal stenosis in the elderly: an overview. *Eur Spine J*. 2003;12(Suppl 2):S170–S175. doi:10.1007/s00586-003-0612-1

11. Niosi CA, Oxland TR. Degenerative mechanics of the lumbar spine. *Spine J*. 2004;4(6 Suppl):202S–208S. doi:10.1016/j.spinee.2004.07.013

12. Benoist M. Natural history of the aging spine. *Eur Spine J*. 2003;12(Suppl 2):S86–S89. doi:10.1007/s00586-003-0593-0

13. Papadakis M, Sapkas G, Papadopoulos EC, Katonis P. Pathophysiology and biomechanics of the aging spine. *Open Orthop J*. 2011;5:335–342. doi:10.2174/1874325001105010335

14. Middleton K, Fish DE. Lumbar spondylosis: clinical presentation and treatment approaches. *Curr Rev Musculoskelet Med*. 2009;2(2):94–104. doi:10.1007/s12178-009-9051-x

15. Brinjikji W, Luetmer PH, Comstock B, et al. Systematic literature review of imaging features of spinal degeneration in asymptomatic populations. *AJNR Am J Neuroradiol*. 2015;36(4):811–816. doi:10.3174/ajnr.A4173

16. Kalichman L, Hunter DJ. Lumbar facet joint osteoarthritis: a review. *Semin Arthritis Rheum*. 2007;37(2):69–80. doi:10.1016/j.semarthrit.2007.01.007

17. Varlotta GP, Lefkowitz TR, Schweitzer M, et al. The lumbar facet joint: a review of current knowledge: part I: anatomy, biomechanics, and grading. *Skeletal Radiol*. 2011;40(1):13–23. doi:10.1007/s00256-010-0983-4

18. Varlotta GP, Lefkowitz TR, Schweitzer M, et al. The lumbar facet joint: a review of current knowledge: part II: diagnosis and management. *Skeletal Radiol*. 2011;40(2):149–157. doi:10.1007/s00256-010-0984-3

19. Pathria M, Sartoris DJ, Resnick D. Osteoarthritis of the facet joints: accuracy of oblique radiographic assessment. *Radiology*. 1987;164(1):227–230. doi:10.1148/radiology.164.1.3588910

20. Kushchayev SV, Glushko T, Jarraya M, et al. Absc of the degenerative spine. *Insights Imaging*. 2018;9(2):253–274. doi:10.1007/s13244-017-0584-z
21. Andreisek G, Imhof M, Wertli M, et al. A systematic review of semiquantitative and qualitative radiologic criteria for the diagnosis of lumbar spinal stenosis. *AJR Am J Roentgenol*. 2013;201(5):W735–W746. doi:10.2214/AJR.12.10163
22. Kreiner DS, Shaffer WO, Baisden JL, et al. An evidence-based clinical guideline for the diagnosis and treatment of degenerative lumbar spinal stenosis (update). *Spine J*. 2013;13(7):734–743. doi:10.1016/j.spinee.2012.11.059
23. Steurer J, Roner S, Gnannt R, Hodler J, LumbSten Research C. Quantitative radiologic criteria for the diagnosis of lumbar spinal stenosis: a systematic literature review. *BMC Musculoskelet Disord*. 2011;12:175. doi:10.1186/1471-2474-12-175
24. Fine N, Lively S, Séguin CA, Perruccio AV, Kapoor M, Rampersaud R. Intervertebral disc degeneration and osteoarthritis: a common molecular disease spectrum. *Nat Rev Rheumatol*. 2023;19(3):136–152. doi:10.1038/s41584-022-00888-z
25. Amstutz HC. Innovations in design and technology. The story of hip arthroplasty. *Clin Orthop Relat Res*. 2000;(378):23–30.
26. Bota NC, Nistor DV, Caterev S, Todor A. Historical overview of hip arthroplasty: from humble beginnings to a high-tech future. *Orthop Rev (Pavia)*. 2021;13(1):8773. doi:10.4081/or.2021.8773
27. Fontalis A, Epinette JA, Thaler M, Zagra L, Khanduja V, Haddad FS. Advances and innovations in total hip arthroplasty. *SICOT J*. 2021;7:26. doi:10.1051/sicotj/2021025
28. Gomez PF, Morcuende JA. A historical and economic perspective on Sir John Charnley, Chas F. Thackray limited, and the early arthroplasty industry. *Iowa Orthop J*. 2005;25:30–37.
29. Jackson J. Father of the modern hip replacement: Professor Sir John Charnley (1911–82). *J Med Biogr*. 2011;19(4):151–156. doi:10.1258/jmb.2011.011021
30. Kingston R, Walsh MG. The evolution of hip replacement surgery. *Ir Med J*. 2001;94(1):5.
31. Knight SR, Auja R, Biswas SP. Total hip arthroplasty - over 100 years of operative history. *Orthop Rev (Pavia)*. 2011;3(2):e16. doi:10.4081/or.2011.e16
32. Learmonth ID, Young C, Rorabeck C. The operation of the century: total hip replacement. *Lancet*. 2007;370(9597):1508–1519. doi:10.1016/S0140-6736(07)60457-7
33. Markatos K, Savvidou OD, Foteinou A, et al. Hallmarks in the history and development of total hip arthroplasty. *Surg Innov*. 2020;27(6):691–694. doi:10.1177/1553350620947209
34. Wroblewski BM. Professor Sir John Charnley (1911–1982). *Rheumatology (Oxford)*. 2002;41(7):824–825. doi:10.1093/rheumatology/41.7.824
35. Thomas TG. John Charnley: the man and the hip. *J R Soc Med*. 1990;83(11):754–754. doi:10.1177/014107689008301133
36. Kayani B, Konan S, Thakrar RR, Huq SS, Haddad FS. Assuring the long-term total joint arthroplasty: a triad of variables. *Bone Joint J*. 2019;101-B(1_Suppl_A):11–18. doi:10.1302/0301-620X.101B1.BJJ-2018-0377.R1
37. Evans JT, Evans JP, Walker RW, Blom AW, Whitehouse MR, Sayers A. How long does a hip replacement last? A systematic review and meta-analysis of case series and national registry reports with more than 15 years of follow-up. *The Lancet*. 2019;393(10172):647–654. doi:10.1016/S0140-6736(18)31665-9
38. Yan L, Ge L, Dong S, et al. Evaluation of comparative efficacy and safety of surgical approaches for total hip arthroplasty: a systematic review and network meta-analysis. *JAMA Netw Open*. 2023;6(1):e2253942. doi:10.1001/jamanetworkopen.2022.53942
39. Scuderi GR, Scott WN, Tehejyan GH. The insall legacy in total knee arthroplasty. *Clin Orthop Relat Res*. 2001;392(392):3–14. doi:10.1097/00003086-200111000-00002
40. Evans JT, Walker RW, Evans JP, Blom AW, Sayers A, Whitehouse MR. How long does a knee replacement last? A systematic review and meta-analysis of case series and national registry reports with more than 15 years of follow-up. *Lancet*. 2019;393(10172):655–663. doi:10.1016/S0140-6736(18)32531-5
41. Cogan CJ, Ho JC, Entezari V, Iannotti JP, Ricchetti ET. The influence of reverse total shoulder arthroplasty implant design on biomechanics. *Curr Rev Musculoskelet Med*. 2023;16(3):95–102. doi:10.1007/s12178-023-09820-8
42. Hembree WC, Gallagher BW, Guyton GP. What's new in foot and ankle surgery. *J Bone Joint Surg Am*. 2022;104(10):857–863. doi:10.2106/JBJS.21.01562
43. de Kunder SL, Rijkers K, Caelers IJMH, de Bie RA, Koehler PJ, van Santbrink H. Lumbar interbody fusion: a historical overview and a future perspective. *Spine (Phila Pa 1976)*. 2018;43(16):1161–1168. doi:10.1097/BRS.0000000000002534
44. Virk S, Qureshi S, Sandhu H. History of spinal fusion: where we came from and where we are going. *HSS J*. 2020;16(2):137–142. doi:10.1007/s11420-020-09747-7
45. Benoist M. The natural history of lumbar degenerative spinal stenosis. *Joint Bone Spine*. 2002;69(5):450–457. doi:10.1016/s1297-319x(02)00429-3
46. Leone A, Guglielmi G, Cassar-Pullicino VN, Bonomo L. Lumbar intervertebral instability: a review. *Radiology*. 2007;245(1):62–77. doi:10.1148/radiol.2451051359
47. Zhang Y, Wei F-L, Liu Z-X, et al. Comparison of posterior decompression techniques and conventional laminectomy for lumbar spinal stenosis. *Front Surg*. 2022;9:997973. doi:10.3389/fsurg.2022.997973
48. Cloward RB. Posterior lumbar interbody fusion updated. *Clin Orthop Relat Res*. 1985;193(193):16–19.
49. Reisener MJ, Pumberger M, Shue J, Girardi FP, Hughes AP. Trends in lumbar spinal fusion—a literature review. *J Spine Surg*. 2020;6(4):752–761. doi:10.21037/jss-20-492
50. Deyo RA, Nachemson A, Mirza SK. Spinal-fusion surgery - the case for restraint. *N Engl J Med*. 2004;350(7):722–726. doi:10.1056/NEJMs031771
51. Hart RA. Acknowledging the elephant in the room: conflict of interest in industry-sponsored clinical research. *Spine J*. 2011;11(8):703–704. doi:10.1016/j.spinee.2011.08.011
52. Malhotra D, Kalb S, Rodriguez-Martinez N, et al. Instrumentation of the posterior thoracolumbar spine: from wires to pedicle screws. *Neurosurgery*. 2014;10 Suppl 4:497–504; . doi:10.1227/NEU.0000000000000489
53. Virk SS, Niedermeier S, Yu E, Khan SN. Adjacent segment disease. *Orthopedics*. 2014;37(8):547–555. doi:10.3928/01477447-20140728-08
54. Eck JC, Humphreys SC, Hodges SD. Adjacent-segment degeneration after lumbar fusion: a review of clinical, biomechanical, and radiologic studies. *Am J Orthop (Belle Mead NJ)*. 1999;28(6):336–340.
55. Lonstein JE, Denis F, Perra JH, Pinto MR, Smith MD, Winter RB. Complications associated with pedicle screws. *J Bone Joint Surg Am*. 1999;81(11):1519–1528. doi:10.2106/00004623-199911000-00003

56. Niu S, Yang D, Ma Y, Lin S, Xu X. Is removal of the internal fixation after successful intervertebral fusion necessary? A case-control study based on patient-reported quality of life. *J Orthop Surg Res*. 2022;17(1):141. doi:10.1186/s13018-022-03031-6
57. Parisien A, Wai EK, ElSayed MSA, Frei H. Subsidence of spinal fusion cages: a systematic review. *Int J Spine Surg*. 2022;16(6):1103–1118. doi:10.14444/8363
58. Harris IA, Traeger A, Stanford R, Maher CG, Buchbinder R. Lumbar spine fusion: what is the evidence *Intern Med J*. 2018;48(12):1430–1434. doi:10.1111/imj.14120
59. Karlsson T, Försth P, Skorpil M, et al. Decompression alone or decompression with fusion for lumbar spinal stenosis: a randomized clinical trial with two-year MRI follow-up. *Bone Joint J*. 2022;104-B(12):1343–1351. doi:10.1302/0301-620X.104B12.BJJ-2022-0340.R1
60. Försth P, Ólafsson G, Carlsson T, et al. A randomized, controlled trial of fusion surgery for lumbar spinal stenosis. *N Engl J Med*. 2016;374(15):1413–1423. doi:10.1056/NEJMoa1513721
61. Fiani B, Nanney JM, Villait A, Sekhon M, Doan T. Investigational research: timeline, trials, and future directions of spinal disc arthroplasty. *Cureus*. 2021;13(7):e16739. doi:10.7759/cureus.16739
62. Helgeson MD, Pisano AJ, Wagner SC. What's new in spine surgery. *J Bone Joint Surg Am*. 2022;104(12):1039–1045. doi:10.2106/JBJS.22.00125
63. Antony A, Stevenson JC, Trimble DT, Block JE. Perspective: a proposed diagnostic and treatment algorithm for management of lumbar spinal stenosis: an integrated team approach. *Pain Physician*. 2023.
64. Hochschuler SH, Ohnmeiss DD. The future of motion preservation. In: Yue JJ, ed. *Motion Preservation Surgery of the Spine*. Philadelphia, PA: Saunders Elsevier; 2008:760–769.
65. Chastain CA, Eck JC, Hodges SD, Humphreys SC, Levi P. Transforaminal lumbar interbody fusion: a retrospective study of long-term pain relief and fusion outcomes. *Orthopedics*. 2007;30(5):389–392. doi:10.3928/01477447-20070501-18
66. Humphreys SC, Hodges SD, Patwardhan AG, Eck JC, Murphy RB, Covington LA. Comparison of posterior and transforaminal approaches to lumbar interbody fusion. *Spine (Phila Pa 1976)*. 2001;26(5):567–571. doi:10.1097/00007632-200103010-00023
67. Patwardhan AG, Sielatycki JA, Havey RM, et al. Loading of the lumbar spine during transition from standing to sitting: effect of fusion versus motion preservation at L4-L5 and L5-S1. *Spine J*. 2021;21(4):708–719. doi:10.1016/j.spinee.2020.10.032
68. Alex Sielatycki J, Devin CJ, Pennings J, et al. A novel lumbar total joint replacement may be an improvement over fusion for degenerative lumbar conditions: a comparative analysis of patient-reported outcomes at one year. *Spine J*. 2021;21(5):829–840. doi:10.1016/j.spinee.2020.12.001
69. Rustenburg CME, Emanuel KS, Peeters M, Lems WF, Vergroesen P-PA, Smit TH. Osteoarthritis and intervertebral disc degeneration: quite different, quite similar. *JOR Spine*. 2018;1(4):e1033. doi:10.1002/jsp2.1033

Funding: J.E.B. received funding to assist in the preparation of this manuscript from 3Spine, Inc. (Chattanooga, TN, USA). 3Spine also provided medical writing assistance for this article.

Declaration of Conflicting Interests: The authors report no conflicts of interest in this work.

Disclosures: Scott Hodges, S. Craig Humphreys, and J. Alex Sielatycki report stock ownership in 3Spine. Additionally, Scott Hodges and S. Craig Humphreys are co-founders of 3Spine, and S. Craig Humphreys also reports being a research director for 3Spine. Jon Block reports no relevant disclosures.

Author Contributions: S.C.H. and J.E.B. were involved in conceptualization; J.E.B. was involved in methodology, software, validation, and formal analysis; S.C.H., S.D.H., J.A.S., A.S., and J.E.B. were involved in investigation; S.C.H. and J.E.B. were involved in resources and data curation; J.E.B. was involved in and writing—original draft preparation; S.C.H., S.D.H., J.A.S., A.S., and J.E.B. were involved in writing—review and editing; S.C.H. was involved in visualization; S.C.H. and J.E.B. were involved in supervision, project administration, and funding acquisition. All authors have read and agreed to the published version of the manuscript.

Corresponding Author: Jon E. Block, Independent Consultant, 2210 Jackson St, Suite 401, San Francisco, CA 94115, USA; jb@drjonblock.com

Published 08 December 2023

This manuscript is generously published free of charge by ISASS, the International Society for the Advancement of Spine Surgery. Copyright © 2024 ISASS. To see more or order reprints or permissions, see <http://ijssurgery.com>.