INTERNATIONAL JOURNAL of SPINE SURGERY

# Nonmetallic Carbon Fiber-Reinforced Polyetheretherketone Implants Vs Titanium Implants: Analysis of Clinical Outcomes and Influence on Postoperative Radiotherapy Planning in Metastatic Spine Tumor Surgery

Naresh Kumar, Priyambada Kumar, Gabriel Leow Zihui, Leon Seow, Shen Liang, Si Jian Hui, Rohan Parihar, James Hallinan, Balamurugan Vellayappan and Jiong Hao Jonathan Tan

*Int J Spine Surg* 2024, 18 (5) 603-610
doi: https://doi.org/10.14444/8685
https://www.ijssurgery.com/content/18/5/603



*The International Journal of Spine Surgery*
2397 Waterbury Circle, Suite 1,
Aurora, IL 60504, Phone: +1-630-375-1432

*International Journal of Spine Surgery*, Vol. 18, No. 5, 2024, pp. 603–610
https://doi.org/10.14444/8685


# Nonmetallic Carbon Fiber-Reinforced Polyetheretherketone Implants Vs Titanium Implants: Analysis of Clinical Outcomes and Influence on Postoperative Radiotherapy Planning in Metastatic Spine Tumor Surgery

NARESH KUMAR, MBBS, MS(Orth), DNB[1]; PRIYAMBADA KUMAR, MBBS, MS[1]; GABRIEL LEOW ZIHUI, MBBS[2]; LEON SEOW, MBBS[3]; SHEN LIANG, PhD[4]; SI JIAN HUI, MBBS, MRCS(Edin)[2]; ROHAN PARIHAR, MBBS, MS[1]; JAMES HALLINAN, MBChB[5]; BALAMURUGAN VELLAYAPPAN, MBBS[3]; AND JIONG HAO JONATHAN TAN, MBBS, MRCS, MMED, FRCSEd[1]

*[1]Department of Orthopedic Surgery (Spine division), National University Hospital, Singapore, Singapore; [2]Department of Orthopedic Surgery, National University Hospital, Singapore, Singapore; [3]Department of Radiation Oncology, National University Hospital, Singapore, Singapore; [4]Biostatistics Unit, National University of Singapore, Singapore, Singapore; [5]Department of Diagnostic Imaging, National University Hospital, Singapore, Singapore*

## ABSTRACT

**Background:** Titanium has been the conventional implant material of choice for fixation in both primary and metastatic spine tumor surgeries (MSTS). However, these implants result in artifact generation during postoperative computed tomography or magnetic resonance imaging, resulting in poor planning of radiotherapy (RT) and suboptimal tumor surveillance. Carbon fiber–reinforced polyetheretherketone (CFR-PEEK) implants have gained momentum for instrumentation in MSTS due to their radiolucent properties. In this study, the perioperative outcomes, postoperative imaging artifacts, and dosimetric data of CFR-PEEK implants to titanium implants were compared to assess for potential benefits in postoperative RT planning in patients undergoing MSTS.

**Methods:** This is a retrospective study involving 62 patients who underwent operations for MSTS. The cohort of CFR-PEEK fixations ($n = 20$) was compared with a series of patients operated using titanium implants ($n = 42$). Patient-related data, including demographics, tumor pathology and extent of morbidity, intraoperative data, functional outcome, and RT-related data, were recorded for both groups. Primary outcome measures for RT data were amount of artifact generated on postoperative imaging and the time taken to contour them. All patients were followed up postoperatively for a minimum of 2 years or until death, whichever was earlier.

**Results:** Both groups had similar clinical outcomes for pain and overall survival predictability preoperatively ($P = 0.786$). The mean number of levels instrumented by titanium screws was 5.69 ± 2.64, while for CFR-PEEK screws it was 4.26 ± 1.05. Mean volume of artifact generated during postoperative computed tomography was 73.4 ± 50.43 $mm^3$ in the titanium group and 20.0 ± 20.7 $mm^3$ in the CFR-PEEK group ($P < 0.001$). The mean time taken to contour the artifacts was 17.3 ± 5.84 minutes in titanium group and 9.60 ± 7.17 minutes in CFR-PEEK group ($P = 0.049$).

**Conclusion:** Our study confirms that CFR-PEEK screws significantly reduce artifact generation and the time taken to contour them during postoperative RT planning while delivering equivalent clinical and functional outcomes as compared with standard titanium implants.

**Level of Evidence:** 2.

Article

Keywords: metastatic spine tumour surgery, CFR-PEEK, adjuvant radiotherapy

## INTRODUCTION

In approximately 40% of cancer patients, the cancer will culminate in spinal metastasis, although only 10% of these patients display clinical manifestations in the form of neurological deficits, radicular pain, axial pain, etc. The thoracic spine (60%–80%) is the most commonly affected segment, followed by the lumbar (15%–30%) and then cervical spine (<10%).[1] The presence of neurodeficit secondary to compression of neural elements, symptomatic spinal instability, impairing axial pain, or a combination of the above are all prime indications for surgical intervention.[2]

Conventionally titanium implants have been the implant material of choice for various spine surgeries requiring internal fixation due to their excellent biomechanical properties demonstrating adequate rigidity and dependability. However, while dealing with primary or secondary tumors of the spine, the use of titanium implants often leads to significant interference with the assessment of postoperative imaging owing to artifacts generated by the metal.[3,4] Although there have been improvement in metal suppression techniques for computed tomography (CT) and magnetic resonance imaging (MRI), a varying degree of artifacts generation is inevitable. This interference has the potential to impact the precise planning and execution of effective radiotherapy (RT) regimens, as well as the ability to adequately monitor the progression or relapse of the tumor through radiological follow-up.[5,6] The presence of metallic implants can also adversely impact the administration of postoperative radiation therapy due to an uneven radiation dose distribution.[5]

In an attempt to overcome these constraints, screws and rods made from carbon fiber-reinforced polyetheretherketone (CFR-PEEK), were devised. Radiolucency and nonmagnetizability of these implants vastly aid in reduction of distortions in CT images and MRIs postoperatively.[7,8] These characteristics substantially simplify radiological assessment of neural structures in case of recurrence of the tumor. In addition, the radiolucency of CFR-PEEK enhances the accuracy of dose calculation for postoperative irradiation of the tumor bed. These implants also reduce radiation scattering and tumor shielding, usually seen in case of metallic implants.[3,4,9,10]

Over the last few years, there has been an increase in their usage across various spine centers, resulting in widely published research highlighting the biomechanical properties of CFR-PEEK implants, their clinical utilization in spine tumor cases, and perioperative complications.[10,11] However, on a comprehensive review of existing literature, we realized that empirical evidence remains scarce about the elaborate objective data regarding the RT artifacts generated. In the present study, we hope to bridge this gap by comparing the imaging artifacts and dosimetric data of CFR-PEEK implants to conventional titanium implants, thereby enabling wider adoption of the former in clinical practice.

## MATERIALS AND METHODS

The present study was retrospectively conducted at a tertiary referral center between January 2019 and December 2021. The study was initiated after approval from the institutional review board (approval No. 2022/00231). Sixty-two consecutive patients with metastatic spine disease (MSD) of the thoracic, thoracolumbar, or lumbar spine were included. All surgeries were performed by a single experienced spine surgeon specializing in MSD. Indications for surgery were evaluated by a team of experts, including a senior spine surgeon, an oncologist, and a radio-oncologist, and included the presence of neural deficit attributable to the tumor, symptomatic spinal instability analyzed according to spinal instability neoplastic score (SINS) classification,[12] impairing axial back pain, or a combination of the above. Patients included in the study were those having histological evidence of the primary tumor, those with radiological evidence of MSD, and those who underwent posterior spinal fixation and stabilization using CFR-PEEK pedicle screws with titanium or CFR-PEEK rods. Patients requiring an additional concomitant surgical procedure for a metastatic focus elsewhere in the body or those with a prior history of surgery for MSD were excluded.

The cohort of CFR-PEEK fixations ($n$ = 20) was compared with a series of consecutively operated MSD patients who underwent fixation using titanium pedicle screw-rod systems ($n$ = 42). All screws in both groups were placed using either an open or minimally invasive technique using intraoperative image intensifier and/or confirmed with intraoperative navigation system. We emphasize that all 62 patients in the current study were eligible to be treated with either group of implants, and the decision on implant material was solely based on patient preference after informed consent. CFR-PEEK posterior instrumentation was done using icotec (Altstätten, Switzerland) system, and titanium fixations were done using Globus (revere/creo) or K2M Everest systems. The decision to use CFR-PEEK or titanium rods was dictated by the available contour and length of CFR-PEEK rods and patient affordability which varied on a case-by-case basis.

The preoperative data collected were patient demographic details and tumor-related data, including site of primary tumor, other sites of metastases, and general condition of the patient evaluated by Eastern Cooperative Oncology Group score. Derived data to aid in surgical planning included grade of instability according to SINS classification[12] and predicted survivability according to the Charlson Comorbidity Index[13] and Modified Tokuhashi score.[14] MRIs or CT images were used to detect the location and extent of pathological fracture and/or spinal cord compression. In correlation with the clinical data, they assisted in determining

whether the patient required decompression at 1 or more levels.

Intra- and postoperative details regarding the type of instrumentation, decompression (if done or not), length of construct, estimated blood loss, procedure time, improvement in American Spinal Injury Association score, length of hospital stay, overall complications, and length of follow-up were recorded. Data related to RT in terms of type of volume of artifact generation on postoperative CT and time taken for artifact contouring were also recorded. All patients were called for follow-up postoperatively at 3, 6, 12, and 24 months or until demise, whichever was earlier.

### RT Planning

Following surgery, patients were referred to the treating radiation oncologist, and the decision was made regarding the RT regimen, which was tailored specifically to the requirement of each patient. Postoperative CT was performed for every patient prior to discharge to aid in planning of the RT regimen. On CT simulation scans, contouring of implant-related artifacts was done by a single observer in a standardized manner using Eclipse (v 18.0) and Monaco RT planning systems. Artifacts were delineated in axial slices with slice thickness of 3 mm at standardized window level of W600 L40 (Abdominal). Artifact region of interest was described as adjacent hypodense areas to metallic components of the spinal implant spanning from 1 vertebral level above and below the irradiated region. The region of interest volume was generated by the software, and time taken to contour was also recorded.

### Statistical Analysis

Statistical analyses were performed using IBM SPSS version 29. Patients' demographics and baseline clinical characteristics were analyzed descriptively. Mean with SD or median with range was reported as appropriate. Independent sample *t* test or Mann-Whitney *U* test was used to compare the numerical variables between the titanium group and the CFR-PEEK group, while $\chi^2$ test or Fisher's Exact test was used to compare the categorical variables. Numerical outcomes, such as blood loss, procedure duration, and so on, were compared by Mann-Whitney *U* test. Incidences of medical complications, surgical complications, and embolizations were compared using $\chi^2$ test or Fisher's exact test. Logistic regression was used to compare the medical complication incidence between 2 groups, adjusting for potential confounders. Two-sided $P$ value < 0.05 was statistically significant.

## RESULTS

### Demographics

A total of 62 patients with MSD were included in our study. The mean age was 63.0 ± 10.3 years in the titanium group and 63.8 ± 15.2 years in the CFR-PEEK group. The mean SINS was 11.45 ± 2.36 in the titanium group and 11.50 ± 1.24 in the CFR-PEEK group (indicating potential instability in both groups). The median Charlson Comorbidity Index was 9.00 (3.00–11.00) in the titanium group and 9.00 (2.00–13.00) in the CFR-PEEK group. According to Eastern Cooperative Oncology Group scoring, 39 patients in the titanium group and 17 patients in the CFR-PEEK group were independent in their activities of daily life, whereas 3 patients in the titanium group and 3 patients in the CFR-PEEK group were dependent living. The full table on our patient's demographics is shown in Table 1.

### Surgical Details

Posterior-only approach was followed for all patients. On average, 5.69 ± 2.64 levels were instrumented in the titanium group and 4.26 ± 1.05 levels were instrumented in the CFR-PEEK group. Decompression was performed in 29 patients from the titanium group and 9 patients in the CFR-PEEK group. The median blood loss was 500 mL in the titanium group and 275 mL in the CFR-PEEK group ($P$ = 0.050). The median duration of the procedure was 286 (94–726) minutes in the titanium group and 270 (154–468) minutes in the CFR-PEEK group ($P$ = 0.243). Two cases with delayed wound healing were reported in the titanium group. Both were treated subsequently with serial dressings. In 1 patient from the CFR-PEEK group, screws loosening and backout were detected during postoperative follow-up at 6 months. The pathological fracture in this case had consolidated by this time and did not need further stabilization. Hence, all instrumentation was removed. Complications such as screw or rod breakage were not recorded in either of the 2 groups. Incidental durotomy was reported in 2 patients from the titanium group and 1 patient in the CFR-PEEK group. Overall, the combined surgical complications in the 2 groups did not reach a statistical significance. The full table on surgical details is shown in Table 2.

### Outcome

Both groups had similar clinical outcomes for pain and overall survival ($P$ > 0.05; Figure 1). American Spinal

**Table 1.** Demographic and clinical characteristics by study group.

| Characteristic | Titanium | CFR-PEEK | *P* |
|---|---|---|---|
| Number of patients, *n* (%) | 42 (67.7%) | 20 (32.3%) | - |
| Age at surgery, y, mean ± SD | 63.0 ± 10.3 | 63.8 ± 15.2 | 0.813 |
| Sex, *n* (%) | | | - |
| Man | 26 (61.9%) | 9 (45.0%) | |
| Woman | 16 (30.10%) | 11 (55.0%) | |
| Primary tumor,[a] *n* (%) | | | 0.089[c] |
| Lung, osteosarcoma, stomach, and bladder | 13 (31.0) | 5 (25.0) | |
| Esophagus and pancreas | 1 (2.38) | 0 (0) | |
| Liver, gallbladder, and unidentified | 1 (2.38) | 2 (10.0) | |
| Kidney and uterus | 1 (2.38) | 4 (20.0) | |
| Rectum | 15 (35.7) | 3 (15.0) | |
| Thyroid, breast, prostate, and carcinoid tumor | 11 (26.2) | 6 (30.0) | |
| SINS, *n* (%) | | | 0.509[c] |
| 0–6 | 2 (4.80) | 0 (0) | |
| 7–12 | 27 (64.2) | 15 (75.0) | |
| 13–18 | 13 (31.0) | 5 (25.0) | |
| SINS, mean ± SD | 11.45 ± 2.36 | 11.50 ± 1.24 | 0.933 |
| CCI score, median (range) | 9.00 (3.00–11.00) | 9.00 (2.00–13.00) | 0.106[d] |
| Modified Tokuhashi score, mean ± SD | 8.62 ± 2.45 | 8.40 ± 2.70 | 0.376 |
| Predicted survivability,[a] *n* (%) | | | 0.259[c] |
| 0–6 mo | 14 (54.5) | 8 (40.0) | |
| 9–11 mo | 19 (27.3) | 11 (50.0) | |
| >11 mo | 9 (18.2) | 1 (10.0) | |
| ECOG score, *n* (%) | | | |
| 0 | 23 (54.8) | 10 (50.0) | 0.230[c] |
| 1 | 13 (31.0) | 3 (15.0) | |
| 2 | 3 (7.14) | 4 (20.0) | |
| 3 | 3 (7.14) | 2 (10.0) | |
| 4 | 0 (0) | 1 (5.0) | |
| Independence,[b] *n* (%) | | | 0.328[c] |
| Independent | 39 (92.9) | 17 (85.0) | |
| Dependent | 3 (7.14) | 3 (15.0) | |

Abbreviations: CCI, Charlson Comorbidity Index; CFR-PEEK, carbon fiber-reinforced polyetheretherketone; ECOG, Eastern Cooperative Oncology Group; SINS, spinal instability neoplastic score.
[a]Based on modified Tokuhashi scoring system.
[b]Based on ECOG score.
[c]$\chi^2$ test was performed.
[d]Mann-Whitney *U* test was performed.

Injury Association score improved by a minimum of 1 grade in 34 patients in titanium group and 17 patients in CFR-PEEK group. The mean number of vertebral levels covered by RT was 5.97 ± 2.40 in the titanium group and 5.50 ± 2.42 in the CFR-PEEK group ($P$ = 0.559). The mean volume of artifact generated during postoperative CT was 73.4 ± 50.3 $mm^3$ in the titanium group and 20.0 ± 20.7 $mm^3$ in the CFR-PEEK group. Mean time taken to contour the artifacts was 17.3 ± 5.84 minutes in the titanium group and 9.60 ± 7.17 minutes in the CFR-PEEK group ($P$ = 0.049). RT-related data are summarized in Table 3.

In 1 patient from the CFR-PEEK group, radiological evidence of suspected deep infection (hyperintensity near the affected pedicle) was detected at 4 weeks postoperatively. On clinical correlation, it was found to be a subclinical deep infection, which was treated conservatively with antibiotics. Tumor recurrence was not reported in any of the patients in both groups.

## DISCUSSION

Surgery followed by adjuvant RT is now the established gold standard for local tumor control in patients with MSD.[15] Proven good outcomes have been achieved with standard titanium implants.[15,16] CFR-PEEK implants have emerged as a promising alternative to traditional titanium screws for stabilization and reconstructive surgeries in MSD. The radiolucent nature of CFR-PEEK screws reduces the generation of artifacts, allowing for better utilization of contemporary imaging techniques as metal artifact reduction algorithms and dual-energy CT to further improve the image quality.[16–18]

Today there is sufficient data in the literature to support the clinical and radiological results of CFR-PEEK fixations as well as the acceptable biomechanical qualities with long-term stability.[19,20] In a cadaveric study to assess the biomechanical properties of CFR-PEEK vs titanium screws, Lindtner et al[11] assessed

**Table 2.** Surgical and operative results.

| Outcome Measure | Titanium | CFR-PEEK | *P* |
|---|---|---|---|
| Duration of operation, min, median (range) | 286 (94–726) | 270 (154–468) | 0.243[b] |
| Total length of stay, d, median (range) | 17 (5–62) | 10 (3–33) | 0.093[b] |
| Estimated blood loss, mL, median (range) | 500 (50–3500) | 275 (40–600) | 0.050[b] |
| No. of levels instrumented, median (range) | 5.00 (1.00–15.00) | 4.00 (2.00–7.00) | 0.007[b] |
| Cases where decompression was performed, *n* (%) | 32 (76.2) | 10 (50.0) | - |
| Number of levels decompressed, *n* (%) | | | 0.108[a] |
| 0 | 10 (23.8) | 10 (50.0) | |
| 1 | 9 (21.4) | 6 (30.0) | |
| 2 | 13 (31.0) | 2 (10.0) | |
| 3 | 7 (16.7) | 2 (10.0) | |
| 4 | 3 (7.1) | 0 (0) | |
| Number of levels decompressed, *n* (%) | | | 0.009 |
| <2 | 19 (45.2) | 16 (80.0) | |
| ≥2 | 23 (54.8) | 4 (20.0) | |
| Area of decompression, *n* (%) | | | - |
| Thoracic | 14 (33.3) | 6 (30.0) | |
| Thoracolumbar | 8 (19.0) | 1 (5.0) | |
| Lumbar | 6 (14.3) | 1 (5.0) | |
| Lumbosacral | 1 (2.4) | 1 (5.0) | |
| Sacral | 0 (0) | 0 (0) | |
| None | 13 (31.0) | 11 (55.0) | |
| Surgical complications, *n* (%) | 5 (22.7) | 3 (15) | - |
| Intraoperative incidental durotomy | 2 | 1 | |
| Delayed wound healing | 2 | 0 | |
| Superficial skin infection | 1 | 0 | |
| Deep surgical infection | 0 | 1 | |
| Hardware breakage (screw/rod) | 0 | 0 | |
| Screw loosening | 0 | 1 | |
| Medical complications, *n* (%) | 14 (33.3) | 2 (10.5) | 0.029[a] |
| Change in ASIA score, *n* (%) | | | 0.846[a] |
| Worsened | 0 (0) | 0 (0) | |
| No change | 8 (19.0) | 3 (15.0) | |
| Improved | 34 (81.0) | 17 (85.0) | |

Abbreviations: ASIA, American Spinal Injury Association; CFR-PEEK, carbon fiber-reinforced polyetheretherketone.
[a]$\chi^2$ test was performed.
[b]Mann-Whitney *U* test was performed.

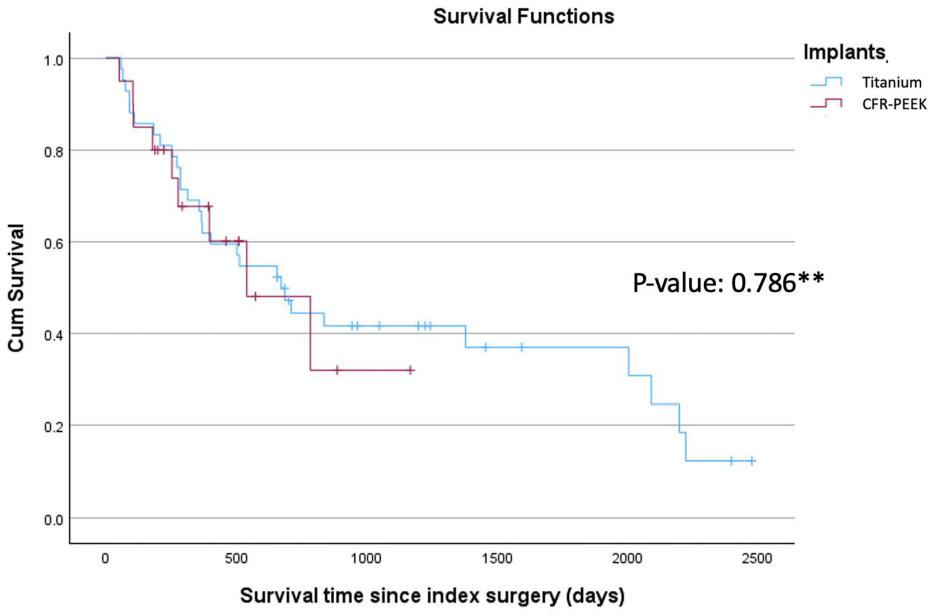


**** - Kaplan Meier curve and analysis were used**

**Figure 1.** Overall survival results.

**Table 3.** Radiotherapy data by study group.

| Parameter | Titanium | CFR-PEEK | *P* |
|---|---|---|---|
| Artifact volume, $mm^3$ | 73.4 ± 50.3 | 20.0 ± 20.7 | <0.001[a] |
| Artifact volume per level, $mm^3$ | 13.2 ± 8.81 | 3.35 ± 3.24 | <0.001[a] |
| Time taken to contour artifacts, min | 17.3 ± 5.84 | 9.60 ± 7.17 | 0.049[a] |
| No. of spinal levels covered for radiotherapy | 5.97 ± 2.40 | 5.50 ± 2.42 | 0.559[a] |

Abbreviation: CFR-PEEK, carbon fiber-reinforced polyetheretherketone.
*Note:* Data presented as mean ± SD.
[a]Mann-Whitney *U* test was performed.

screw loosening on cyclical loading of the spinal model and reported that CFR-PEEK pedicle screws were comparable to titanium screws in withstanding a similar number of load cycles until loosening. In 2 subsequent clinical studies, Boriani et al[3,4] reported preliminary data of CFR-PEEK in a series of 34 (14 metastatic and 20 primary) tumor patients. They discussed that reduced artifacts generation allowed for early identification of local recurrence in 6 patients (2 primary and 4 metastatic).

However, the existing studies did not provide a quantitative analysis of data related to RT planning.[19–21] In our study, the mean volume of artifact generated during postoperative CT was 73.4 ± 50.3 $mm^3$ in the titanium group and 20.0 ± 20.7 $mm^3$ in the CFR-PEEK group ($P < 0.001$; Figure 2). Mean time taken to contour the artifacts was 17.3 ± 5.84 minutes in the titanium group and 9.60 ± 7.17 minutes in the CFR-PEEK group ($P = 0.049$). This adds an objective dimension to the study, enhancing our understanding of the challenges posed by metallic implants in RT planning. The minimal artifacts associated with radiolucent CFR-PEEK implants streamline the contouring process, improving workflow efficiency, reducing patient wait times, and allowing for quicker commencement of adjuvant RT. This efficiency optimizes treatment outcomes and possibly enhances overall patient care in the management of MSD.

In our study, we reported that both groups had similar clinical outcomes for pain and overall survival ($P > 0.05$). Median blood loss was 500 mL for the titanium group and 275 mL for the CFR-PEEK group, and the duration of surgery was longer for patients in the titanium group than in the CFR-PEEK group. This could largely be attributed to the fact that patients in the

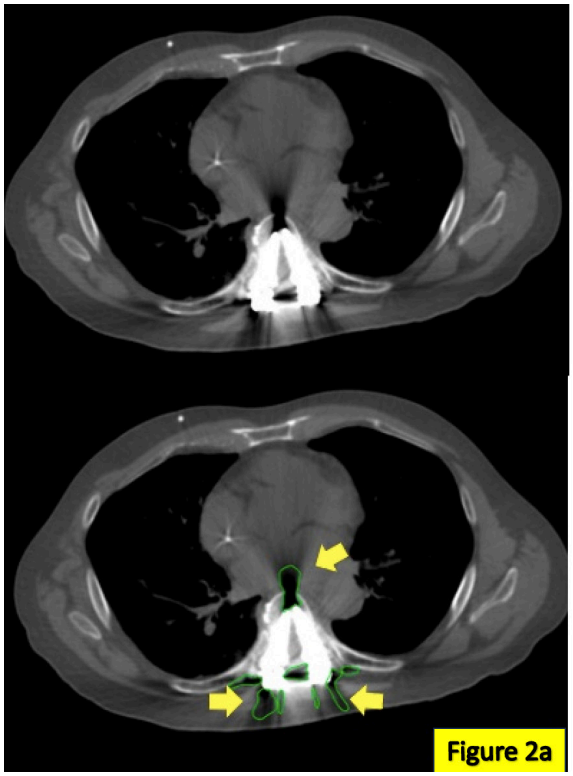


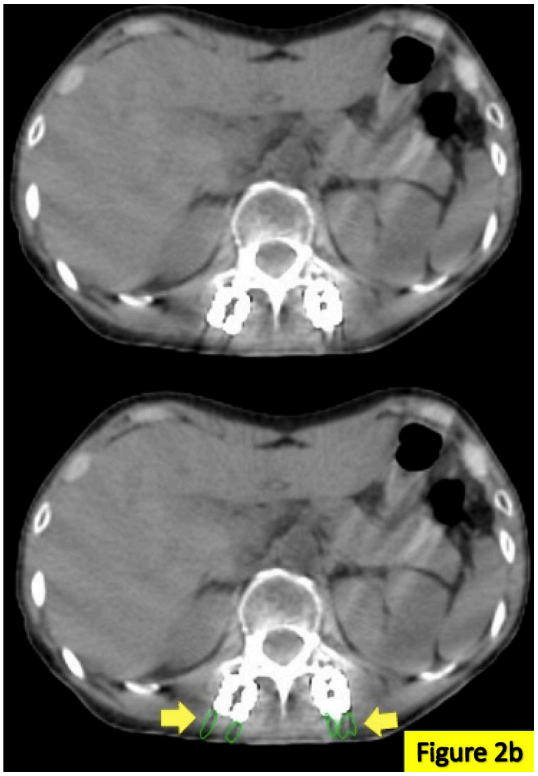


**Figure 2.** Sample computed tomography imaging. (a) Axial CT section at the T7 vertebra with bilateral titanium pedicle screw instrumentation. Note the increased artifact generated. (b) Axial CT section at L1 vertebra with carbon fiber–reinforced polyetheretherketone pedicle screws. Note minimal artifact generated.

titanium group required higher mean levels of instrumentation as compared with the CFR-PEEK group ($P$ = 0.007). However, the estimated blood loss in our cohort was comparable to that published previously by our institution.[22] No implant-related complications were encountered in the present study; this could be due to the relatively small sample size. We intend to continue this study with a bigger sample size to corroborate our findings from this early comparative study.

The overall prognosis and survivability of patients with MSD are multifactorial, influenced by the primary tumor, the extent of disease burden, and, most importantly, the patient's general health at the time of surgery. Surgical interventions with minimally invasive or open techniques can improve quality of life and pain management, but long-term survival largely depends on the systemic control of the primary malignancy and the patient's response to treatment.[23,24] This study aimed to emphasize the importance of carbon-fiber reinforced screws, not as a means to extend survival, but as a tool to amplify the potential for adjuvant RT and for effective surveillance of tumor recurrence postsurgery. These radiolucent implants allow for accurate radiation therapy planning, clear visualization of tumor margins, early detection of recurrences, and timely intervention when necessary. However, they represent just one of the many factors that contribute to the overall prognosis of the patient.

### Limitations

The relatively small sample size is the primary limitation of the study. Second, the patients were not randomized to the implant of choice for metastatic spine tumor surgeries. The choice of implant and subsequent patient allocation to the groups were vastly influenced by the patient's decision after a thorough procedural informed consent.

However, to the best of our knowledge, this is the first study to provide objectively measured radio-oncological data in terms of artifact generated by the implants during postoperative scans and the time spent on contouring them. This gives a more accurate validation in terms of establishing the superiority of the CFR-PEEK implants in postoperative RT in management of MSD.

## CONCLUSION

Our comparative study confirms that CFR-PEEK screws significantly reduce artifact generation and the time taken to contour them during postoperative RT planning while delivering equivalent clinical and functional outcomes as compared with conventional titanium implants. This suggests that they have a promising advantage over the titanium screws in metastatic spine tumor surgeries.

## ACKNOWLEDGMENTS

1. We acknowledge the AO Technical Commission Spine, Fracture, Tumor and Deformity Expert Group for facilitating numerous discussions, which allowed for the contrivance of this research question and subsequent manuscript.
2. We extend our special thanks to our research assistant, Mr Renick Lee, for his dedicated time and effort in critically reviewing our manuscript before submission.
3. We also acknowledge the scientific and engineering team from icotec Medical for their continued interaction with A/Prof Naresh Kumar for developing the concepts for the manuscript.

## REFERENCES

1. Krätzig T, Mende KC, Mohme M, et al. Carbon fiber-reinforced PEEK versus titanium implants: an in vitro comparison of susceptibility artifacts in CT and MR imaging. *Neurosurg Rev*. 2021;44(4):2163–2170. doi:10.1007/s10143-020-01384-2

2. Patchell RA, Tibbs PA, Regine WF, et al. Direct decompressive surgical resection in the treatment of spinal cord compression caused by metastatic cancer: a randomised trial. *The Lancet*. 2005;366(9486):643–648. doi:10.1016/S0140-6736(05)66954-1

3. Boriani S, Pipola V, Cecchinato R, et al. Composite PEEK/carbon fiber rods in the treatment for bone tumors of the cervical spine: a case series. *Eur Spine J*. 2020;29(12):3229–3236. doi:10.1007/s00586-020-06534-0

4. Boriani S, Tedesco G, Ming L, et al. Carbon-fiber-reinforced PEEK fixation system in the treatment of spine tumors: a preliminary report. *Eur Spine J*. 2018;27(4):874–881. doi:10.1007/s00586-017-5258-5

5. Müller BS, Ryang Y-M, Oechsner M, et al. The dosimetric impact of stabilizing spinal implants in radiotherapy treatment planning with protons and photons: standard titanium alloy vs. radiolucent carbon-fiber-reinforced PEEK systems. *J Appl Clin Med Phys*. 2020;21(8):6–14. doi:10.1002/acm2.12905

6. Spratt DE, Beeler WH, de Moraes FY, et al. An integrated multidisciplinary algorithm for the management of spinal metastases: an international spine oncology consortium report. *Lancet Oncol*. 2017;18(12):e720–e730. doi:10.1016/S1470-2045(17)30612-5

7. Ringel F, Ryang Y-M, Kirschke JS, et al. Radiolucent carbon fiber–reinforced pedicle screws for treatment of spinal tumors: advantages for radiation planning and follow-up imaging. *World Neurosurg*. 2017;105:294–301. doi:10.1016/j.wneu.2017.04.091

8. Bar-Deroma R, Nevelsky A. Perturbation effects of the carbon fiber-PEEK screws on radiotherapy dose distribution. *J Appl Clin Med Phys*. 2017;18(2):62–68. doi:10.1002/acm2.12046

9. Alvarez-Breckenridge C, de Almeida R, Haider A, et al. Carbon fiber-reinforced polyetheretherketone spinal implants for treatment of spinal tumors: perceived advantages and limitations. *Neurospine*. 2023;20(1):317–326. doi:10.14245/ns.2244920.460

10. Cofano F, Di Perna G, Monticelli M, et al. Carbon fiber reinforced vs titanium implants for fixation in spinal metastases: a comparative clinical study about safety and effectiveness of the new "carbon-strategy." *J Clin Neurosci*. 2020;75:106–111. doi:10.1016/j.jocn.2020.03.013

11. Lindtner RA, Schmid R, Nydegger T, Konschake M, Schmoelz W. Pedicle screw anchorage of carbon fiber-reinforced PEEK screws under cyclic loading. *Eur Spine J*. 2018;27(8):1775–1784. doi:10.1007/s00586-018-5538-8

12. Fisher CG, DiPaola CP, Ryken TC, et al. A novel classification system for spinal instability in neoplastic disease: an evidence-based approach and expert consensus from the spine oncology study group. *Spine*. 2010;35(22):E1221–E1229. doi:10.1097/BRS.0b013e3181e16ae2

13. Charlson ME, Carrozzino D, Guidi J, Patierno C. Charlson comorbidity index: a critical review of clinimetric properties. *Psychother Psychosom*. 2022;91(1):8–35. doi:10.1159/000521288

14. Tokuhashi Y, Matsuzaki H, Oda H, Oshima M, Ryu J. A revised scoring system for preoperative evaluation of metastatic spine tumor prognosis. *Spine*. 2005;30(19):2186–2191. doi:10.1097/01.brs.0000180401.06919.a5

15. Kumar N, Tan JH, Thomas AC, et al. The utility of "minimal access and separation surgery" in the management of metastatic spine disease. *Glob Spine J*. 2023;13(7):1793–1802. doi:10.1177/21925682211049803

16. Kumar N, Ramakrishnan SA, Lopez KG, et al. Can polyether ether ketone dethrone titanium as the choice implant material for metastatic spine tumor surgery? *World Neurosurg*. 2021;148:94–109. doi:10.1016/j.wneu.2021.01.059

17. Yazici G, Sari SY, Yedekci FY, et al. The dosimetric impact of implants on the spinal cord dose during stereotactic body radiotherapy. *Radiat Oncol*. 2016;11(1). doi:10.1186/s13014-016-0649-z

18. Mastella E, Molinelli S, Magro G, et al. Dosimetric characterization of carbon fiber stabilization devices for post-operative particle therapy. *Phys Med*. 2017;44:18–25. doi:10.1016/j.ejmp.2017.11.008

19. Fujihara K, Huang Z-M, Ramakrishna S, Satknanantham K, Hamada H. Feasibility of knitted carbon/PEEK composites for orthopedic bone plates. *Biomaterials*. 2004;25(17):3877–3885. doi:10.1016/j.biomaterials.2003.10.050

20. Hak DJ, Mauffrey C, Seligson D, Lindeque B. Use of carbon-fiber-reinforced composite implants in orthopedic surgery. *Orthopedics*. 2014;37(12):825–830. doi:10.3928/01477447-20141124-05

21. Neal MT, Richards AE, Curley KL, et al. Carbon fiber-reinforced PEEK instrumentation in the spinal oncology population: a retrospective series demonstrating technique, feasibility, and clinical outcomes. *Neurosurg Focus*. 2021;50(5). doi:10.3171/2021.2.FOCUS20995

22. Kumar N, Zaw AS, Khine HE, et al. Blood loss and transfusion requirements in metastatic spinal tumor surgery: evaluation of influencing factors. *Ann Surg Oncol*. 2016;23(6):2079–2086. doi:10.1245/s10434-016-5092-8

23. Kumar N, Hui SJ, Lee R, Athia S, Rothenfluh DA, Tan JH. Implant and construct decision-making in metastatic spine tumour surgery: a review of current concepts with a decision-making algorithm. *Eur Spine J*. 2024;33(5):1899–1910. doi:10.1007/s00586-023-07987-9

24. Tan JHJ, Hallinan J, Lee R, et al. Trends in surgical management of spinal metastases in a singaporean tertiary referral center: a 17-year retrospective review. *Front Oncol*. 2023;13. doi:10.3389/fonc.2023.1297553

**Funding:** The authors received no financial support for the research, authorship, and/or publication of this article.

**Declaration of Conflicting Interests:** The authors report no conflicts of interest in this work.

**Disclosures:** The authors have no relevant disclosures. Naresh Kumar is a member of the Fracture, Tumor, and Deformity Expert Group of the AO Technical Commission Spine.

**Author Contributions:** Naresh Kumar: Made substantial contributions to the conception and design of the work; revised the manuscript critically for intellectual content. Priyambada Kumar: Collected data for the study; drafted and edited the final manuscript. Gabriel Leow Zihu: Collected data for the study. Leon Seow: Collected radiotherapy related data in the study. Shen Liang: Performed statistical analysis for the study. Si Jian Hui: Critically reviewed the manuscript. Rohan Parihar: Critically reviewed the manuscript. James Hallinan: Helped in analysis of the CT imaging pre- and postoperatively. Balamurugan A Vellayappan: Analyzed radiotherapy-related data for the study. Tan Jiong Hao Jonathan: Critically reviewed the manuscript. All authors approved the version to be published and agree to be accountable for all aspects of the work in ensuring that questions related to the accuracy or integrity of any part of the work are appropriately investigated and resolved.

**Ethics Approval:** Ethical Committee approval was sanctioned from the Institutional Review Board.

**Corresponding Author:** Naresh Kumar, Department of Orthopaedic Surgery (Spine Division), National University Hospital, Singapore NUHS Tower Block, Level 11, 5 Lower Kent Ridge Road, Singapore 119228, Singapore; dosksn@nus.edu.sg

Published 06 November 2024