

Are the Umbilicus and Iliac Crests Truly at the Level of L4 to L5? A Computed Tomography-Based Study of Surface Anatomy of the Anterior Lumbar Spine

David Shin, Kai Nguyen, Easton Small, Trevor Case, Mikayla Kricfalusi, Alexander Bouterse, Andrew Cabrera, Ethan Purnell, Wheddy Laguerre, Jacob Razzouk, Omar Ramos, Olumide Danisa and Wayne Cheng

Int J Spine Surg 2024, 18 (6) 660-666

doi: <https://doi.org/10.14444/8651>

<https://www.ijssurgery.com/content/18/6/660>

This information is current as of January 3, 2025.

Email Alerts Receive free email-alerts when new articles cite this article. Sign up at:
<http://ijssurgery.com/alerts>

Are the Umbilicus and Iliac Crests Truly at the Level of L4 to L5? A Computed Tomography-Based Study of Surface Anatomy of the Anterior Lumbar Spine

DAVID SHIN, BS¹; KAI NGUYEN, BS¹; EASTON SMALL, BS¹; TREVOR CASE, BS²; MIKAYLA KRICFALUSI, BS²; ALEXANDER BOUTERSE, BS¹; ANDREW CABRERA, BS¹; ETHAN PURNELL, BS¹; WHEDDY LAGUERRE, BS¹; JACOB RAZZOUK, BS¹; OMAR RAMOS, MD³; OLUMIDE DANISA, MD⁴; AND WAYNE CHENG, MD⁵

¹School of Medicine, Loma Linda University, Loma Linda, CA, USA; ²School of Medicine, California University of Science and Medicine, Colton, CA, USA; ³Department of Orthopedic Surgery, Twin Cities Spine Center, Minneapolis, MN, USA; ⁴Department of Orthopaedic and Neurological Surgery, Duke University Healthcare Center, Durham, NC, USA; ⁵Division of Orthopedic Surgery, Jerry L Pettis Memorial Veterans Hospital, Loma Linda, CA, USA

ABSTRACT

Background: This study aimed to determine whether the iliac crests are truly at the level of L4 to L5, accounting for patient demographic and anthropometric characteristics.

Methods: We measured the umbilicus and iliac crests relative to the lumbar spine using computed tomography of patients without spinal pathology, accounting for the influences of patient height, weight, body mass index (BMI), sex, race, and ethnicity.

Results: A total of 834 patients (391 men and 443 women) were reviewed. The location of the umbilicus relative to the lumbar spine demonstrated a unimodal distribution pattern clustered at L4, while the iliac crests were most frequently located from L4 to L5. Iliac crests were located above the L4 to L5 disc space 26.5% of the time. Iliac crests were located at the L4 to L5 disc space 29.8% of the time. No correlations were observed between the umbilicus and iliac crests with patient height, weight, or BMI. There was no difference in the location of the umbilicus with respect to patient sex, race, and ethnicity. The locations of the iliac crests were cephalad in women compared with men and in Hispanics compared with African American, Caucasian, and Asian patients.

Conclusions: The iliac crests were located above the level of the L4 to L5 disc space approximately 26% of the time. The umbilicus is most frequently at the level of the L4 vertebral body. Patient height, weight, and BMI do not influence the location of the umbilicus or the iliac crests relative to the lumbar spine. Patient sex and ethnicity influence the location of the iliac crests but not the umbilicus relative to the lumbar spine.

Clinical Relevance: Modern neurosurgical techniques require clearance of the iliac crests during anterior and anterolateral approaches. Understanding the level of the iliac crests is crucial in planning for transposas fusion approaches.

Level of Evidence: 2.

Lumbar Spine

Keywords: anatomic, computed tomography, ethnicity, iliac crest, race

INTRODUCTION

Understanding the location of surface anatomical landmarks in relation to the lumbar spine is important for a wide array of clinical applications.¹ Anatomic studies of surface landmarks were first conducted in cadaveric models. However, the most prominent drawback of this methodology was the potential for anatomic distortion due to advanced age, comorbidity, postmortem changes, and embalming.² With the modern availability of advanced imaging, there is a need to re-assess surface anatomy in vivo with the higher precision and controlled settings afforded by standardized imaging techniques.

During the transposas interbody fusion technique, the relationship between the iliac crests and the targeted disc space becomes important. For anterior lumbar interbody fusion, the relationship between the umbilicus and patient body habitus becomes important. Several imaging-based studies have investigated the surface landmarks of the umbilicus and iliac crests in relation to the lumbar spine.^{3–10} While some of these studies have accounted for the influence of factors such as patient sex,^{3,4,7} numerous studies cite the need for additional research accounting for the influence of other variables such as patient ethnicity, height, and weight.^{3–6,8,11,12} The aim of this study was to measure the locations of the iliac crests and umbilicus relative to the lumbar

spine using computed tomography (CT) of patients without spinal pathology, accounting for patient demographic and anthropometric characteristics.

METHODS

Following Institutional Review Board approval (#5230005), we performed a radiographic analysis of patients aged between 18 and 35 years who underwent abdominal CT (GE Discovery 750 HD 64 slice CT Scanner) between March 2020 and January 2023. Patient consent was not required due to the nature of this retrospective, radiographic study. All patients for possible inclusion within the study were reviewed in a systematic order corresponding to the chronological sequence in which their imaging was completed. All patients demonstrated clear axial and sagittal CT imaging and were reviewed with a window designation of 2000 Hounsfield units and a level designation of 500 Hounsfield units. Patients with a history of kyphosis, scoliosis, organomegaly, spondylolisthesis, spinal trauma, neoplasm, spine surgery, infection, or malignancy were excluded from the review. Patients for whom only the umbilicus or iliac crest(s) was visible on CT were still included for review. Radiographic, demographic, and anthropometric data were retrieved using IMPAX6 (Agfa-Gavaert, Mortsel, Belgium) picture archiving and communication system. Anthropometric data were composed of patient weight, height, and body mass index (BMI), and patient demographic data consisted of patient age, race, and ethnicity.

Data Gathering

Measurements were performed by medical students trained by a board-certified neuroradiologist to measure the umbilicus and iliac crests in relation to the lumbar spine. This study used measurement techniques similar to those of previous studies, which demonstrated excellent inter- and intrarater reliability.^{3,5,8,12,13} Interobserver reliability was assessed via the intraclass correlation coefficient (ICC) 2-way mixed model on the absolute agreement. ICC was defined as poor, fair, good, or excellent based on threshold values of <0.40, 0.40 to 0.59, 0.60 to 0.74, and >0.75, respectively.¹⁴⁻¹⁶ For the first 200 patients, each CT scan was measured by 2 medical students, as well as verified by the neuroradiologist, to assess ICC. After evaluating the reliability of the measurements performed on the first 200 patients, the ICC was found to be excellent. The remaining measurements were allowed to be performed by 1 reviewer per CT scan. To measure the location of

the umbilicus relative to the spine, a horizontal line was drawn between the umbilicus and corresponding vertebral level in the midsagittal plane. To measure each iliac crest in relation to the lumbar spine, a horizontal line was drawn connecting the superior aspect of the iliac crest and the lumbar spine as viewed in the sagittal plane. While all measurements were performed from the sagittal view, axial and coronal planes were utilized for orientation and visualization of anatomic structures. Additionally, sagittal measurements were verified in the axial and coronal planes to assess for accuracy regarding off-plane measurements.

Statistical Analysis

All statistical analyses were performed using SPSS version 28 (IBM Corporation, 2021, Armonk, NY, USA) with an alpha setting of 0.05 denoting statistical significance. Homoscedasticity was evaluated with regression residual plots and homogeneity of variance tests.¹⁷ To review the normality of the data, Kolmogorov-Smirnov tests and Q-Q plots were assessed.^{18,19} To evaluate associations among radiographic, demographic, and anthropometric variables, Pearson's correlation tests and enter-method univariate linear regression models were constructed. For the purposes of avoiding collinearity with patient height and weight, BMI was omitted from all regression modeling. Correlation coefficients and regression models were classified as weak, moderate, and strong, which corresponded to value ranges of 0–0.3, 0.3–0.7, and 0.7–1, respectively.^{20,21} Differences in the location of anatomical landmarks based on patient sex were analyzed using independent sample *t* tests with Levene's test for equality of variance.²² To assess for differences based on race and ethnicity, a 1-way analysis of variance with post hoc Bonferroni and Tukey corrections was performed.

RESULTS

Cohort Descriptives

Our study evaluated a total of 1051 CT scans, of which 217 were excluded. Of those excluded, 91 had poor or insufficient imaging, 33 had scoliosis, 29 had previous spinal surgery, 24 had spondylolisthesis, 20 had kyphosis, 19 had spinal trauma, and 1 had infection. Of the remaining 834 patients included in this study, 391 were men and 443 were women. Mean patient height was 1.58 ± 0.13 m (range, 1.26 to 1.87 m); weight, 81.19 ± 23.90 kg (range, 31.10 to 211.90 kg); BMI, 28.39 ± 7.8 kg/m² (range, 15.15 to 68.17 kg/m²); and age, 27.2 ± 4.6 years (range, 18 to 35 years). Of the

834 patients, 334 were Hispanic or Latino, 298 were Caucasian, 81 were African American, 64 were Asian, 9 were identified as “other,” and 48 did not have racial or ethnic data available.

Umbilicus

The location of the umbilicus in relation to the lumbar spine demonstrated a unimodal distribution pattern clustered at L4 (Figure 1). No significant correlations were observed between the location of the umbilicus relative to the lumbar spine and patient height ($r = -0.126$; $P = 0.559$), weight ($r = 0.035$; $P = 0.391$), or BMI ($r = 0.073$; $P = 0.084$). There was no difference in the location of the umbilicus relative to the lumbar spine with respect to patient sex ($P = 0.423$; Figure 2). No differences based on ethnicity were observed with respect to the location of the umbilicus in relation to the lumbar spine ($P = 0.377$; Figure 3).

Iliac Crests

The iliac crests were most commonly observed from L4 to L5 (Figure 4 and Figure 5). No significant

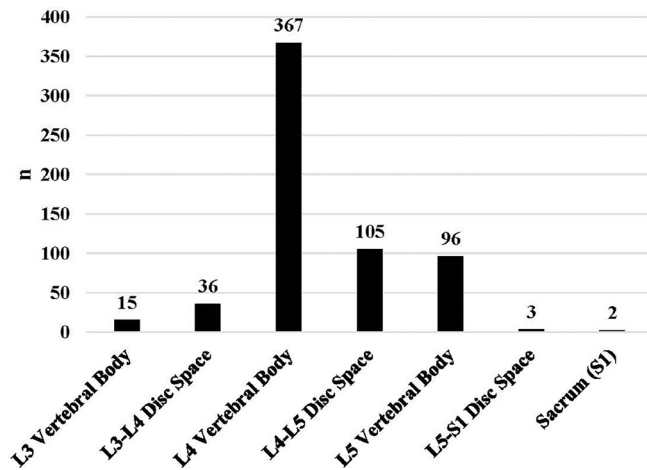


Figure 1. Location of the umbilicus in relation to the lumbar spine ($n = 624$).

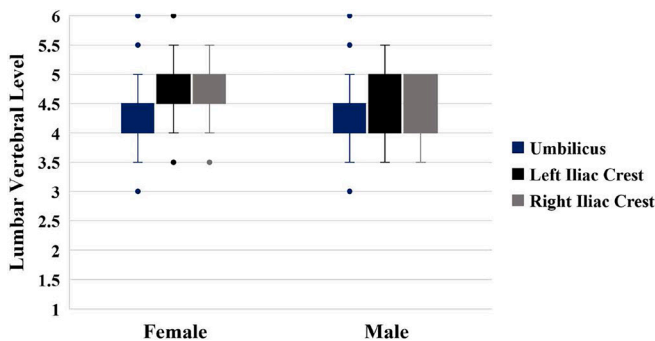


Figure 2. Influence of patient sex on the location of the umbilicus and iliac crests in relation to the lumbar spine.

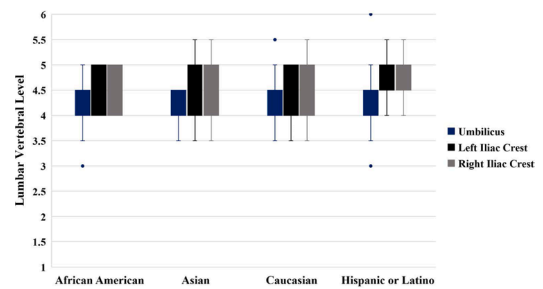


Figure 3. Influence of race and ethnicity on the location of the umbilicus and iliac crests in relation to the lumbar spine.

correlations were observed between the location of the left iliac crest relative to the lumbar spine and patient height ($r = -0.226$; $P = 0.744$), weight ($r = -0.071$; $P = 0.791$), or BMI ($r = 0.035$; $P = 0.823$). Similarly, no significant correlations were observed between the right iliac crest and patient height ($r = -0.272$; $P = 0.365$), weight ($r = -0.049$; $P = 0.222$), or BMI ($r = 0.121$; $P = 0.856$). A moderate correlation was observed between the location of the left and right iliac crest ($r = 0.698$; $P < 0.001$). The location of the iliac crests was more cephalad in women compared with men on both left ($P < 0.001$) and right ($P < 0.001$) sides (see Figure 2). Hispanics demonstrated more cephalad locations of the iliac crests compared with African American ($P < 0.001$), Caucasian ($P < 0.001$), and Asian patients ($P < 0.001$), while no other differences based on race and ethnicity were observed with respect to the location of the iliac crests in relation to the lumbar spine (see Figure 3). The Table reports the enter-method linear regression modeling accounting for patient sex, ethnicity, height, and weight in relation to the umbilicus and

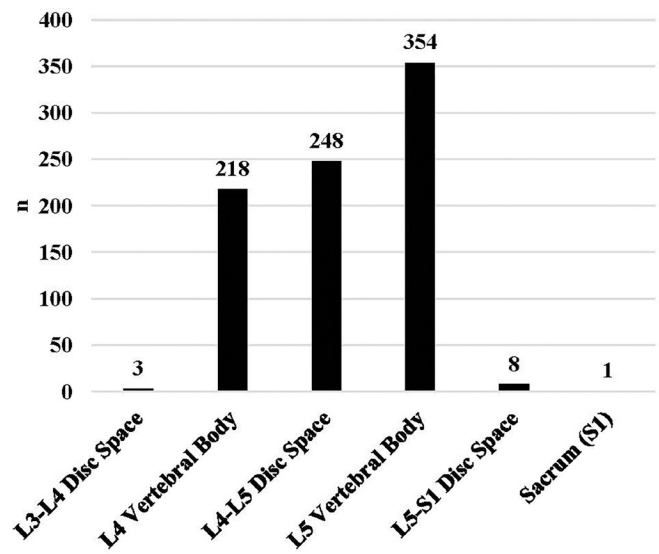


Figure 4. Location of the left iliac crest in relation to the lumbar spine ($n = 832$).

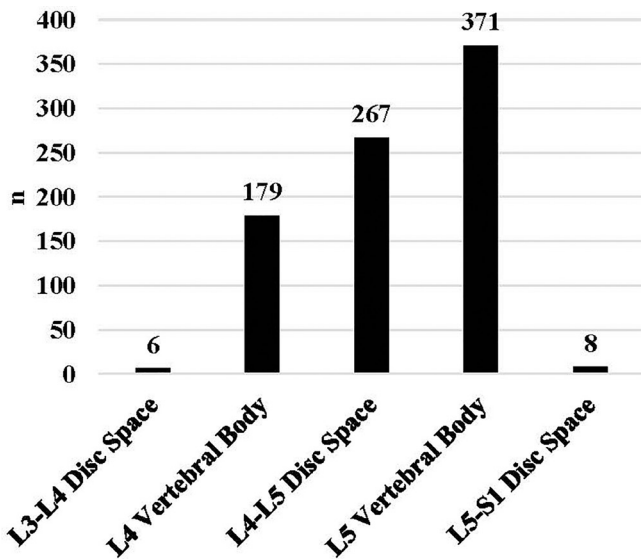


Figure 5. Location of the right iliac crest in relation to the lumbar spine (n = 831).

iliac crests. All 3 regression models demonstrated weak performance based on the defined categorization of 0 to 0.3 used in this study.

DISCUSSION

Clinical and Surgical Considerations

Our findings prompt several clinical and surgical considerations. More than 26% of the time, the iliac crests were identified above the level of the L4 to L5 disc space, while iliac crests were located at the L4 to L5 disc space 29.8% of the time. This is an important consideration for spine surgeons during approach access in procedures such as transposas interbody fusion at the L4 to L5 disc space.^{19,22} Correspondingly, more than 26% of the time, the surgeon would have to manipulate the patient’s body positioning or use angled instruments to overcome the high-riding iliac crests.

It is important to keep in mind that while the umbilicus is frequently associated with the T10 dermatome,

our findings suggest that this landmark corresponds to the level of the L4 vertebral body with the exception of extremes. Regarding these exceptions, all 5 patients in this study possessing an umbilicus below the level of L5 demonstrated excessive panniculus. Logically, one may intuit that patients with prominent panniculus may have an umbilicus below the level of L4 due to the drooping of the fatty apron. Correspondingly, even though weight or BMI were not directly associated with umbilicus location, this does not mean there are no outliers at the extremes of this continuum. Notwithstanding, this study suggests that weight, height, BMI, ethnicity, and sex generally do not influence the vertebral level of the umbilicus—evidenced by the poor correlations and inability of regression modeling to significantly account for the level of the umbilicus based on these factors.

On the other hand, the findings of this study demonstrate that ethnicity influences the position of the iliac crests, while height, weight, BMI, and sex are not associated with the iliac crests’ location relative to the lumbar spine. Interestingly, the locations of the left and right iliac crests were only moderately correlated with each other ($r = 0.698$), which underscores the fact that patient anatomy is not always symmetrical, even in a young adult population free of pathology. Whereas the left iliac crest is above the level of the L4 to L5 disc space 26% of the time, the right iliac crest can be relatively caudal, being above the level of the L4 to L5 disc space 22% of the time.

Influence of Race and Ethnicity

To the best of the authors’ knowledge, this is the largest study to date investigating the anatomic locations of the umbilicus and iliac crests and the first to describe these landmarks in Hispanic and African American populations. It is crucial to conduct a thorough and repeated study of surface anatomical landmarks if they are to have clinical utility. This is especially true given the countless anatomic variations that exist throughout the human population. Numerous studies of large cohorts are thus necessary to ensure the generalizability of anatomic rules of thumb and to make certain that anatomic variations are captured across populations. Our overall observations are aligned with the present literature in that the locations of the iliac crests correspond to the L4 to L5 region and the umbilicus to the L4 vertebral level.^{4,5,8,9,23} Nevertheless, while previous studies have investigated the location of umbilicus and iliac crest landmarks, many were almost entirely composed of patients from European ancestral origin.^{4,5,8,9} Our findings contribute to the literature that

Table. Enter-method linear regression modeling of patient height, weight, sex, and ethnicity in relation to the umbilicus and iliac crests.

Metric	Umbilicus	Left Iliac Crest	Right Iliac Crest
ANOVA P value	0.002	<0.001	<0.001
R ²	0.057	0.120	0.109
SE	0.472	0.400	0.396
Constant	4.878	5.174	5.612
B coefficient—height	-0.489	-0.357	-0.662
B coefficient—weight	0.003	0.001	0.001
B coefficient—sex	-0.075	-0.245	-0.168
B coefficient—ethnicity	-0.038	0.023	0.035

Abbreviation: ANOVA, analysis of variance.

the vertebral level of the umbilicus does not vary based on ethnic background, but the iliac crests from those of Hispanic ethnicity are relatively caudal compared with those of Caucasian, African American, or Asian background. Among those of Caucasian, African American, and Asian descent, there is no difference.

Influence of Sex

Snider et al found the superior iliac crests most often correspond to the level of L4 in men and the level of L5 in women.¹³ Both Uzun et al and Mirjalili et al found the iliac crests to lie most commonly at the L4 vertebral level and did not find any significant relationship between the vertebral level of the iliac crests and patient sex.^{6,11} Our findings, as well as those from several other studies, corroborate the hypothesis that men demonstrate relatively cephalad locations of the iliac crests compared with women.^{3,24–27} Our study, however, suggests slightly different parameters for the most common vertebral level of the iliac crests. While we did frequently observe the iliac crests at the level of L4, the L5 level was a more common location on both the left and right sides. This discrepancy may be credited to the higher granularity of detail that was afforded by our sample size. With respect to the umbilicus, the literature is limited in assessing differences in positioning based on patient sex. Our study suggests that there is no difference based on patient sex with respect to the vertebral level corresponding to the umbilicus.

Influence of Height, Weight, and BMI

Our study did not find height, weight, or BMI to be associated with the location of the iliac crests relative to the lumbar spine. Snider et al also found no correlation between weight or BMI and the location of the iliac crests in relation to the lumbar spine,¹³ and other studies have posited similar conclusions.^{5,7} It is important to keep in mind, however, that physical palpation of the iliac crests corresponds to a spine level 1 vertebrae cephalad to the spine level identified via imaging.^{4,7} While the iliac crests radiographically correspond to the region of L4 to L5, upon palpation they correspond to the level of L3 to L4 due to the cushioning effect of subcutaneous tissue between the bony iliac surface and the palpating hand.^{3,7,28} Therefore, in the setting of clinical palpation, it is more appropriate to consider the iliac crests as a guide for identifying the L3 to L4 region rather than the L4 to L5 region, particularly in women and/or patients with higher BMI.^{4,29–32} Accordingly, it is important to qualify that our findings suggest that BMI does not affect the measured radiographic vertebral

level of the iliac crests, though it is well-established that BMI does affect measurements derived from palpation.

Our study did not find height to be correlated with either umbilicus or iliac crest locations relative to the spine. In contrast, Pysyk et al found that a palpated intercrystal line—the line formed between the superior-most aspects of the iliac crests—at L2 to L3 was more likely in tall and male individuals.¹² This discrepancy may be due to our larger sample size and more rigorous statistical analysis. The more cephalad positioning of the iliac crests observed in the Pysyk et al study may be due to the confounding influence of patient sex rather than strictly patient height.

Limitations

Our study must be viewed in light of several limitations. First, our study was solely composed of patients between the ages of 18 and 35 who demonstrated zero spinal pathology. Although age has previously been found to be an insignificant factor in influencing the location of the iliac crests in relation to the lumbar spine,^{27,33,34} it is nevertheless important to recognize the impact of our study design on its generalizability. Our study may also be limited in its generalizability to clinical situations where identifying the correct spinal level might be complicated by sacralization or lumbalization of the lower spine, spondylolisthesis, lumbar scoliosis, or loss of vertebral height. Nevertheless, the pros of using a young adult population still outweigh the cons as this study design allows for providing reference values that may be equidistant in their application to a broad range of patient presentations. In this way, a surgeon may use the values in this study as frames of reference that may be adjusted based on individual patient presentations.

Furthermore, it is reasonable to question whether our findings are translatable in settings where patients are not in the supine position as assumed during imaging. While it has been demonstrated that positioning of patients in a sitting or lateral position may cause minor shifts in the location of the iliac crests, these changes are not clinically significant because they are minuscule and do not cause shifts beyond 1 disc space or vertebral level.^{4,7,13,35–37}

CONCLUSION

This study demonstrates that the iliac crests were located above the level of the L4 to L5 disc space approximately 26% of the time, which is crucial in the surgical planning for transposas fusion approach. The

location of the umbilicus is most frequently at the level of the L4 vertebral body. Patient height, weight, and BMI do not influence the location of the umbilicus or the iliac crests relative to the lumbar spine. Patient sex and ethnicity influence the location of the iliac crests but do not influence the location of the umbilicus relative to the lumbar spine.

REFERENCES

1. Gray's A. 39th edition: the anatomical basis of clinical practice. *AJNR Am J Neuroradiol*. 2005;26(10):2703–2704.
2. Ruggles G. Topography of the unpaired visceral branches of the abdominal aorta. *J Anat*. 1935;69(Pt 2):196–205. <https://pubmed.ncbi.nlm.nih.gov/17104532/>.
3. Kim JT, Bahk JH, Sung J. Influence of age and sex on the position of the conus medullaris and tuffier's line in adults. *Anesthesiology*. 2003;99(6):1359–1363. doi:10.1097/0000542-200312000-00018
4. Chakraverty R, Pynsent P, Isaacs K. Which spinal levels are identified by palpation of the iliac crests and the posterior superior iliac spines? *J Anat*. 2007;210(2):232–236. doi:10.1111/j.1469-7580.2006.00686.x
5. Ali Mirjalili S, McFadden SL, Buckenham T, Stringer MD. A reappraisal of adult abdominal surface anatomy. *Clin Anat*. 2012;25(7):844–850. doi:10.1002/ca.22119
6. Uzun C, Atman ED, Ustuner E, Mirjalili SA, Oztuna D, Esmer TS. Surface anatomy and anatomical planes in the adult turkish population. *Clin Anat*. 2016;29(2):183–190. doi:10.1002/ca.22634
7. Cooperstein R, Truong F. Systematic review and meta-analyses of the difference between the spinal level of the palpated and imaged iliac crests. *J Can Chiropr Assoc*. 2017;61(2):106–120.
8. Goyal R, Aggarwal A, Gupta T, et al. Reappraisal of the classical abdominal anatomical landmarks using in vivo computerized tomography imaging. *Surg Radiol Anat*. 2020;42(4):417–428. doi:10.1007/s00276-019-02326-4
9. Walsh JC, Quinlan JF, Butt K, Towers M, Devitt AT. Variation in position of the L4/5 disc inter-space from the anatomical landmark: review of 450 radiographs and clinical applications. *Eur J Orthop Surg Traumatol*. 2006;16(3):203–206. doi:10.1007/s00590-005-0075-7
10. Wattanaruangkowit P, Lakchayapakorn K. The position of the lumbar vertebrae in relation to the intercrestal line. *J Med Assoc Thai*. 2010;93(11):1294–1300.
11. Mirjalili SA, McFadden SL, Buckenham T, Wilson B, Stringer MD. Anatomical planes: are we teaching accurate surface anatomy? *Clin Anat*. 2012;25(7):819–826. doi:10.1002/ca.22104
12. Pysyk CL, Persaud D, Bryson GL, Lui A. Ultrasound assessment of the vertebral level of the palpated intercrestal (tuffier's) line. *Can J Anaesth*. 2010;57(1):46–49. doi:10.1007/s12630-009-9208-5
13. Snider KT, Kribs JW, Snider EJ, Degenhardt BF, Bukowski A, Johnson JC. Reliability of tuffier's line as an anatomic landmark. *Spine*. 2008;33(6):E161–E165. doi:10.1097/BRS.0b013e318166f58c
14. Fleiss J. Design and analysis of clinical experiments. In: Vol 73. John Wiley & Sons; 2011.
15. Shrout PE, Fleiss JL. Intraclass correlations: uses in assessing rater reliability. *Psychol Bull*. 1979;86(2):420–428. doi:10.1037//0033-2909.86.2.420
16. Koo TK, Li MY. A guideline of selecting and reporting intraclass correlation coefficients for reliability research. *J Chiropr Med*. 2016;15(2):155–163. doi:10.1016/j.jcm.2016.02.012
17. Parra-Frutos I. Testing homogeneity of variances with unequal sample sizes. *Comput Stat*. 2013;28(3):1269–1297. doi:10.1007/s00180-012-0353-x
18. Vetter TR. Fundamentals of research data and variables: the devil is in the details. *Anesth Analg*. 2017;125(4):1375–1380. doi:10.1213/ANE.0000000000002370
19. Razzouk J, Ramos O, Mehta S, et al. CT-based analysis of oblique lateral interbody fusion from L1 to L5: location of incision, feasibility of safe corridor approach, and influencing factors. *Eur Spine J*. 2023;32(6):1947–1952. doi:10.1007/s00586-023-07555-1
20. Ratner B. The correlation coefficient: its values range between +1/–1, or do they? *J Target Meas Anal Mark*. 2009;17(2):139–142. doi:10.1057/jt.2009.5
21. Razzouk J, Ramos O, Ouro-Rodrigues E, et al. Comparison of cervical, thoracic, and lumbar vertebral bone quality scores for increased utility of bone mineral density screening. *Eur Spine J*. 2023;32(1):20–26. doi:10.1007/s00586-022-07484-5
22. Razzouk J, Ramos O, Mehta S, et al. Anterior-to-psoas approach measurements, feasibility, non-neurological structures at risk and influencing factors: a bilateral analysis from L1-L5 using computed tomography imaging. *Oper Neurosurg*. 2023;25(1):52–58. doi:10.1227/ons.0000000000000696
23. Kuhns LR, Borlaza GS, Seigel R. External anatomic landmarks of the abdomen related to vertebral segments: applications in cross-sectional imaging. *Am J Roentgenol*. 1978;131(1):115–117. doi:10.2214/ajr.131.1.115
24. McGaugh JM, Brismée JM, Dedrick GS, Jones EA, Sizer PS. Comparing the anatomical consistency of the posterior superior iliac spine to the iliac crest as reference landmarks for the lumbopelvic spine: a retrospective radiological study. *Clin Anat*. 2007;20(7):819–825. doi:10.1002/ca.20531
25. Rahmani M, Vaziri Bozorg SM, Ghasemi Esfe AR, et al. Evaluating the reliability of anatomical landmarks in safe lumbar puncture using magnetic resonance imaging: does sex matter? *Int J Biomed Imaging*. 2011;2011. doi:10.1155/2011/868632
26. Margarido CB, Mikhael R, Arzola C, Balki M, Carvalho JCA. The intercrestal line determined by palpation is not a reliable anatomical landmark for neuraxial anesthesia. *Can J Anaesth*. 2011;58(3):262–266. doi:10.1007/s12630-010-9432-z
27. Horsanlı BÖ, Tekgül ZT, Özkalkanlı MY, Adıbelli ZH, Esen Ö, Duran FY. Radiological evaluation of the line between the crista iliaca (tuffier's line) in elderly patients. *Turk J Anaesthesiol Reanim*. 2015;43(3):149–153. doi:10.5152/TJAR.2015.35761
28. Furness G, Reilly MP, Kuchi S. An evaluation of ultrasound imaging for identification of lumbar intervertebral level. *Anaesthesia*. 2002;57(3):277–280. doi:10.1046/j.1365-2044.2002.2403_4.x
29. Kim HW, Ko YJ, Rhee WI, et al. Interexaminer reliability and accuracy of posterior superior iliac spine and iliac crest palpation for spinal level estimations. *J Manipul Physiol Ther*. 2007;30(5):386–389. doi:10.1016/j.jmpt.2007.04.005
30. Broadbent CR, Maxwell WB, Ferrie R, Wilson DJ, Gawne-Cain M, Russell R. Ability of anaesthetists to identify a marked lumbar interspace. *Anaesthesia*. 2000;55(11):1122–1126. doi:10.1046/j.1365-2044.2000.01547-4.x

31. Bartali B, Benvenuti E, Corsi AM, et al. Changes in anthropometric measures in men and women across the life-span: findings from the inchianti study. *Soz Präventivmed.* 2002;47(5):336–348. doi:10.1007/pl00012644
32. Gallagher D, Visser M, Sepúlveda D, Pierson RN, Harris T, Heymsfield SB. How useful is body mass index for comparison of body fatness across age, sex, and ethnic groups? *Am J Epidemiol.* 1996;143(3):228–239. doi:10.1093/oxfordjournals.aje.a008733
33. Tanaka K, Irikoma S, Kokubo S. Identification of the lumbar interspinous spaces by palpation and verified by X-rays. *Braz J Anesthesiol.* 2013;63(3):245–248. doi:10.1016/S0034-7094(13)70224-1
34. Sahin T, Balaban O, Sahin L, Solak M, Toker K. A randomized controlled trial of preinsertion ultrasound guidance for spinal anaesthesia in pregnancy: outcomes among obese and lean parturients: ultrasound for spinal anesthesia in pregnancy. *J Anesth.* 2014;28(3):413–419. doi:10.1007/s00540-013-1726-1
35. Kim J-T, Jung C-W, Lee J-R, Min S-W, Bahk J-H. Influence of lumbar flexion on the position of the intercrestal line. *Reg Anesth Pain Med.* 2003;28(6):509–511. doi:10.1016/j.rapm.2003.08.027
36. Lin N, Li Y, Bebawy JF, Dong J, Hua L. Abdominal circumference but not the degree of lumbar flexion affects the accuracy of lumbar interspace identification by tuffier's line palpation method: an observational study. *BMC Anesth.* 2015;15. doi:10.1186/1471-2253-15-9
37. Shiraishi N, Matsumura G. Establishing intercrestal line by posture:--a radiographic evaluation. *Okajimas Folia Anat Jpn.* 2006;82(4):139–146. doi:10.2535/ofaj.82.139

Funding: The authors received no financial support for the research, authorship, and/or publication of this article.

Declaration of Conflicting Interests: The authors report no conflicts of interest in this work.

Disclosures: Olumide Danisa reports grants/contracts from NuVasive and the Musculoskeletal Transplant Foundation (MTF); consulting fees from Stryker Spine and Spine Art; support for attending meetings/travel from the American Board of Orthopedic Surgery and the MTF; serving on committees for North American Spine Society, Orthopedic Research Society, and American Academy of Orthopedic Surgeons; and serving as an associate editor for SpineLine and NASSJ. Wayne Cheng reports grants or contracts from DePuy; consulting fees from Medtronic and Orthofix; and payment/honoraria for lectures, presentations, speakers bureaus, manuscript writing, or educational events from Orthofix and Radius. The remaining authors have nothing to disclose.

Data Availability Statement: The datasets used and/or analyzed during the current study are included in this published article and are available from the corresponding author on reasonable request.

Corresponding Author: Wayne Cheng, Division of Orthopaedic Surgery, Jerry L. Pettis Veterans Affairs Medical Center, 25805 Barton Rd Suite A106, Loma Linda, CA, USA; md4spine@yahoo.com

Published 26 September 2024

This manuscript is generously published free of charge by ISASS, the International Society for the Advancement of Spine Surgery. Copyright © 2024 ISASS. To see more or order reprints or permissions, see <http://ijssurgery.com>.