

INTERNATIONAL
JOURNAL
of
SPINE
SURGERY

Personalized Approaches to Spine Surgery

Arati Patel, Abraham Dada, Satvir Saggi, Hunter Yamada, Vardhaan S. Ambati, Elianna Goldstein, Edward C. Hsiao and Praveen V. Mummaneni

Int J Spine Surg 2024, 18 (6) 676-693

doi: <https://doi.org/10.14444/8644>

<https://www.ijssurgery.com/content/18/6/676>

This information is current as of January 2, 2025.

Email Alerts Receive free email-alerts when new articles cite this article. Sign up at:
<http://ijssurgery.com/alerts>

Personalized Approaches to Spine Surgery

ARATI PATEL, MD¹; ABRAHAM DADA, BA¹; SATVIR SAGGI, BS¹; HUNTER YAMADA, BS¹;
VARDHAAN S. AMBATI, MS¹; ELIANNA GOLDSTEIN, MD, MS²; EDWARD C. HSIAO, MD, PhD³; AND
PRAVEEN V. MUMMANENI, MD, MBA¹

¹Department of Neurological Surgery, University of California San Francisco, San Francisco, CA, USA; ²Department of Radiology and Biomedical Imaging, Neuroradiology Division, University of California San Francisco, San Francisco, CA, USA; ³Division of Endocrinology and Metabolism, The UCSF Metabolic Bone Clinic, University of California San Francisco, San Francisco, CA, USA

ABSTRACT

Patient-centric decision-making has imbued all aspects of health care, including spine surgery. This review describes how spine surgeons can use evolving technologies and knowledge of disease and pain states to tailor their surgical approach to the individual patient. This includes preoperative screening for and optimization of low bone mineral density, intraoperative selection of implant material and customization of interbody cages and screws, and postoperative personalization of pain regimens and rehabilitation courses. By working in a multidisciplinary fashion, spine surgeons can avail themselves of these advances to provide individualized care.

Special Issue (Invited)

Keywords: personalized medicine, spine surgery, biologics, bone mineral density, robotics, surgical planning, spine implants, outcomes, pain, artificial intelligence

INTRODUCTION

While personalized medicine has its roots in preventative care, favoring a proactive rather than a reactive approach to disease, its principles have now permeated all aspects of health care. In an era of performance-based reimbursements, there is growing emphasis on providing patient-centric decision-making during all aspects of their care. This includes all facets of spine care, from preoperative optimization to customization of intraoperative implants and postoperative pain management. While it has long been understood that a “1 size fits all” approach is inadequate for instrumentation selection, we now know there are other patient customizations of intraoperative implants and postoperative pain management. This article aims to provide an overview of evolving technologies and management algorithms and their implementation in a personalized approach to spine surgery.

PREOPERATIVE

Bone Mineral Density Assessment

The number of spine surgeries performed annually in the United States has increased alongside the aging population; however, the incidence of osteoporosis has also risen. Spine surgeons can work with endocrinologists to better understand how to

mitigate the effects of osteoporosis preoperatively, thereby achieving better fusion and avoiding hardware failure in this population.

Low bone mineral density (BMD) is strongly associated with postoperative complications^{1,2} such as pseudoarthrosis,³ cage subsidence,^{4,5} screw lucency,⁶ and proximal junction failure.^{7,8} Identifying potentially osteoporotic patients and implementing a personalized BMD optimization regimen in the preoperative setting improves the odds of successful fusion and favorable postoperative outcomes (Figure 1).

Dual-energy x-ray absorptiometry (DEXA) is the gold standard for assessing BMD (Figure 1A).^{9–12} The DEXA scan measures areal BMD (aBMD) through the degree of x-ray attenuation in patients exposed to low-level x-ray radiation.^{11,13} The aBMD is then normalized to the predicated peak bone mass, using a *T*-scored using the National Health and Nutrition Examination Survey III.¹⁴ A *T*-score of -2.5 or lower indicates osteoporosis and an elevated fracture risk. DEXA measurements are most commonly done in the spine and hip, which are most commonly used to define osteoporosis and treatment thresholds for preventing osteoporotic fractures.^{15,16} It is not recommended to measure the spine alone, as osteophytes can confound *T*-scores.¹⁷ With a grade B rating, the U.S. Preventive Services Task Force recommends routine DEXA

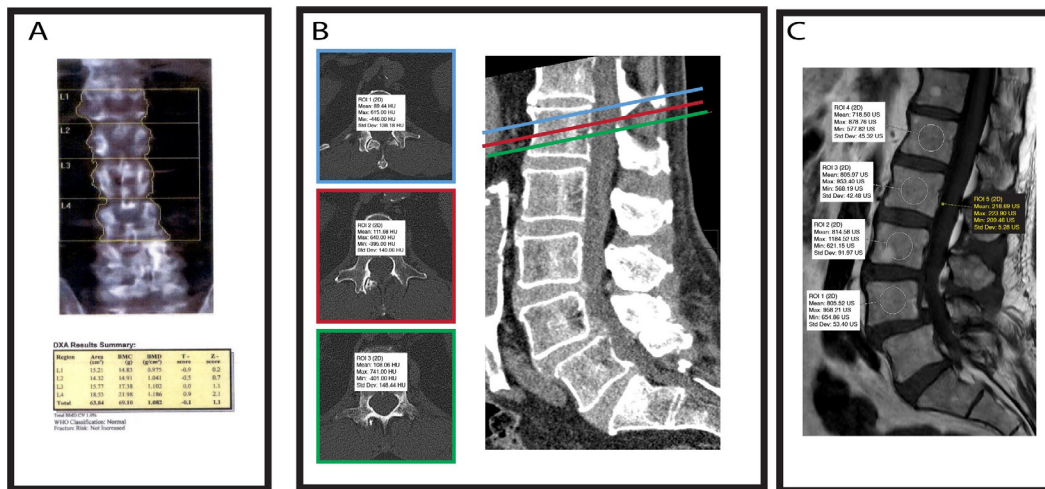


Figure 1. An 80-year-old man undergoing preoperative spinal imaging. (A) Lumbar dual-energy x-ray absorptiometry scan. (B) Hounsfield unit (HU) bone mineral density at a given level is calculated as the average HU of the superior endplate, middle of the vertebral body, and the inferior endplate. (C) Vertebral bone quality is calculated by dividing the median signal intensity of the medullary portions of L1–L4 vertebral bodies by the average signal intensity of the cerebrospinal fluid at L3.

screening of women aged 65 years or older and postmenopausal women younger than 65 years who are at increased risk of fracture.⁹

There are some limitations to DEXA. Spinal osteophytes associated with spondylosis have been shown to overestimate DEXA-measured BMD.¹⁷ This may partially explain the elevated rates (over 50%) of osteoporotic compression fractures in patients with “normal” spine DEXA scores.^{18,19} The DEXA scan has been shown to have limited accuracy in patients with obesity²⁰ and prior instrumentation.^{10,21} Many spine surgery experts, including the AOSpine Knowledge Forum Deformity working group, advise DEXA screening of the femur or distal radius in all patients being considered for elective screening.^{12,22}

In the context of spine surgeries, we consider that DEXA scores at the hip are typically the most reliable. DEXA scores in the spine can be confounded by osteophytes (leading to an artificially elevated aBMD) or by compression fractures.¹⁷ Patients without these complications can still have spinal DEXA measurements that are of value for clinical decision-making. Although forearm DEXA can be used to assess the risk of distal forearm fracture,²³ this has been controversial. In addition, the utility of the forearm DEXA in predicting overall skeletal health is unclear because of known variability based on the specific anatomic landmark used as well as whether the dominant vs nondominant arm is measured. Therefore, limitations of the use of forearm DEXAs have been recommended by the International Society for Clinical Densitometry.²⁴

Ancillary software, like the trabecular score (TBS), can be applied alongside a DEXA scan to obtain complementary of aBMD within the spine. The TBS is a textural index that evaluates pixel gray-level variations in the lumbar spine DEXA permitting more accurate clinical evaluations of skeletal microarchitecture and bone quality.^{25,26} TBS is independent of degenerative bone abnormalities such as osteophytes and can reduce underestimating fracture risk in patients with nonpathological DEXA *T*-scores.^{27,28} However, older versions of TBS software showed inaccuracies in patients with high BMI, or if significant structural changes were present in the assessed vertebrae. TBS indicative of degraded bone quality is generally less than 1.23.^{28,29}

Another example of aBMD assessment software includes the fracture risk assessment tool (FRAX), a computer-based algorithm that uses clinical features (eg, age, sex, race, and evidence of secondary osteoporosis) to estimate the 10-year probability of major osteoporotic and hip fractures.³⁰ Unlike TBS, treatment decisions for osteoporosis using FRAX alone in patients who are treatment naïve are well established.^{31,32} FRAX-based indications for treatment are at least 3% for hip or at least 20% for hip or major osteoporotic fractures (which includes the spine), respectively.^{31,33} TBS is most useful for individuals who lie close to a FRAX or BMD *T*-score intervention threshold.²⁸ We recommend primary BMD screening with DEXA at this time, along with the use of TBS and FRAX as adjuncts.

Computed tomography (CT) and magnetic resonance imaging (MRI) are routinely used to assess surgical spine pathology preoperatively. Currently, neither CT nor MRI is clinically validated to evaluate BMD. However, newer methods such as a dedicated bone CT scan or quantitative CT scanning to determine BMD are being developed.³⁴ These advanced methods may be available in research settings or in some clinical centers, and they can be very helpful for direct assessment of volumetric BMDs, especially for patients in whom the DEXA may have limited interpretability. We consider 3 sites of DEXA imaging (hip, spine, and distal forearm) with TBS as the gold standard for BMD assessment.

Widely available across standard medical imaging viewing software, the Hounsfield unit (HU) is a helpful tool for assessing BMD from CT scans. The HU is a unitless measure of density derived from a normalization of the CT image such that -1000 HU corresponds to air, while HU corresponds to pure distilled water. Schreiber et al describe estimating the BMD of a given vertebra by taking the average of HU measured at 3 distinct locations: immediately inferior to the superior end plate, middle of the vertebral body, and superior to the inferior end plate (Figure 1B).³⁵ Investigators comparing HU measurements in the spine to DEXA-derived *T*-scores have established thresholds indicative of poor BMD to range from 73 to 202 HU.

Irrespective of HU findings, a DEXA scan must still be used to assess BMD as it is a clinically validated tool and critical for supporting the treatment decision-making process. Concordance between DEXA *T*-scores and HU ranges anywhere from 40% to 54%.³⁶ The use of DEXA in assessing BMD in patients with pre-existing spinal hardware has proven challenging due to interference from the metallic artifact.²¹ Compelling work suggests that HU measurements may best suit this use case. Wanderman et al collected pre- and postoperative HU measurements from lumbar CT scans of 50 patients who underwent L2 and distal instrumented lumbar fusions, finding that the postoperative HU at the upper instrumented vertebra was strongly correlated with and not significantly different from the preoperative HU.³⁷

It is crucial to bear in mind that the CT acquisition technique influences HU measurements. CT kilovoltage settings have been shown to alter the HU unit thresholds for predicting osteoporotic *T*-scores.³⁸ Furthermore, intravenous contrast has been shown to slightly overestimate HU. A study

comparing HU at L1 between CT with and without contrast found differences of up to 8%.³⁹ These confounders must be accounted for when using HU to determine BMD.

Recent work has established MRI-based equivalents for measuring bone density well.⁴⁰ Ehresmen et al described the vertebral bone quality (VBQ) score collected from T1-weighted MRI. VBQ is calculated by dividing the median signal intensity of the medullary portions of L1 to L4 vertebral bodies by the average signal intensity of the cerebrospinal fluid at L3 (Figure 1C). VBQ scores had a predictive accuracy of 81% in detecting osteopenic/osteoporotic bone⁴⁰ and have been shown to correlate moderately with DEXA *T*-scores.^{41,42} VBQ thresholds indicative of poor BMD range from 2.18 to 3.06.^{42,43} Irrespective of VBQ findings, a DEXA scan must still be used to assess BMD as it is a clinically validated tool.

VBQ analysis is not without its shortcomings. Hyperlipemia has been shown to overestimate the presence of osteoporosis compared with DEXA.⁴⁴ Although future research is needed to validate this new methodology, it remains a viable screening tool for osteoporosis.

Pharmacological BMD Optimization for Instrumented Spinal Surgery

It is well understood that low BMD is tied to poor fusion outcomes.⁴⁵ Adequate preoperative BMD optimization of patients meeting diagnostic criteria for osteoporosis is paramount to increasing the odds of adequate fusion and maximizing postoperative outcomes. Our approach to preoperative BMD treatment employs apt, interdisciplinary collaboration with endocrinologists, who play a pivotal role in optimizing osteoporotic patients before and after spinal surgery.⁴⁶⁻⁵⁰ First, we employ nonpharmacological methods, such as physical therapy and weight bearing as tolerated. All secondary causes of osteoporosis, such as hypogonadism, hypo- or hyperthyroidism, renal calcium leak, hypophosphatasia, vitamin D deficiency, and hyperparathyroidism, must be explored and treated. We then consider pharmacological treatment. The standard pharmacological armamentarium comprises vitamin D3, bisphosphonates, denosumab, and anabolic medications such as PTH analogs and romosozumab (Figure 2).

Vitamin D2 (plant derived) and D3 (animal derived) are routinely used in the therapeutic

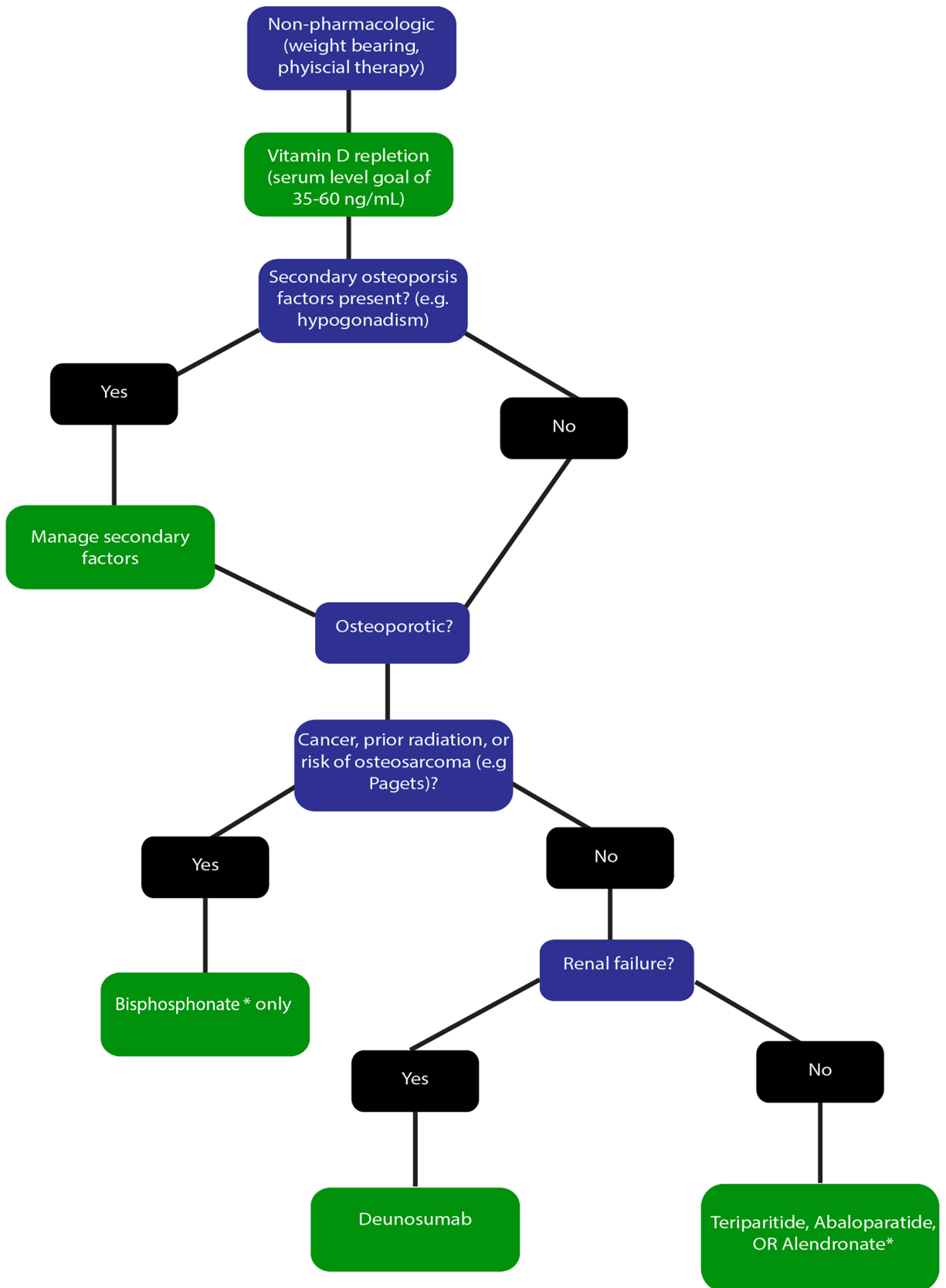


Figure 2. Algorithm for optimization of preoperative bone mineral density. *At this time, starting bisphosphonates as a single agent to treat osteoporosis specifically for surgery optimization is not generally warranted. However, surgery is not contraindicated and does not need to be delayed in patients who are currently receiving bisphosphonates

management for osteoporosis. Vitamin D is essential for calcium absorption and bone mineralization, and it is generally well tolerated in the doses used to improve BMD.⁵¹ In a retrospective study evaluating the effect of perioperative 1,25 hydroxy vitamin D3 supplementation on fusion rates in patients with osteoporosis, Xu et al found that supplementation significantly improved 6-month fusion rates (76.19% vs 43.48%, $P = 0.03$).⁵² In our practice, we aim for a serum level goal of 35 to 60 ng/mL.^{53,54} Notably, correlations between calcium and vitamin D supplementation and coronary artery calcification remain controversial.⁵⁵ Therefore, we recommend supplementation for patients with low dietary intake or documented deficiencies, but not oversupplementation.

Bisphosphonates are the first-line treatment for osteoporosis. This drug class improves BMD through osteoclast inhibition and subsequent reduction of bone resorption. Common side effects include reflux and esophagitis.⁵⁶ Rarely, patients may experience osteonecrosis of the jaw and atypical fracture, although the benefits of fracture reduction significantly outweigh the risks of these complications.⁵⁷ Evidence supporting bisphosphonate therapy as a single-agent regimen in the treatment of osteopenic patients undergoing spinal surgery is largely inconclusive.⁵⁸ While Nagahama et al found higher fusion rates in patients given alendronate after posterior lumbar interbody fusion, Kim et al failed to find any differences when using the drug for single-level posterior fusions.^{59,60} Similarly, zoledronic acid, an intravenous bisphosphonate, has shown ambiguous results.⁶¹ At this time, starting bisphosphonates as a single agent to treat osteoporosis specifically for preoperative optimization is not warranted.⁵⁸ However, surgery is not contraindicated and does not need to be delayed in patients who are currently receiving bisphosphonates.⁵⁸ Combination therapy of teriparatide with a bisphosphonate does not appear to show additional benefits over teriparatide alone.⁵⁸

Anabolics such as teriparatide, a recombinant human parathyroid hormone (PTH) analog, are excellent medications for treating osteoporosis. It increases osteoblast activity and promotes bone growth.⁶² Although the black box warning for inducing osteosarcoma was removed in 2020,⁶³ there is still a warning about the risk of bone malignancy in patients who are at higher risk of osteosarcoma. We generally avoid anabolics in patients with active

cancer, patients with prior radiation, or patients at risk of osteosarcoma (eg, Paget's), as well as patients with growing skeletons.^{64,65} In a prospective, nonrandomized study, Ohtori et al found that teriparatide treatment not only resulted in higher fusion rates compared with bisphosphonates (82% vs 68%) but also conferred faster time to fusion (8 months vs 10 months).⁶⁶ Ohtori et al also found a reduced incidence of pedicle screw loosening in patients treated with teriparatide compared with those treated with bisphosphonate (7% vs 13%).⁶⁶ Cho et al compared cyclic combination treatment of teriparatide and bisphosphonates to bisphosphonate monotherapy and found that the combination group achieved fusion faster.⁶⁷ Notably, no standard duration of teriparatide therapy has been defined for spinal surgeries. In our practice, if a patient qualifies for osteoporosis treatment with teriparatide or another PTH analog, then a full 2-year course for osteoporosis (starting 3 months prior to surgery, if possible) is desirable. In addition, patients who are currently only on a bisphosphonate for management of their osteoporosis can be considered for transition to teriparatide in the setting of preoperative optimization. Important side effects of PTH analogs to monitor for include hypercalcemia and injection site infections.

Denosumab is a second-line antiresorptive medication for the treatment of osteoporosis. Denosumab is a monoclonal antibody against the receptor activator of nuclear factor- κ B ligand, and its interactions with receptor activator of nuclear factor- κ B ligand lead to decreased osteoclast activity.⁶⁸ Because of the high risk of spinal compression fractures and rebound osteoporosis in patients who discontinue denosumab, its use has become much more limited for managing osteoporosis.⁶⁹ In our practice, we employ denosumab for patients who cannot tolerate bisphosphonates due to renal failure.⁷⁰ Patients receiving denosumab should be counseled that denosumab therapy may need to be lifelong, with unclear implications and long-term risks, because denosumab transition-off protocols remain suboptimal.⁶⁹ In addition, sequential therapy (ie, from denosumab onto teriparatide) is associated with increased bone loss⁷¹ and should not be done. Notably, the DATA-SWITCH study also showed that combined therapy of denosumab with teriparatide has shown strong benefit for osteoporosis management.⁷¹ Ide et al followed 16 patients treated with denosumab and teriparatide, enabling higher fusion rates at 6 months

compared with those treated with teriparatide alone.⁷² Therefore, for patients who are currently on denosumab, it is important not to discontinue the denosumab prior to surgery. Addition of teriparatide for concomitant treatment may be a consideration, but the teriparatide should be discontinued first before denosumab once the treatment course is completed. These patients can be complicated to manage, so a multidisciplinary approach with an experienced bone/osteoporosis team is warranted.

Other popular second-line treatments include selective estrogen receptor modulators and romosozumab; however, there is limited clinical evidence investigating the use of these agents in the context of spinal surgery outcomes, and this is beyond the scope of this review. Ultimately, our practice is in line with the Congress of Neurological Surgeons' recommendations, which endorse the use of anabolics, such as teriparatide, for preoperative osteoporosis treatment with a grade B rating.⁵⁸ Future randomized controlled trials are needed to further substantiate this position.

Utility of EOS and Robotics in Perioperative Surgical Planning

In addition to improvements in preoperative BMD detection and optimization, several new technologies have been introduced to facilitate the interpretation of patient-specific spinopelvic parameters and surgical planning.

Historically, spinopelvic parameters have been assessed on standing sagittal and coronal whole-spinal radiographs.⁷³ While this method is effective in assessing spinal malalignment, it is hindered by image distortion at the edge of the radiograph and poor interobserver reliability.^{73,74} EOS, a proprietary low-dose biplanar imaging system, offers a novel method for assessing spinopelvic parameters in the preoperative setting (Figure 3). In general, EOS has several advantages over conventional spinal radiographs. Conventional x-ray radiography requires multiple exposures followed by stitching of images to generate a full-body image (Figure 4C and D; Figure 5D and E). However, EOS imaging avoids the need for multiple exposures, thereby reducing the examination time, decreasing the overall radiation exposure per examination, and eliminating the distortion and stitching artifacts seen in conventional radiography.⁷⁵ Not only does the EOS produce distortion-free, high-quality images, but it also generates 3D renderings that

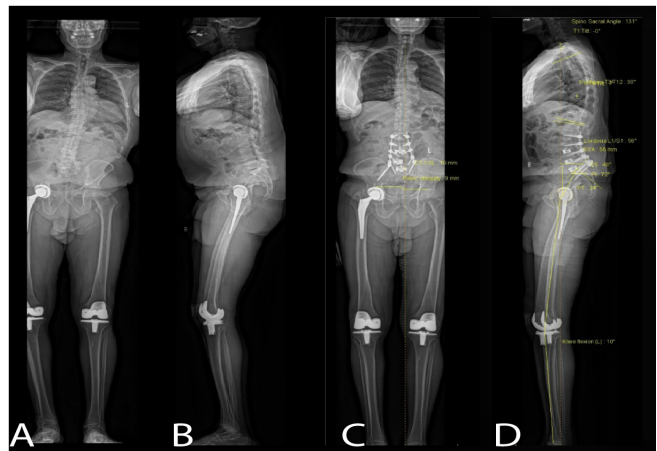


Figure 3. A 78-year-old man with a history of prior lumbar laminectomy underwent a 2-stage lumbosacral fusion: L3–L5 anterior lumbar interbody fusion and L2–pelvic minimally invasive fixation for severe back pain, right leg pain, and chronic right foot weakness. (A) Preoperative anteroposterior and (B) lateral full spinal imaging generated from an EOS scan, revealing severe degenerative changes, spinal stenosis worst at L2–L3 and L3–L4, and scoliosis with a significant mismatch between lumbar lordosis and pelvic incidence. (C) Postoperative coronal and (D) sagittal full spinal imaging generated from EOS showing instrumentation.

cannot be produced from conventional radiography.⁷⁶ Recent work from Shakeri et al shows that spinopelvic parameters measured from EOS films are reliable and comparable to those generated by traditional radiographs.⁷⁶

Recent developments in robot-assisted spinal surgery have allowed for safer, faster, and more personalized care.⁷⁷ The Mazor X and Globus Excelsius systems are examples of this technology. They incorporate 3-dimensional (3D) analytical software as an adjunct to preoperative planning. With this software, surgeons can simultaneously inspect implant size and trajectory in all 3 planes.⁷⁸ In an updated iteration of this software, the Mazor X and ExcelsiusGPS now provide real-time 3D visualization in the operative setting as surgeons use instruments and/or place screws along preoperatively planned trajectories.⁷⁷

After surgeons surmount the learning curve, robotic planning has been shown to augment operative efficiency and reduce operative times.^{79–81}

INTRAOPERATIVE SETTING

Technological advances have also changed the landscape of the operating room with regard to the customization of spinal implants. While neuronavigation systems allow for intraoperative planning of screw size and trajectories in addition to implant size based on an intraoperative CT, 3D printing, and the ability to choose

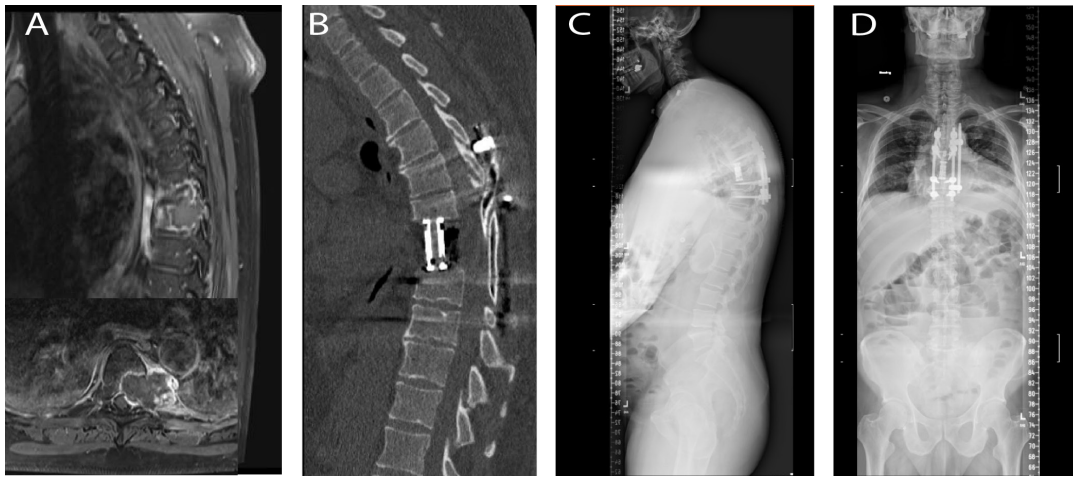


Figure 4. Fifty-two-year old man who underwent a T7 corpectomy with en bloc resection of a grade 2 chondrosarcoma and T5–T9 posterior fusion. This is an example of a case in which a custom implant would have been advantageous given the irregular margins of the tumor resection cavity. (A) Preoperative T1-post gadolinium magnetic resonance imaging revealed a 1.4 cm bony destructive mass within the T7 vertebral body and left pedicle with expansile component to the left paravertebral space and also left epidural component abutting the thoracic cord without cord compression (inset). (B) Postoperative computed tomography scan demonstrating an expandable titanium cage flush to the endplates of T6 and T8. (C) and (D) Postoperative stitched standing scoliosis films demonstrating anterior and posterior instrumentation.

implant materials based on patient-related factors take this personalization 1 step further.

Implant Choice

Information derived from preoperative imaging can be used to fashion digitally modeled 3D implants. Printed implants can cater to the patient’s anatomy and biomechanical requirements; their specificity allows for minimal removal of surrounding structures and preservation of normal anatomy during implantation.^{82,83} Moreover, custom implants allow for a more even distribution of stress and shearing forces and optimize osteointegration. Additionally, custom implants

that optimize fit with superior and inferior endplates mitigate the need for adding bone grafts, reducing the overall surgical time that would have been spent harvesting said graft. D’Urso et al were the first to describe 3D printing for preoperative planning in 1999; the first 3D printed implant was used in 2014. 3D modeling is particularly helpful in spine oncology; tumors irregularly erode and invade adjacent structures, and modeling the tumor configuration can help with preoperative planning and lead to an overall decrease in operative time and blood loss associated with tumor resection (Figure 4).⁸⁴ Moreover, as a result of the invasive nature of tumors, tumor resection cavities are often irregularly

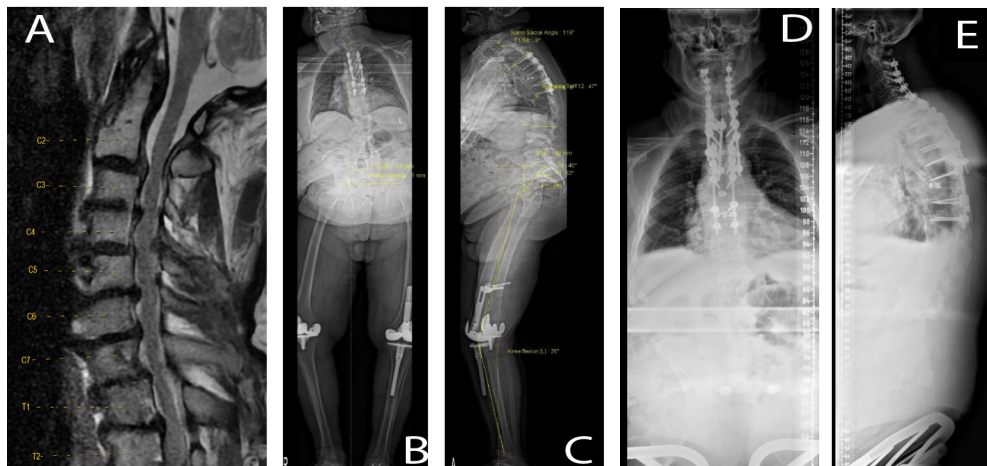


Figure 5. Sixty-eight-year-old man who underwent posterior C2–T6 fusions extension into prior fusion construct and C2–T2 laminectomy for progressive cervical myelopathy status post prior T7 corpectomy and T4–T9 fusion following T6–T7 pathologic fracture secondary to osteomyelitis. (A) Preoperative magnetic resonance imaging demonstrating severe stenosis from C2 to T2. (B) Preoperative anteroposterior (AP) and (C) lateral EOS scans demonstrating prior posterior hardware. (D) Postoperative AP and (E) lateral stitched scoliosis films highlighting a titanium rod construct spanning C2–T9.

shaped and an ill fit for standard vertebral prosthetics, necessitating custom implants for restoration of load-bearing segments.^{85,86} The use of custom implants has been associated with better long-term stability and decreased periods of activity restriction after spine tumor surgery. Custom implants offer a new solution in the operative management of axis tumors since current cervical implants are optimized for the subaxial spine and have difficulty recapitulating the biomechanics of the axis.^{87,88}

Beyond surgical oncology, 3D-printed implants can also be useful for congenital deformities. In the case of adolescent idiopathic scoliosis, where curvature makes it difficult to visualize the optimal screw trajectory, a drill guide can be 3D printed based on preoperative imaging to lay down on the entry point and guide screw placement. In a retrospective study of 126 adolescent idiopathic scoliosis patients, using a 3D-printed biomodel was associated with decreased operative time, blood loss, and transfusion volume without an increase in postoperative complications or length of stay.⁸⁹ Another opportunity would be in the case of congenitally abnormally sized pedicles and vertebral bodies, such as in achondroplasia. With 3D printing, we are no longer forced to repurpose our existing implants to accommodate these patients, often resulting in a less-than-ideal construct; instead, we can offer a customized and well-planned construct.

Materials

The properties of constructs are an essential consideration when deciding which material to use, and another important realm is where an individualized approach can be taken (Table 1). Most commonly, stainless steel (SS), titanium (Ti), cobalt chromium (Co-Cr), and polyethylene terephthalate (PEEK) are used in

spinal constructs (Figure 5).⁹⁰ Each material has its own set of advantages and indications for use. The appropriateness of each material is typically assessed based on its Young's modulus, tensile strength, fatigue strength, and radiopacity.⁹⁰ In cases of adult spinal deformity correction, where it is important to maintain the initial correction made, rod material is especially important. While Co-Cr and ultrahigh strength SS rods generate the greatest corrective forces compared with SS and Ti, they come at the cost of greater plastic deformation.⁹¹ Co-Cr multiple-rod constructs also have a higher occurrence of proximal junctional kyphosis when compared with Ti alloy 2-rod constructs.⁹² While there are variable reports on breakage between Co-Cr and Ti rods, there is no difference in other outcomes, including Cobb angle, sagittal vertical axis, pelvic tilt angle, and pseudoarthrosis.⁹³

Radiopacity becomes a decision-making factor for patients requiring frequent screening or oncological treatment. For patients with primary and metastatic spinal tumors, carbon-fiber-reinforced (CFR) PEEK constructs can be useful for reducing imaging artifacts.⁹⁴ CFR PEEK hardware may also reduce radiotherapy perturbations while having an 89% fusion rate, which is comparable to Ti implants.⁹⁵ In a comparative study with more than 7 years of follow-up for multilevel cervical spondylotic myelopathy, PEEK cages were found to have lower subsidence rates and improved maintenance of intervertebral height and cervical lordosis when compared with Ti.⁹⁶ A survey conducted by the North American Spine Society section of spinal oncology found varied opinions on CFR PEEK. Respondents were largely concerned with the high cost and low availability, which was reflected in their low utilization for anterior and posterior constructs following tumor resection.⁹⁷

Table 1. Summary of implant materials and their applications and characteristics.

Material	Young's Modulus	Applications	Pros	Cons
Ti6Al4V	110	● Rods	● Lightweight	● Relatively expensive
Ti	50.2	● Cages ● Plates ● Screws	● Flexible ● Alloys available	● Imaging artifacts
Co-Cr	53.15	● Rods	● High corrective force for scoliosis	● Risk of plastic deformation ● Risk of PJK ● High imaging artifacts ● High imaging artifacts ● Corrosion
Stainless steel	51.07	● Rods	● Inexpensive	● Low Young's modulus
CFR PEEK	17.94	● Rods ● Cages	● Reduced imaging artifacts	
Cancellous bone	3.87			

Abbreviations: CFR, carbon fiber reinforced; Co-Cr, cobalt chromium; PEEK, polyethylene terephthalate; PJK, proximal junctional kyphosis; Ti, titanium.

Material considerations for osteoporotic patients warrant special attention due to the increased risk of hardware failure. Screw loosening in osteoporotic patients is not entirely understood, but it appears that cranio-caudal toggling can significantly reduce screw pullout strength in osteoporotic vertebrae. It is thought to occur through tissue failure around the screw.⁹⁸ Some approaches to improve pullout strength in osteoporotic vertebrae include using fenestrated pedicle screws. Compared with conventional pedicle screws, fenestrated pedicle screws allow for the injection of polymethylmethacrylate, calcium phosphate, or hydroxyapatite cement into cannulation and out of the fenestrations, thereby reducing the risk of screw loosening and improving screw fixation and overall fusion rates. Additionally, other less commonly used methods of screw fixation in osteoporotic vertebrae include using allograft bone particles, calcium phosphate cement, or demineralized bone matrix. These can be used for pedicle augmentation and are found to improve the screw-bone interface and increase screw pullout force and fatigue load cycle.

Other methods that increase maximum pullout force in osteoporotic bone are expandable pedicle screws and cortical trajectory screws. Each of these individually can increase the maximum pullout force by approximately 130% compared with unreinforced screws.^{89,99}

Technique

In addition to material choice, there are numerous techniques for contouring rods to patients' unique anatomy. Manual bending can introduce stress and strain into rods, which has implications for breakage, plastic deformation, and maintenance of correction. For adolescent patients with idiopathic scoliosis, notch-free prebent rods were found to have higher thoracic kyphosis postoperatively compared with those with manually bent rods. This was achieved because the notch-free prebent rods maintained their curvature better than the manually bent rods.¹⁰⁰ Several groups have recapitulated these findings in adolescent idiopathic scoliosis.¹⁰¹ Beyond demonstrated efficacy in adolescent pathology, patient-specific rods have demonstrated significant improvement in patient-reported outcomes and spinopelvic parameters in adult deformity as well.¹⁰²⁻¹⁰⁴

Proper rod choice and alignment are also important for avoidance of screw pullout. Forcing a rod to fit into a tulip head when there is a gap discrepancy significantly reduces the pullout strength of the screws.¹⁰⁵ The stress in a construct can also be determined by the method of shaping rods. Finite element studies have shown that using a French bender induces more stress

than an in-situ bender. There are currently efforts to use machinery to bend rods to patient-specific anatomy. They are designed to reduce forces on the screw-bone interface compared with freehand bending.¹⁰⁶

CT-Guided Navigation

Imaging and navigation enhance the surgeon's ability to understand, verify, and plan surgeries based on their patient's anatomy. Intraoperative CT-guided navigation has proven to be an essential tool in the spinal surgeon's armamentarium for adult deformity and degenerative pathologies. Placing pedicle screws using the freehand technique is challenging due to obscured anatomical landmarks, a common issue in deformity correction surgeries. CT-guided navigation systems enhance placement accuracy by providing real-time, 3-dimensional imaging, which allows for precise localization of anatomical structures. Studies have shown that navigation use can improve placement accuracy¹⁰⁷⁻¹⁰⁹ and reduce pedicle screw placement time and breach rates.¹¹⁰

Whether in the form of C-arm fluoroscopy or CT, intraoperative x-rays are vital tools during spine surgery. When comparing cone-beam CT and fluoroscopy, cone-beam CT has a reduced mean screw placement time, operative time, and length of stay. However, it also yields a higher total radiation dose. This is an important consideration when planning imaging for adolescent idiopathic scoliosis: patients younger than 18 being treated for a spinal deformity may have an increased estimated risk of developing cancer due to the radiation they are exposed to during surgical intervention.

POSTOPERATIVE SETTING

Ultimately, patient-reported outcomes and patient satisfaction after surgery are contingent upon a host of factors independent of the adequacy of their surgical construct; as such, surgeons' planning does not stop as soon as the patient leaves the operating room. With an improved knowledge of the importance of postoperative nutrition and rehabilitation, spine surgeons can work with nutritionists and physical therapists to optimize these 2 aspects of postoperative recovery and improve the chances of maximizing functional outcomes.

Personalized Postoperative Pain Regimens

Pharmacogenomics and Inter-Individual Differences in Drug Clearance

For patients undergoing spine surgery, personalized pain regimens can serve as an important component

Table 2. Overview of pain-associated genes that can be used as screening targets in the context of spine surgery.

Gene	Function	Example Polymorphism(s) Associated With Pain
Catechol-O-methyltransferase	Metabolism of catecholamines (dopamine, epinephrine, and norepinephrine)	rs4680 GG (Ernst et al, 2024) ¹¹³ Val158Met (Rakvåg et al, 2008 ¹¹⁴ ; Diatchenko et al, 2006 ¹¹⁵)
Neuropeptide Y Guanosine triphosphate cyclohydrolase 1	Neuropeptide implicated in pain modulation Rate-limiting enzyme in the synthesis of tetrahydrobiopterin (BH4)	rs16147 TT (Ernst et al, 2024) ¹¹³ rs998259 (minor allele T) (Kim et al, 2010) ¹¹⁶
Opioid Receptor Mu 1	Encodes for the mu opioid receptor	Asn118Asp (Lötsch et al, 2004) ¹¹⁷

in reducing the duration of postoperative pain and decreasing opioid dependency. Approximately half of the patients indicate continued postoperative pain following back surgery, with nearly 40% of the patients at the 6-month postoperative period still reporting the use of pain medications.¹¹¹ These findings suggest the need for pain regimens that are tailored to a patient's specific characteristics. Over the past 2 decades, pharmacogenomics has increasingly offered new insights into creating patient-specific pain regimens using genetic screening for polymorphisms present in pain-associated genes. White and Kehlet discuss how differences at the individual level in pain sensitivity can lead to different responses to similar painful stimuli such that some individuals, through genetic differences, can be categorized as either low- or high-pain responders.¹¹² Categorizing patients into these groups in the preoperative period can dictate the quantity and type of pain medications in the postoperative period. Indeed, several genes have been identified over the years that can serve as possible screening targets, with many being investigated in the context of spine surgery (Table 2).

Catechol-O-methyltransferase (COMT) is an important enzyme involved in metabolizing various catecholamine neurotransmitters, such as dopamine, epinephrine, and norepinephrine. Polymorphisms in this gene have an important role in the context of modulating pain. Similar to the idea discussed by White and Kehlet, COMT is a screening target that can play a role in categorizing patients who are more or less susceptible to painful stimuli.¹¹² In a study by Diatchenko et al, 3 COMT haplotypes, with primary differences in the rate of COMT protein translation, were found to be associated with low-, average-, or high-pain sensitivity.¹¹⁵ Those who were homozygous for the low-pain sensitivity haplotype had the greatest tolerance for different forms of noxious stimuli, while those with the high-sensitivity haplotype had the least tolerance. In addition to pain sensitivity, polymorphisms in the COMT gene have been associated with variations in the quantity of opioid dosages required to treat pain. Rakvåg et al, in a study involving patients with cancer-related pain, performed genotyping of 11 single

nucleotide polymorphisms of the COMT gene to construct COMT haplotypes.¹¹⁴ Patients with the most frequent haplotype required less morphine compared with those patients who did not possess these haplotypes to treat cancer-related pain. The results of this study not only carry implications for patients with malignancies in general but can be a topic of further investigation in the pre- and postoperative context for patients with spinal malignancies.

Focused studies on pharmacogenomics in patients with spinal pathologies have been explored in the context of both the COMT gene and additional pain-related genes. In a recent study by Ernst et al in 2024, the genes COMT and Neuropeptide Y (NPY) were investigated to determine if polymorphisms in these genes are related to symptom severity and treatment outcomes in patients with lumbar spinal stenosis.¹¹⁴ Patients with a specific COMT genotype displayed greater severity of symptoms at baseline, while patients with a specific NPY genotype displayed not only greater baseline symptom severity but also better treatment outcomes. Although this study specifically focused on patients with lumbar spinal stenosis receiving nonoperative treatment modalities, the results can possibly be translated toward using variations in NPY and COMT in predicting postoperative symptom levels in patients with degenerative spinal conditions. Other foundational studies have specifically laid the groundwork for the role of assessing genetic polymorphisms in operative spine cohorts. Tegeder et al found that in patients who had undergone discectomy for radicular back pain, a specific haplotype in the gene Guanosine triphosphate cyclohydrolase 1 was associated with decreased pain levels after surgery.¹¹⁸ Similarly, a subsequent study focusing on patients undergoing instrumented fusion or disc arthroplasty in patients with lumbar degenerative disease demonstrated that a single nucleotide polymorphism in the Guanosine triphosphate cyclohydrolase 1 gene was significantly associated with improvement in the Oswestry Disability Index score and Numerical Rating Scale back pain scores following surgery.¹¹⁶

Through screening patients with this particular polymorphism in the preoperative setting, patients with lumbar degenerative disc disease or other degenerative pathologies of the spine can possibly have tailored pain dosages and regimens in association with their expected postoperative outcome.

The mu opioid receptor, encoded by the OPRM1 gene, is also implicated as an important preoperative screening target. The mu opioid receptor is the binding site for several opiates, including morphine, methadone, and fentanyl. Polymorphisms in the OPRM1 gene are associated with different analgesic effects and dosage requirements to treat pain. For example, the single nucleotide polymorphism A118G for the OPRM1 gene is associated with not only decreased analgesic effects of both morphine and morphine metabolites in the laboratory setting but also with postoperative pain scores, morphine use, and morphine-related side effects. In patients with spine pathologies, inter-individual differences in the OPRM1 regulatory site have been shown to have associations with postoperative pain.¹¹⁷ In a study by Chidambaran et al in 2016 of 133 adolescents undergoing spinal fusion for idiopathic scoliosis, differences in DNA methylation at methylation sites of the OPRM1 gene promoter were found to be associated with preoperative pain measures along with the development of acute and chronic postsurgical pain.¹¹⁹

Other important factors for optimal personalized pain regimens for patients undergoing spine surgery include individual differences in drug clearance. For example, polymorphisms in drug efflux pumps are associated with differences in the development of morphine-related side effects and, therefore, serve as additional screening targets for determining optimal dosage requirements in the postoperative setting.¹²⁰ Finally, outside of genetic screening, concomitant medications being taken alongside pain medications should be carefully reviewed for possible drug-drug interactions.¹²¹ Morphine, when used alongside other drugs that interfere with morphine metabolism, can result in either potentiated side effects or a reduced therapeutic effect.

AI Tools for Predicting Postoperative Pain

Artificial intelligence (AI) prediction tools, including machine-learning models, are important for assessing which patients are more likely to develop postoperative pain and opioid dependency following surgery based on preoperative clinical,

radiographic, and genetic variables. In a Quality Outcomes Database study by Park et al, machine-learning models were implemented to determine the likelihood a patient with cervical spondylotic myelopathy will achieve a clinically meaningful improvement in neck pain following surgery.¹²² Similarly, in a study performed using the Norwegian Registry for Spine Surgery, machine-learning models were trained on over 20,000 patients with surgery for lumbar disc herniation to determine treatment success with respect to a range of postoperative pain measures.¹²³ Through using machine-learning models and AI-powered calculators, patients with spinal pathologies who are at greater risk of not developing significant improvement in pain can be screened for in the preoperative setting for more aggressive follow-up in the postoperative setting for optimized pain control and additional therapeutic interventions.

Machine learning in the preoperative setting has also shown promise in determining patients who are at high risk of needing an extended duration of postoperative opioid medications after lumbar disc herniation surgery.¹²⁴ Patients who are predicted to have greater postoperative opioid needs following surgery can undergo greater surveillance to ensure that pain needs are being met adequately without the need for an extended duration. AI prediction tools are, therefore, valuable for screening patients with a greater need for postoperative pain control. Through future incorporation of a patient's specific genetic polymorphisms and preoperative radiographic features, AI models can potentially offer high prediction accuracy for patients who are at the highest risk of postoperative pain.

Personalized Physical and Nutritional Therapy in the Postoperative Period

Postoperative rehabilitation approaches optimized to a patient's particular characteristics have the opportunity to improve functional outcomes in patients following spine surgery. Several prior studies have demonstrated the importance of a personalized rehabilitation approach as opposed to standardized rehabilitation methods. Millisdotter et al performed a study comparing the performance of a neuromuscular customized training program with a traditional rehabilitation approach following lumbar disc herniation.¹²⁵ At 12 months surgery, patients who underwent the customized approach had improved disability levels compared with those patients who underwent

the traditional approach. A personalized physical rehabilitation approach should additionally be supplemented with approaches emphasizing biopsychosocial domains. Prior studies have demonstrated the importance of addressing these domains in patients undergoing spine surgery. For example, in a study of patients undergoing lumbar fusion, the postoperative recovery trajectory was found to be also determined by biopsychosocial factors such as depression, anxiety, and fatigue.¹²⁶ Similarly, for patients undergoing spinal cord stimulation surgery, a personalized biopsychosocial rehabilitation program can potentially offer improved postoperative outcomes in areas such as functional disability, quality of life, and return to work.¹²⁷ Adequately screening for these factors prior to surgery and ensuring that a patient's biopsychosocial needs are being met postoperatively are important, given the complex interplay of these factors with surgical outcomes.

Health-related technologies are additionally important during the postoperative period for monitoring patients who need earlier postoperative care. Such technologies offer the capability of customized follow-up times following spine surgery as opposed to standardized postoperative follow-ups. Prior to surgery, AI tools offer the potential capability to predict patients at greater risk of functional deterioration postoperatively. In a study by DeVries et al, machine learning was used to predict ambulatory activity in patients following spinal cord injury surgery with relatively good accuracy.¹²⁸ Those patients who were predicted to develop poor ambulatory status could, therefore, undergo more aggressive postoperative monitoring and physical therapy. Similar models can be developed to predict functional outcomes in patients with other pathologies of the spine.

In addition to preoperative tools, mobile digital platforms and wearable devices are possible avenues for close postoperative monitoring. Patient-reported outcome measures can be supplemented with objective data points from these digital health technologies to gain insight into the postoperative recovery trajectory. Ambulatory activity, tracked by measuring step counts using smartphones, serves as an objective metric to track changes in functional activity following spine surgery.¹²⁹ Furthermore, wearable devices, such as the tri-axis accelerometer, provide information into additional parameters beyond step count, such as cadence and posture. Patients with a slower than anticipated improvement in ambulatory activity

can have shortened follow-up times to analyze for new deficits or a need for a more aggressive physical rehabilitation. Mobile health applications allow not only activity monitoring but also monitoring of wound healing, pain management, and new deficits reported by a patient.¹³⁰ Other technologies include wearable cameras that allow for the measurement of functional limb usage, thereby allowing for monitoring of neurorehabilitation progress.¹³¹

Outside of customized physical therapy and patient-specific activity monitoring, optimizing a patient's nutritional status relative to their baseline frailty plays an important role in the postoperative surgical course. Screening for patients with poor nutritional status includes tools such as the Nutritional Risk Score and measurements of body mass index, sarcopenia, and other metabolic markers of frailty, such as albumin, which has been shown to be an independent predictor of postoperative complications after certain types of spine surgery.^{132,133} In a study by Rigney et al, patients who underwent surgery for metastatic spinal tumors and who received a nutrition consultation preoperatively were less likely to develop complications related to wound healing during the postoperative course.¹³⁴ Additionally, those patients who were determined to have a normal nutritional status at baseline were more likely to have improved survival following surgery. Similarly, in a study by Elsamadicy et al, patients with poor nutritional status and who underwent lumbar fusion for spondylolisthesis had greater rates of readmissions, length of stay, and adverse events such as pneumonia and skin/soft tissue infections.¹³⁵ Optimizing a patient's nutritional status based on their specific nutritional needs is therefore important prior to surgery with continued optimization postoperatively.¹³³

CONCLUSION

Evolving technologies and a deeper understanding of patient-specific factors have changed the landscape of spine surgery. By working in a multidisciplinary fashion with other health care providers, including but not limited to radiologists, endocrinologists, nutritionists, and physical therapists, spine surgeons can avail themselves of personalized, precision care and tailor each stage of the surgical pathway to the individual patient.

In this review, we described some ways to do so, from the initial clinic visit to the ultimate rehabilitation. BMD should first be assessed with DEXA scans, with complementary information gleaned from TBS

or FRAX scores. In collaboration with endocrinology, preoperative optimization of BMD is essential to mitigate the risks of osteoporosis-related complications, thereby improving surgical outcomes. Additionally, the intraoperative setting has seen significant advancements with the customization of implants. The use of 3D printing technology enables the creation of implants tailored to the patient's unique anatomical and biomechanical needs, enhancing the fit and functionality of the surgical constructs. Furthermore, the integration of cutting-edge technologies such as EOS imaging and robot-assisted surgery has improved the precision and efficiency of surgical interventions. These technologies facilitate accurate assessment of spinopelvic parameters and allow for meticulous preoperative planning and intraoperative execution. Equally important is the emphasis on postoperative care, where personalized pain management regimens, increasingly informed by pharmacogenomic and AI insights, as well as individualized physical and nutritional therapy plans, created with nutritionists and physical therapists, are crucial for optimizing recovery and functional outcomes.

By focusing on these critical factors, spine surgeons can significantly enhance patient care and outcomes through a personalized, patient-centric approach to spine surgery. This comprehensive, tailored care ensures that each patient receives optimal treatment throughout their surgical journey, ultimately leading to improved overall health and well-being.

REFERENCES

- Liu Y, Dash A, Krez A, et al. Low volumetric bone density is a risk factor for early complications after spine fusion surgery. *Osteoporos Int*. 2020;31(4):647–654. doi:10.1007/s00198-019-05245-7
- Hasegawa K, Abe M, Washio T, Hara T. An experimental study on the interface strength between titanium mesh cage and vertebra in reference to vertebral bone mineral density. *Spine (Phila Pa 1986)*. 2001;26(8):957–963.
- St Jeor JD, Jackson TJ, Xiong AE, et al. Average lumbar hounsfield units predicts osteoporosis-related complications following lumbar spine fusion. *Glob Spine J*. 2022;12(5):851–857. doi:10.1177/2192568220975365
- Wang M, Mummaneni PV, Xi Z, et al. Lower hounsfield units on CT are associated with cage subsidence after anterior cervical discectomy and fusion. *J Neurosurg*. 2020;33(4):425–432. doi:10.3171/2020.3.SPINE2035
- Xi Z, Mummaneni PV, Wang M, et al. The association between lower hounsfield units on computed tomography and cage subsidence after lateral lumbar interbody fusion. *Neurosurg Focus*. 2020;49(2). doi:10.3171/2020.5.FOCUS20169
- Kim KH, Kim T-H, Kim SW, et al. Significance of measuring lumbar spine 3-dimensional computed tomography hounsfield units to predict screw loosening. *World Neurosurg*. 2022;165:e555–e562. doi:10.1016/j.wneu.2022.06.104
- Wang Q, Wang C, Zhang X, et al. Correlation of vertebral trabecular attenuation in hounsfield units and the upper instrumented vertebra with proximal junctional failure after surgical treatment of degenerative lumbar disease. *J Neurosurg Spine*. 2021;34(3):456–463. doi:10.3171/2020.7.SPINE20920
- Yao Y-C, Elysee J, Lafage R, et al. Preoperative hounsfield units at the planned upper instrumented vertebrae may predict proximal junctional kyphosis in adult spinal deformity. *Spine*. 2021;46(3):E174–E180. doi:10.1097/BRS.0000000000003798
- US Preventive Task Force, Curry SJ, Krist AH, et al. Screening for osteoporosis to prevent fractures: US preventive services task force recommendation statement. *JAMA*. 2018;319(24):2521–2531. doi:10.1001/jama.2018.7498
- Agaronnik ND, Giberson-Chen C, Bono CM. Using advanced imaging to measure bone density, compression fracture risk, and risk for construct failure after spine surgery. *Spine J*. 2024;24(7):1135–1152. doi:10.1016/j.spinee.2024.02.018
- Pennington Z, Ehresman J, Lubelski D, et al. Assessing underlying bone quality in spine surgery patients: a narrative review of dual-energy x-ray absorptiometry (DXA) and alternatives. *Spine J*. 2021;21(2):321–331. doi:10.1016/j.spinee.2020.08.020
- Berven SH, Kamper SJ, Germscheid NM, et al. An international consensus on the appropriate evaluation and treatment for adults with spinal deformity. *Eur Spine J*. 2018;27(3):585–596. doi:10.1007/s00586-017-5241-1
- Karunanithi R, Ganesan S, Panicker TMR, Korath MP, Jagadeesan K. Assessment of bone mineral density by DXA and the trabecular microarchitecture of the calcaneum by texture analysis in pre- and postmenopausal women in the evaluation of osteoporosis. *J Med Phys*. 2007;32(4):161–168. doi:10.4103/0971-6203.37481
- Lewiecki EM, Gordon CM, Baim S, et al. International society for clinical densitometry 2007 adult and pediatric official positions. *Bone*. 2008;43(6):1115–1121. doi:10.1016/j.bone.2008.08.106
- Camacho PM, Petak SM, Binkley N, et al. American Association of Clinical Endocrinologists and American College of Endocrinology clinical practice guidelines for the diagnosis and treatment of postmenopausal osteoporosis - 2016--executive summary. *Endocr Pract*. 2016;22(9):1111–1118. doi:10.4158/EP161435.ESGL
- Nelson HD, Haney EM, Dana T, Bougatsos C, Chou R. Screening for osteoporosis: an update for the U.S. preventive services task force. *Ann Intern Med*. 2010;153(2):99–111. doi:10.7326/0003-4819-153-2-201007200-00262
- Masud T, Langley S, Wiltshire P, Doyle DV, Spector TD. Effect of spinal osteophytosis on bone mineral density measurements in vertebral osteoporosis. *BMJ*. 1993;307(6897):172–173. doi:10.1136/bmj.307.6897.172
- Sanders KM, Nicholson GC, Watts JJ, et al. Half the burden of fragility fractures in the community occur in women without osteoporosis. *When is fracture prevention cost-effective? Bone*. 2006;38(5):694–700. doi:10.1016/j.bone.2005.06.004
- Trajanoska K, Schoufour JD, de Jonge EAL, et al. Fracture incidence and secular trends between 1989 and 2013 in a population based cohort: the Rotterdam study. *Bone*. 2018;114:116–124. doi:10.1016/j.bone.2018.06.004
- Brownbill RA, Ilich JZ. Measuring body composition in overweight individuals by dual energy x-ray absorptiometry. *BMC Med Imaging*. 2005;5(1). doi:10.1186/1471-2342-5-1

21. Wanderman N, Freedman B, Currier B, Huddleston P, Yaszemski M, Nassr A. Interpreting the DXA analysis: when should you hold off on spinal fusion? *Semin Spine Surg.* 2018;30(1):36–40. doi:10.1053/j.semss.2017.09.007
22. Lehman RA, Kang DG, Wagner SC. Management of osteoporosis in spine surgery. *J Am Acad Orthop Surg.* 2015;23(4):253–263. doi:10.5435/JAAOS-D-14-00042
23. Miyamura S, Kuriyama K, Ebina K, et al. Utility of distal forearm DXA as a screening tool for primary osteoporotic fragility fractures of the distal radius: A case-control study. *JB JS Open Access.* 2020;5(1):e0036. doi:10.2106/JBJS.OA.19.00036
24. The International Society for Clinical Densitometry. *ISCD Official Positions—Adult 2019.* 2019. <https://iscd.org/learn/official-positions/adult-positions/>. Accessed October 20, 2021.
25. Martineau P, Leslie WD. Trabecular bone score (TBS): method and applications. *Bone.* 2017;104:66–72. doi:10.1016/j.bone.2017.01.035
26. Rajan R, Cherian KE, Kapoor N, Paul TV. Trabecular bone score—an emerging tool in the management of osteoporosis. *Indian J Endocrinol Metab.* 2020;24(3):237–243. doi:10.4103/ijem.IJEM_147_20
27. Al-Hashimi L, Klotsche J, Ohrndorf S, Gaber T, Hoff P. Trabecular bone score significantly influences treatment decisions in secondary osteoporosis. *J Clin Med.* 2023;12(12):4147. doi:10.3390/jcm12124147
28. Shevroja E, Reginster J-Y, Lamy O, et al. Update on the clinical use of trabecular bone score (TBS) in the management of osteoporosis: results of an expert group meeting organized by the European Society for Clinical and Economic Aspects of Osteoporosis, Osteoarthritis and Musculoskeletal diseases (ESCEO), and the International Osteoporosis Foundation (IOF) under the auspices of WHO collaborating center for epidemiology of musculoskeletal health and aging. *Osteoporos Int.* 2023;34(9):1501–1529. doi:10.1007/s00198-023-06817-4
29. Goel H, Binkley N, Boggild M, et al. Clinical use of trabecular bone score: the 2023 ISCD official positions. *J Clin Densitom.* 2024;27(1):S1094-6950(23)00102-6:101452. doi:10.1016/j.jocd.2023.101452
30. Kanis JA, Johansson H, Harvey NC, McCloskey EV. A brief history of FRAX. *Arch Osteoporos.* 2018;13(1):118. doi:10.1007/s11657-018-0510-0
31. Kanis JA, Harvey NC, Johansson H, Odén A, Leslie WD, McCloskey EV. FRAX update. *J Clin Densitom.* 2017;20(3):360–367. doi:10.1016/j.jocd.2017.06.022
32. Zerikly R, Demetriou EW. Use of fracture risk assessment tool in clinical practice and fracture risk assessment tool future directions. *Womens Health.* 2024;20. doi:10.1177/17455057241231387
33. Shoback D, Rosen CJ, Black DM, Cheung AM, Murad MH, Eastell R. Pharmacological management of osteoporosis in postmenopausal women: an Endocrine Society guideline update. *J Clin Endocrinol Metab.* 2020;105(3). doi:10.1210/clinem/dgaa048
34. Link TM, Kazakia G. Update on imaging-based measurement of bone mineral density and quality. *Curr Rheumatol Rep.* 2020;22(5):13. doi:10.1007/s11926-020-00892-w
35. Schreiber JJ, Anderson PA, Rosas HG, Buchholz AL, Au AG. Hounsfield units for assessing bone mineral density and strength: a tool for osteoporosis management. *J Bone Joint Surg Am.* 2011;93(11):1057–1063. doi:10.2106/JBJS.J.00160
36. Davidson S, Vecellio A, Flagstad I, et al. Discrepancy between DXA and CT-based assessment of spine bone mineral density. *Spine Deform.* 2023;11(3):677–683. doi:10.1007/s43390-023-00646-5
37. Wanderman N, Glassman SD, Mkorombindo T, Dimar JR, Gum JL, Carreon LY. Evaluation of bone mineral density after instrumented lumbar fusion with computed tomography. *Spine J.* 2022;22(6):951–956. doi:10.1016/j.spinee.2022.02.007
38. Lin M, Ridley L, Seibel MJ. Prediction of low DEXA T-scores by routine computed tomography body scans at different kilovoltage peaks. *J Med Imaging Radiat Oncol.* 2023;67(6):602–608. doi:10.1111/1754-9485.13537
39. Pickhardt PJ, Lauder T, Pooler BD, et al. Effect of IV contrast on lumbar trabecular attenuation at routine abdominal CT: correlation with DXA and implications for opportunistic osteoporosis screening. *Osteoporos Int.* 2016;27(1):147–152. doi:10.1007/s00198-015-3224-9
40. Ehresman J, Pennington Z, Schilling A, et al. Novel MRI-based score for assessment of bone density in operative spine patients. *Spine J.* 2020;20(4):556–562. doi:10.1016/j.spinee.2019.10.018
41. Chang H-K, Hsu T-W, Ku J, et al. Simple parameters of synthetic MRI for assessment of bone density in patients with spinal degenerative disease. *J Neurosurg Spine.* 2022;36(3):414–421. doi:10.3171/2021.6.SPINE21666
42. Pu M, Zhong W, Heng H, et al. Vertebral bone quality score provides preoperative bone density assessment for patients undergoing lumbar spine surgery: a retrospective study. *J Neurosurg Spine.* 2023;1–10. doi:10.3171/2023.1.SPINE221187
43. Haffer H, Muellner M, Chiapparelli E, et al. Bone quality in patients with osteoporosis undergoing lumbar fusion surgery: analysis of the MRI-based vertebral bone quality score and the bone microstructure derived from microcomputed tomography. *Spine J.* 2022;22(10):S1529-9430(22)00243-1:1642–1650. doi:10.1016/j.spinee.2022.05.008
44. Aynaszyan S, Devia LG, Udoeyo IF, Badve SA, DelSole EM. Patient physiology influences the MRI-based vertebral bone quality score. *Spine J.* 2022;22(11):1866–1874. doi:10.1016/j.spinee.2022.06.003
45. Gupta A, Cha T, Schwab J, et al. Osteoporosis is under recognized and undertreated in adult spinal deformity patients. *J Spine Surg.* 2021;7(1):1–7. doi:10.21037/jss-20-668
46. Sardar ZM, Coury JR, Cerpa M, et al. Best practice guidelines for assessment and management of osteoporosis in adult patients undergoing elective spinal reconstruction. *Spine.* 2022;47(2):128–135. doi:10.1097/BRS.0000000000004268
47. Schömig F, Becker L, Schönnagel L, et al. Avoiding spinal implant failures in osteoporotic patients: a narrative review. *Glob Spine J.* 2023;13(1_suppl):52S–58S. doi:10.1177/21925682231159066
48. Díaz-Romero R, Henríquez MS, Melián KA, Balhen-Martin C. Practice patterns of spine surgeons regarding osteoporosis: an international survey. *Int J Spine Surg.* 2021;15(2):376–385. doi:10.14444/8049
49. Pantoja S, Molina M. Surgeon management of osteoporosis in instrumented spine surgery: a spine latin america survey. *Glob Spine J.* 2019;9(2):169–172. doi:10.1177/2192568218785369
50. Somma T, De Rosa A, Mastantuoni C, et al. Multidisciplinary management of osteoporotic vertebral fractures. *Minerva Endocrinol.* 2022;47(2):189–202. doi:10.23736/S2724-6507.21.03515-6
51. Laird E, Ward M, McSorley E, Strain JJ, Wallace J. Vitamin D and bone health: potential mechanisms. *Nutrients.* 2010;2(7):693–724. doi:10.3390/nu2070693
52. Xu Y, Zhou M, Liu H, et al. Effect of 1,25-dihydroxyvitamin D3 on posterior transforaminal lumbar interbody fusion in patients

with osteoporosis and lumbar disc degenerative disease. *Zhong Xiu Fu Chong Jian Wai Ke Za Zhi*. 2014;28(8):969–972.

53. Russow G, Jahn D, Appelt J, Märdian S, Tsitsilonis S, Keller J. Anabolic therapies in osteoporosis and bone regeneration. *Int J Mol Sci*. 2018;20(1). doi:10.3390/ijms20010083

54. van den Bergh JPW, Bours SPG, van Geel T, Geusens PP. Optimal use of vitamin D when treating osteoporosis. *Curr Osteoporos Rep*. 2011;9(1):36–42. doi:10.1007/s11914-010-0041-0

55. Heravi AS, Michos ED. Vitamin D and calcium supplements: helpful, harmful, or neutral for cardiovascular risk? *Methodist Debakey Cardiovasc J*. 2019;15(3):207–213. doi:10.14797/mdcj-15-3-207

56. Genev IK, Tobin MK, Zaidi SP, Khan SR, Amirouche FML, Mehta AI. Spinal compression fracture management: a review of current treatment strategies and possible future avenues. *Glob Spine J*. 2017;7(1):71–82. doi:10.1055/s-0036-1583288

57. Watts NB, Diab DL. Long-term use of bisphosphonates in osteoporosis. *J Clin Endocrinol Metab*. 2010;95(4):1555–1565. doi:10.1210/jc.2009-1947

58. Dimar J, Bisson EF, Dhall S, et al. Congress of neurological surgeons systematic review and evidence-based guidelines for perioperative spine: preoperative osteoporosis assessment. *Neurosurgery*. 2021;89(Suppl 1):S19–S25. doi:10.1093/neuros/nyab317

59. Nagahama K, Kanayama M, Togawa D, Hashimoto T, Minami A. Does alendronate disturb the healing process of posterior lumbar interbody fusion? A prospective randomized trial. *J Neurosurg Spine*. 2011;14(4):500–507. doi:10.3171/2010.11.SPINE10245

60. Kim S-M, Rhee W, Ha S, Lim JH, Jang IT. Influence of alendronate and endplate degeneration to single level posterior lumbar spinal interbody fusion. *Korean J Spine*. 2014;11(4):221–226. doi:10.14245/kjs.2014.11.4.221

61. Zhang AS, Khatri S, Balmaceno-Criss M, Alsoof D, Daniels AH. Medical optimization of osteoporosis for adult spinal deformity surgery: a state-of-the-art evidence-based review of current pharmacotherapy. *Spine Deform*. 2023;11(3):579–596. doi:10.1007/s43390-022-00621-6

62. Canalis E. Management of endocrine disease: novel anabolic treatments for osteoporosis. *Eur J Endocrinol*. 2018;178(2):R33–R44. doi:10.1530/EJE-17-0920

63. Kellier-Steele N, Casso D, Anderson A, Oliveria SA, Motsko S. Assessing the incidence of osteosarcoma among teriparatide-treated patients using linkage of commercial pharmacy and state cancer registry data, contributing to the removal of boxed warning and other labeling changes. *Bone*. 2022;160:116394. doi:10.1016/j.bone.2022.116394

64. Kumagai Y, Ose A, Tanaka K, Sugimoto T. Safety profiles, pharmacokinetics, and changes in bone turnover markers after twice-weekly subcutaneous administration of teriparatide in healthy Japanese postmenopausal women: a single-blind randomized study. *Clin Pharmacol Drug Dev*. 2020;9(1):87–96. doi:10.1002/cpdd.687

65. Vahle JL, Long GG, Sandusky G, Westmore M, Ma YL, Sato M. Bone neoplasms in F344 rats given teriparatide [rhPTH(1-34)] are dependent on duration of treatment and dose. *Toxicol Pathol*. 2004;32(4):426–438. doi:10.1080/01926230490462138

66. Ohtori S, Inoue G, Orita S, et al. Teriparatide accelerates lumbar posterolateral fusion in women with postmenopausal osteoporosis: prospective study. *Spine*. 2012;37(23):E1464–E1468. doi:10.1097/BRS.0b013e31826ca2a8

67. Cho PG, Ji GY, Shin DA, Ha Y, Yoon DH, Kim KN. An effect comparison of teriparatide and bisphosphonate on posterior

lumbar interbody fusion in patients with osteoporosis: a prospective cohort study and preliminary data. *Eur Spine J*. 2017;26(3):691–697. doi:10.1007/s00586-015-4342-y

68. Miller PD. Denosumab: anti-RANKL antibody. *Curr Osteoporos Rep*. 2009;7(1):18–22. doi:10.1007/s11914-009-0004-5

69. Tsourdi E, Zillikens MC, Meier C, et al. Fracture risk and management of discontinuation of denosumab therapy: a systematic review and position statement by ECTS. *J Clin Endocrinol Metab*. 2020;26:dga756. doi:10.1210/clinem/dga756

70. Camacho PM, Petak SM, Binkley N, et al. American Association of Clinical Endocrinologists/American College of Endocrinology clinical practice guidelines for the diagnosis and treatment of postmenopausal osteoporosis-2020 update. *Endocr Pract*. 2020;26(Suppl 1):1–46. doi:10.4158/GL-2020-0524SUPPL

71. Leder BZ, Tsai JN, Uihlein AV, et al. Denosumab and teriparatide transitions in postmenopausal osteoporosis (the DATA-switch study): extension of a randomised controlled trial. *Lancet*. 2015;386(9999):S0140-6736(15)61120-5:1147–1155. doi:10.1016/S0140-6736(15)61120-5

72. Ide M, Yamada K, Kaneko K, et al. Combined teriparatide and denosumab therapy accelerates spinal fusion following posterior lumbar interbody fusion. *Orthop Traumatol Surg Res*. 2018;104(7):1043–1048. doi:10.1016/j.otsr.2018.07.015

73. Fujita N, Yagi M, Watanabe K, et al. Determining the validity and reliability of spinopelvic parameters through comparing standing whole spinal radiographs and upright computed tomography images. *BMC Musculoskelet Disord*. 2021;22(1). doi:10.1186/s12891-021-04786-5

74. Chen R-Q, Hosogane N, Watanabe K, et al. Reliability analysis of spino-pelvic parameters in adult spinal deformity: a comparison of whole spine and pelvic radiographs. *Spine*. 2016;41(4):320–327. doi:10.1097/BRS.0000000000001208

75. Illés T, Somoskeöy S. The EOS. *Int Orthop*. 2012;36(7):1325–1331. doi:10.1007/s00264-012-1512-y

76. Shakeri M, Mahdavi SM, Rikhtehgar M, et al. EOS® is reliable to evaluate spinopelvic parameters: a validation study. *BMC Med Imaging*. 2024;24(1):35. doi:10.1186/s12880-023-01178-0

77. Lee NJ, Zuckerman SL, Buchanan IA, et al. Is there a difference between navigated and non-navigated robot cohorts in robot-assisted spine surgery? A multicenter, propensity-matched analysis of 2,800 screws and 372 patients. *Spine J*. 2021;21(9):1504–1512. doi:10.1016/j.spinee.2021.05.015

78. Khan A, Meyers JE, Siasios I, Pollina J. Next-generation robotic spine surgery: first report on feasibility, safety, and learning curve. *Oper Neurosurg*. 2019;17(1):61–69. doi:10.1093/ons/opy280

79. Ghasem A, Sharma A, Greif DN, Alam M, Maaieh MA. The arrival of robotics in spine surgery: A review of the literature. *Spine (Phila Pa 1976)*. 2018;43(23):1670–1677. doi:10.1097/BRS.0000000000002695

80. Bydon M, Chen SG, Neal MD, et al. Initiation of a robotic program in spinal surgery: experience at a three-site medical center. *Mayo Clin Proc*. 2021;96(5):S0025-6196(20)30930-7:1193–1202. doi:10.1016/j.mayocp.2020.07.034

81. Roser F, Tatagiba M, Maier G. Spinal robotics: current applications and future perspectives. *Neurosurgery*. 2013;72 Suppl 1:12–18. doi:10.1227/NEU.0b013e318270d02c

82. Choy WJ, Parr WCH, Phan K, Walsh WR, Mobbs RJ. 3-dimensional printing for anterior cervical surgery: a review. *J Spine Surg*. 2018;4(4):757–769. doi:10.21037/jss.2018.12.01

83. Fiani B, Newhouse A, Cathel A, Sarhadi K, Soula M. Implications of 3-dimensional printed spinal implants on the outcomes

- in spine surgery. *J Korean Neurosurg Soc.* 2021;64(4):495–504. doi:10.3340/jkns.2020.0272
84. D’Urso PS, Askin G, Earwaker JS, et al. Spinal biomodeling. *Spine.* 1999;24(12):1247–1251. doi:10.1097/00007632-199906150-00013
85. Wang Y-T, Yang X-J, Yan B, Zeng T-H, Qiu Y-Y, Chen S-J. Clinical application of three-dimensional printing in the personalized treatment of complex spinal disorders. *Chin J Traumatol.* 2016;19(1):31–34. doi:10.1016/j.cjtee.2015.09.009
86. Mobbs RJ, Coughlan M, Thompson R, Sutterlin CE, Phan K. The utility of 3D printing for surgical planning and patient-specific implant design for complex spinal pathologies: case report. *SPI.* 2017;26(4):513–518. doi:10.3171/2016.9.SPINE16371
87. Zhuang H, Wei F, Jiang L, Wang Y, Liu Z. Assessment of spinal tumor treatment using implanted 3D-printed vertebral bodies with robotic stereotactic radiotherapy. *Innov Camb.* 2020;1(2). doi:10.1016/j.xinn.2020.100040
88. Wu W, Li F, Fang Z, et al. Total spondylectomy of C2 and circumferential reconstruction via combined anterior and posterior approach to cervical spine for axis tumor surgery. *J Huazhong Univ Sci Technol.* 2013;33(1):126–132. doi:10.1007/s11596-013-1084-0
89. Yang M, Li C, Li Y, et al. Application of 3D rapid prototyping technology in posterior corrective surgery for lenke I adolescent idiopathic scoliosis patients. *Medicine.* 2015;94(8). doi:10.1097/MD.0000000000000582
90. Warburton A, Girdler SJ, Mikhail CM, Ahn A, Cho SK. Biomaterials in spinal implants: a review. *Neurospine.* 2020;17(1):101–110. doi:10.14245/ns.1938296.148
91. Serhan H, Mhatre D, Newton P, Giorgio P, Sturm P. Would coCr rods provide better correctional forces than stainless steel or titanium for rigid scoliosis curves? *J Spinal Disord Tech.* 2013;26(2):E70–E74. doi:10.1097/BSD.0b013e31826a0f19
92. Han S, Hyun S-J, Kim K-J, Jahng T-A, Lee S, Rhim S-C. Rod stiffness as a risk factor of proximal junctional kyphosis after adult spinal deformity surgery: comparative study between cobalt chrome multiple-rod constructs and titanium alloy two-rod constructs. *Spine J.* 2017;17(7):962–968. doi:10.1016/j.spinee.2017.02.005
93. Bowden D, Michielli A, Merrill M, Will S. Systematic review and meta-analysis for the impact of rod materials and sizes in the surgical treatment of adult spine deformity. *Spine Deform.* 2022;10(6):1265–1278. doi:10.1007/s43390-022-00556-y
94. Huber FA, Sprengel K, Müller L, Graf LC, Osterhoff G, Guggenberger R. Comparison of different CT metal artifact reduction strategies for standard titanium and carbon-fiber reinforced polymer implants in sheep cadavers. *BMC Med Imaging.* 2021;21(1). doi:10.1186/s12880-021-00554-y
95. Ghermandi R, Tosini G, Lorenzi A, et al. Carbon fiber-reinforced polyetheretherketone (CFR-PEEK) instrumentation in degenerative disease of lumbar spine: a pilot study. *Bioeng.* 2023;10(7). doi:10.3390/bioengineering10070872
96. Chen Y, Wang X, Lu X, et al. Comparison of titanium and polyetheretherketone (PEEK) cages in the surgical treatment of multilevel cervical spondylotic myelopathy: a prospective, randomized, control study with over 7-year follow-up. *Eur Spine J.* 2013;22(7):1539–1546. doi:10.1007/s00586-013-2772-y
97. Zavras AG, Schoenfeld AJ, Patt JC, et al. Attitudes and trends in the use of radiolucent spinal implants: a survey of the north american spine society section of spinal oncology. *N Am Spine Soc J.* 2022;10:100105. doi:10.1016/j.xnsj.2022.100105
98. Song F, Liu Y, Fu R, et al. Craniocaudal toggling increases the risk of screw loosening in osteoporotic vertebrae. *Comput Methods Programs Biomed.* 2023;238:S0169-2607(23)00290-0:107625. doi:10.1016/j.cmpb.2023.107625
99. Jia C, Zhang R, Wang J, et al. Biomechanical study of 3 osteoconductive materials applied in pedicle augmentation and revision for osteoporotic vertebrae: allograft bone particles, calcium phosphate cement, demineralized bone matrix. *Neurospine.* 2023;20(4):1407–1420. doi:10.14245/ns.2346760.380
100. Sudo H, Tachi H, Kokabu T, et al. In vivo deformation of anatomically pre-bent rods in thoracic adolescent idiopathic scoliosis. *Sci Rep.* 2021;11(1). doi:10.1038/s41598-021-92187-y
101. Thomas ES, Boyer N, Meyers A, Aziz H, Aminian A. Restoration of thoracic kyphosis in adolescent idiopathic scoliosis with patient-specific rods: did the preoperative plan match postoperative sagittal alignment? *Eur Spine J.* 2023;32(1):190–201. doi:10.1007/s00586-022-07437-y
102. Faulks CR, Biddau DT, Munday NR, McKenzie DP, Malham GM. Patient-specific spinal rods in adult spinal deformity surgery reduce proximal junctional failure: a review of patient outcomes and surgical technique in a prospective observational cohort. *J Spine Surg.* 2023;9(4):409–421. doi:10.21037/jss-23-85
103. Barton C, Noshchenko A, Patel V, Kleck C, Burger E. Early experience and initial outcomes with patient-specific spine rods for adult spinal deformity. *Orthopedics.* 2016;39(2):79–86. doi:10.3928/01477447-20160304-04
104. Ou-Yang D, Burger EL, Kleck CJ. Global spine J. 2022;12(2_suppl):40S–44S. doi:10.1177/21925682211055096
105. Hsieh M-K, Lee D-M, Chen W-P, et al. Forcefully engaging rods into tulips with gap discrepancy leading to pedicle screw loosening—a biomechanical analysis using long porcine spine segments. *Spine J.* 2024;16. doi:10.1016/j.spinee.2024.03.008
106. von Atzigen M, Liebmann F, Cavalcanti NA, et al. Reducing residual forces in spinal fusion using a custom-built rod bending machine. *Comput Methods Programs Biomed.* 2024;247. doi:10.1016/j.cmpb.2024.108096
107. Rajasekaran S, Vidyadhara S, Ramesh P, Shetty AP. Randomized clinical study to compare the accuracy of navigated and non-navigated thoracic pedicle screws in deformity correction surgeries. *Spine.* 2007;32(2):E56–E64. doi:10.1097/01.brs.0000252094.64857.ab
108. Tormenti MJ, Kostov DB, Gardner PA, Kanter AS, Spiro RM, Okonkwo DO. Intraoperative computed tomography image-guided navigation for posterior thoracolumbar spinal instrumentation in spinal deformity surgery. *Neurosurg Focus.* 2010;28(3). doi:10.3171/2010.1.FOCUS09275
109. Van de Kelft E, Costa F, Van der Planken D, Schils F. A prospective multicenter registry on the accuracy of pedicle screw placement in the thoracic, lumbar, and sacral levels with the use of the O-arm imaging system and stealthstation navigation. *Spine.* 2012;37(25):E1580–E1587. doi:10.1097/BRS.0b013e318271b1fa
110. Cui G, Wang Y, Kao T-H, et al. Application of intraoperative computed tomography with or without navigation system in surgical correction of spinal deformity: a preliminary result of 59 consecutive human cases. *Spine.* 2012;37(10):891–900. doi:10.1097/BRS.0b013e31823aff81
111. Laufenberg-Feldmann R, Kappis B, Mauff S, Schmidtman I, Ferner M. Prevalence of pain 6 months after surgery: a prospective observational study. *BMC Anesth.* 2016;16(1):91. doi:10.1186/s12871-016-0261-7
112. White PF, Kehlet H. Improving postoperative pain management: what are the unresolved issues? *Anesthesiology.* 2010;112(1):220–225. doi:10.1097/ALN.0b013e3181c6316e

113. Ernst S, Huang W, Conley Y, Vo N, Schneider M, Sowa G. Pain-related single nucleotide polymorphisms: association with lumbar spinal stenosis patient experience and non-surgical treatment outcomes. *Eur Spine J.* 2024;33(6):2213–2221. doi:10.1007/s00586-024-08182-0
114. Rakvåg TT, Ross JR, Sato H, Skorpen F, Kaasa S, Klepstad P. Genetic variation in the catechol-O-methyltransferase (COMT) gene and morphine requirements in cancer patients with pain. *Mol Pain.* 2008;4:1744–8069. doi:10.1186/1744-8069-4-64
115. Diatchenko L, Nackley AG, Slade GD, et al. Catechol-O-methyltransferase gene polymorphisms are associated with multiple pain-evoking stimuli. *Pain.* 2006;125(3):216–224. doi:10.1016/j.pain.2006.05.024
116. Kim DH, Dai F, Belfer I, et al. Polymorphic variation of the guanosine triphosphate cyclohydrolase 1 gene predicts outcome in patients undergoing surgical treatment for lumbar degenerative disc disease. *Spine.* 2010;35(21):1909–1914. doi:10.1097/BRS.0b013e3181eea007
117. Lötsch J, Skarke C, Liefhold J, Geisslinger G. Genetic predictors of the clinical response to opioid analgesics: clinical utility and future perspectives. *Clin Pharmacokinet.* 2004;43(14):983–1013. doi:10.2165/00003088-200443140-00003
118. Tegeder I, Costigan M, Griffin RS, et al. GTP cyclohydrolase and tetrahydrobiopterin regulate pain sensitivity and persistence. *N Med.* 2006;12(11):1269–1277. doi:10.1038/nm1490
119. Chidambaran V, Zhang X, Martin LJ, et al. DNA methylation at the mu-1 opioid receptor gene (*oprm1*) promoter predicts preoperative, acute, and chronic postsurgical pain after spine fusion. *Pharmacogenomics Pers Med.* 2017;10:157–168. doi:10.2147/PGPM.S132691
120. Coulbault L, Beaussier M, Verstuyft C, et al. Environmental and genetic factors associated with morphine response in the postoperative period. *Clin Pharmacol Ther.* 2006;79(4):316–324. doi:10.1016/j.clpt.2006.01.007
121. Hara Y, Nakajima M, Miyamoto K, Yokoi T. Morphine glucuronosyltransferase activity in human liver microsomes is inhibited by a variety of drugs that are co-administered with morphine. *Drug Metab Pharmacokinet.* 2007;22(2):103–112. doi:10.2133/dmpk.22.103
122. Park C, Mummaneni PV, Gottfried ON, et al. Which supervised machine learning algorithm can best predict achievement of minimum clinically important difference in neck pain after surgery in patients with cervical myelopathy? A QOD study. *Neurosurg Focus.* 2023;54(6). doi:10.3171/2023.3.FOCUS2372
123. Berg B, Gorosito MA, Fjeld O, et al. Machine learning models for predicting disability and pain following lumbar disc herniation surgery. *JAMA Netw Open.* 2024;7(2). doi:10.1001/jamanetworkopen.2023.55024
124. Karhade AV, Ogink PT, Thio Q, et al. Development of machine learning algorithms for prediction of prolonged opioid prescription after surgery for lumbar disc herniation. *Spine J.* 2019;19(11):1764–1771. doi:10.1016/j.spinee.2019.06.002
125. Millisdotter M, Strömquist B. Early neuromuscular customized training after surgery for lumbar disc herniation: a prospective controlled study. *Eur Spine J.* 2007;16(1):19–26. doi:10.1007/s00586-005-0044-1
126. Halvorson RT, Torres-Espin A, Callahan M, et al. Multi-domain biopsychosocial postoperative recovery trajectories associate with patient outcomes following lumbar fusion. *Eur Spine J.* 2023;32(4):1429–1436. doi:10.1007/s00586-023-07572-0
127. Moens M, Goudman L, Van de Velde D, et al. Personalised rehabilitation to improve return to work in patients with persistent spinal pain syndrome type II after spinal cord stimulation implantation: a study protocol for a 12-month randomised controlled trial—the OPERA study. *Trials.* 2022;23(1). doi:10.1186/s13063-022-06895-5
128. DeVries Z, Hoda M, Rivers CS, et al. Development of an unsupervised machine learning algorithm for the prognostication of walking ability in spinal cord injury patients. *Spine J.* 2020;20(2):213–224. doi:10.1016/j.spinee.2019.09.007
129. Ahmad HS, Yang AI, Basil GW, Welch WC, Wang MY, Yoon JW. Towards personalized and value-based spine care: objective patient monitoring with smartphone activity data. *J Spine Surg.* 2022;8(1):87–92. doi:10.21037/jss-21-67
130. Glauser G, Ali ZS, Gardiner D, et al. Assessing the utility of an ios application in the perioperative care of spine surgery patients: the neuropath pilot study. *Mhealth.* 2019;5. doi:10.21037/mhealth.2019.09.01
131. Likitlersuang J, Sumitro ER, Theventhiran P, Kalsi-Ryan S, Zariffa J. Views of individuals with spinal cord injury on the use of wearable cameras to monitor upper limb function in the home and community. *J Spinal Cord Med.* 2017;40(6):706–714. doi:10.1080/10790268.2017.1349856
132. Adogwa O, Martin JR, Huang K, et al. Preoperative serum albumin level as a predictor of postoperative complication after spine fusion. *Spine.* 2014;39(18):1513–1519. doi:10.1097/BRS.0000000000000450
133. Qureshi R, Rasool M, Puvanesarajah V, Hassanzadeh H. Perioperative nutritional optimization in spine surgery. *Clin Spine Surg.* 2018;31(3):103–107. doi:10.1097/BSD.0000000000000579
134. Rigney GH, Massaad E, Kiapour A, et al. Implication of nutritional status for adverse outcomes after surgery for metastatic spine tumors. *J Neurosurg Spine.* 2023;39(4):557–567. doi:10.3171/2023.5.SPINE2367
135. Elsamadicy AA, Havlik J, Reeves BC, et al. Effects of preoperative nutritional status on complications and readmissions after posterior lumbar decompression and fusion for spondylolisthesis: a propensity-score analysis. *Clin Neurol Neurosurg.* 2021;211. doi:10.1016/j.clineuro.2021.107017

Funding: The authors received no financial support for the research, authorship, and/or publication of this article.

Declaration of Conflicting Interests: The authors report no conflicts of interest in this work.

Disclosures: P.V.M. serves as a consultant for DePuy Spine and Globus, has direct stock ownership in Discgenics, receives royalties from Thieme Publishers and Springer Publishing, has received support from ISSG, NREF, AOSpine, NIH, PCORI, SLIP II, Pacira, and DoD for nonstudy-related clinical or research effort, and receives honoraria from BK Medical, Brainlab, and SI Bone. E.C.H. serves in an unpaid capacity on the Medical Registry Advisory Board of the International Fibrodysplasia Ossificans Progressiva Association; the Fibrous Dysplasia Foundation Medical Advisory

Board; and the International Clinical Council on FOP. E.C.H. also receives clinical trials support through his institution from Clementia Pharmaceuticals, an Ipsen Company; Ipsen Pharmaceuticals; Ascendis Bio; and ashbio.

Editor's Note: Editor's Note: This article is an addendum to the August 2024 IJSS special issue on personalized medicine in spine surgery. View the full special issue at <https://www.ijssurgery.com/content/18/S1>.

Corresponding Author: Arati Patel, Resident Physician Department of Neurological Surgery, University of California San Francisco, 7th floor Neurosurgery Office, 505 Parnassus Ave, San Francisco, CA 94143, USA; arati.patel@ucsf.edu

Published 27 August 2024

This manuscript is generously published free of charge by ISASS, the International Society for the Advancement of Spine Surgery. Copyright © 2024 ISASS. To see more or order reprints or permissions, see <http://ijssurgery.com>.