

Radiographic Alignment in Deformity Patients Treated With Personalized Interbody Devices: Early Experience From the COMPASS Registry

Roland S. Kent, Christopher P. Ames, Jahangir Asghar, Donald J. Blaskiewicz, Joseph A. Osorio, Chun-Po Yen, Jeffrey Mullin, Justin S. Smith, John M. Small, Michele Temple-Wong and Jeffrey D. Schwardt

Int J Spine Surg 2024, 18 (S1) S6-S15
doi: <https://doi.org/10.14444/8636>
<https://www.ijssurgery.com/content/18/S1/S6>

This information is current as of September 2, 2024.

Email Alerts Receive free email-alerts when new articles cite this article. Sign up at:
<http://ijssurgery.com/alerts>

Radiographic Alignment in Deformity Patients Treated With Personalized Interbody Devices: Early Experience From the COMPASS Registry

ROLAND S. KENT, MD¹; CHRISTOPHER P. AMES, MD²; JAHANGIR ASGHAR, MD³; DONALD J. BLASKIEWICZ, MD⁴; JOSEPH A. OSORIO, MD, PhD⁵; CHUN-PO YEN, MD⁶; JEFFREY MULLIN, MD, MBA⁷; JUSTIN S. SMITH, MD, PhD⁸; JOHN M. SMALL, MD⁹; MICHELE TEMPLE-WONG, PhD¹⁰; AND JEFFREY D. SCHWARDT, PhD¹⁰

¹Department of Spine Surgery, Axis Spine Center, Coeur d'Alene, ID, USA; ²Department of Neurological Surgery, University of California, San Francisco, CA, USA; ³Department of Spine Surgery, Elite Spine Health and Wellness, Plantation, FL, USA; ⁴Department of Spine Surgery, St. Luke's Boise Medical Center, Boise, ID, USA; ⁵Department of Neurological Surgery, University of California, San Diego, CA, USA; ⁶Department of Neurosurgery, University of Virginia, Charlottesville, VA, USA; ⁷Department of Neurosurgery, University at Buffalo, Buffalo, NY, USA; ⁸Department of Neurosurgery, University of Virginia, Charlottesville, VA, USA; ⁹Department of Spine Surgery, Center for Spinal Disorders at Florida Orthopedic Institute, Temple Terrace, FL, USA; ¹⁰Department of Clinical Science, Carlsmed, Carlsbad, CA, USA

ABSTRACT

Background: Literature supports the need for improved techniques to achieve spinopelvic alignment and reduce complication rates in patients with adult spinal deformity (ASD). Personalized interbody devices were developed to address this need and are under evaluation in the multicenter Clinical Outcome Measures in Personalized ^{aprevo} (circle R superscript) Spine Surgery (COMPASS (TM superscript) registry). This report presents interim COMPASS pre- and postoperative sagittal alignment results and complication rates for a subcohort of COMPASS patients diagnosed and surgically treated for spinal deformity.

Methods: COMPASS is a postmarket observational registry of patients enrolled either before or after index surgery and then followed prospectively for 24 months. Sagittal alignment was assessed with SRS-Schwab modifiers for pelvic incidence minus lumbar lordosis, pelvic tilt, and T1 pelvic angle. Summed SRS-Schwab modifiers were utilized to assign overall deformity status as mild, moderate, or severe. Complications were extracted from patient medical records.

Results: The study included 67 patients from 9 centers. Preoperative severe deformity was observed in 66% of patients. Index surgeries included implantation of a median of 2 personalized interbody devices by anterior, lateral, or transforaminal approaches and with a median of 8 posteriorly instrumented levels. Overall postoperative sagittal alignment improved with a significant decrease in the mean sum of SRS-Schwab modifiers that correlated strongly to improvements in pelvic incidence minus lumbar lordosis. Among 44 patients with preoperative severe overall deformity, 16 improved to moderate and 9 to mild deformity. Complications occurred for 13 patients (19.4%), including 1 mechanical complication requiring revision 9 months after surgery and none related to personalized interbody devices.

Conclusions: This study demonstrates that ASD patients whose treatment included personalized interbody devices can obtain favorable postoperative alignment status comparable to published results and with no complications related to the personalized interbody devices.

Clinical Relevance: This study contributes to growing evidence that personalized interbody devices contribute to improved sagittal alignment in ASD patients by directly adjusting the orientation of adjacent vertebra.

Level of Evidence: 3.

Lumbar Spine

Keywords: personalized interbody devices, adult spinal deformity, SRS-Schwab

INTRODUCTION

Historically, patients treated surgically for spinal deformity have had high rates of new or persistent postoperative malalignment and complications requiring revision surgery. To address these issues, personalized interbody devices have been developed to predictably control the disc space and the resulting segmental and regional spinal alignment. As with any new medical technology, it is important to study the effectiveness and

outcomes. Toward this objective, the multicenter Clinical Outcome Measures in Personalized ^{aprevo} Spine Surgery (COMPASS (TM superscript)) observational registry has been established. This ongoing registry enables the collection of baseline, operative, and follow-up data on patients treated with spinal fusion that included personalized interbody devices. The overall objective of this registry effort is to assess whether the utilization of personalized interbody devices in the surgical treatment of spinal deformity and/or degenerative

pathologies will improve the ability to achieve alignment goals, reduce the risk of interbody subsidence, enhance fusion rates through improved implant-to-endplate contact, and reduce revision rates due to mechanical complications. This report presents interim COMPASS results for a subcohort of COMPASS patients diagnosed and surgically treated for spinal deformity.

While surgical treatment has been shown to be superior to conservative care for adult spinal deformity (ASD) patients,¹ the incidence of adverse events (AEs) and long-term complications is high: Up to 75% of patients still have a radiographic deformity after surgery,² over 40% experience a major AE that is surgery or implant related,³ and over 20% require revision surgery.⁴ For example, Glassman et al showed that among 122 operative ASD patients, 38 (31%) had revision surgery by year 5 postoperatively, 3 patients had 2 revisions, and 1 patient had 3 revisions.⁵ The costs of complications include emotional and physical distress for patients and their families along with the significant financial burden to the healthcare system.⁶

AEs that result in revision surgery are primarily mechanical complications including proximal junctional kyphosis (PJK), pseudoarthrosis, cage subsidence, and rod breakage. PJK has been associated with overcorrection and lordotic disproportion.⁷ Pseudoarthrosis can result from suboptimal loading conditions, specifically the load distribution and contact area between the vertebral endplates and the interbody bone graft. Endplate subsidence can lead to loss of correction as well as pseudoarthrosis. Rod failure can be the result of extreme rod bends or excessive loading over time. When the intervertebral bone fails to fuse, anatomical loads are transferred to the spinal rod, exposing it to excessive loading over time and an increased likelihood of dynamic rod fracture.⁸

Although the focus of this report is on deformity patients, spinal alignment is equally important for surgical patients with degenerative pathologies. Over the past decade, there has been increasing evidence linking the presence of postoperative spinal malalignment in these patients to higher risk for adjacent segment disease requiring surgery.^{7,9,10} Residual postoperative sagittal malalignment in degenerative patients is also a risk factor for mechanical failures, including PJK, that require revision surgery.¹¹ Collectively, current literature strongly supports the need for improved approaches and techniques to better achieve spinopelvic alignment following spine fusion.

This report presents interim results from the COMPASS observational registry for a cohort of

patients who underwent surgical treatments to address ASD. The purpose of this study is to compare pre- and postoperative radiographic sagittal spinopelvic alignment parameters and track complications in ASD patients whose treatment included personalized interbody devices.

METHODS

Creation of Personalized Interbody Devices

Personalized interbody devices (aprevoTM suprascript), Carlsmed, Carlsbad, CA) are cleared by the US Food and Drug Administration, are individually designed for each patient, and are 3D-printed from titanium alloy (Ti-6Al-4V). Three-dimensional spine models are rendered from patient computed tomography and radiographic images and used to specify device dimensions and contours that match and adjust the orientation of adjacent vertebral endplates. The ordering surgeon reviews and approves specifications for planned intervertebral anterior and posterior height along with intervertebral lordotic and coronal angles for each fused level. Personalized devices are available for anterior, lateral, and transforaminal surgical approaches (Figure 1).

Study Design

COMPASS is a postmarket observational registry of patients surgically treated with personalized lumbar interbody devices. Participating patients are enrolled before or after their index surgery and then followed prospectively at intervals of 6 weeks, 6 months, 12 months, and 24 months postoperatively. All 16 participating US centers obtained Institutional Review Board approval prior to study initiation, and all patients provided informed consent.

The present study includes COMPASS patients for whom surgical treatment addressed spinal deformity defined radiographically by the presence of 1 or more moderate or severe sagittal modifiers or coronal deformities according to the SRS/Schwab ASD classification.¹² Thresholds for moderate or severe deformity include sagittal measurements of pelvic incidence minus lumbar lordosis (PI-LL) $\geq 10^\circ$, pelvic tilt (PT) $\geq 20^\circ$, or T1 pelvic angle (T1PA) $\geq 10^\circ$ and coronal angles greater than 30° for thoracic, thoracolumbar, or double curves.¹²⁻¹⁴ Eligible patients underwent index surgeries including 1 or more personalized interbody devices with at least 3 instrumented fusion levels and had pre- and

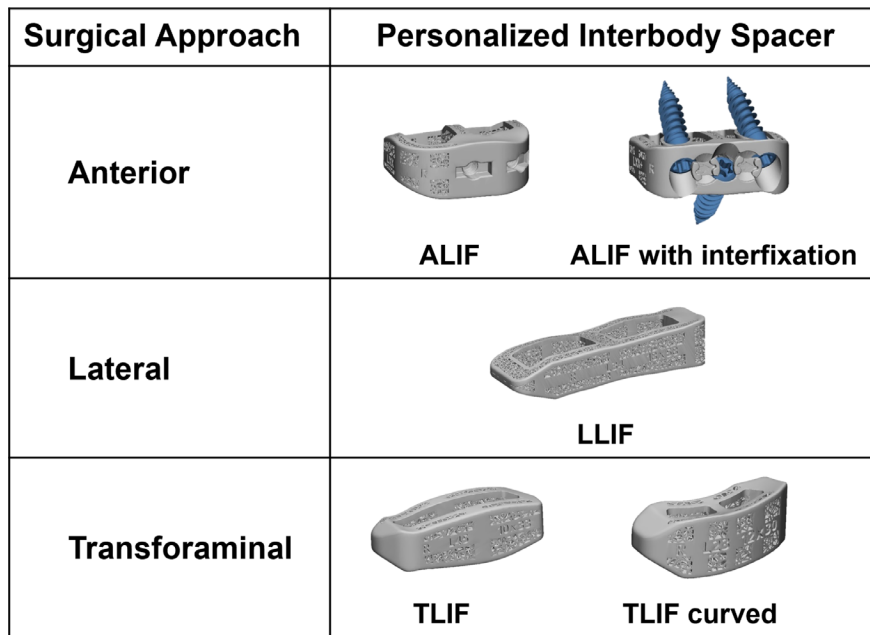


Figure 1. Personalized lumbar interbody devices for anterior lumbar interbody fusion, lateral lumbar interbody fusion, and transforaminal lumbar interbody fusion.

postoperative radiographs available for measurement of spinopelvic alignment parameters.

Radiographic Assessment

The most recent anteroposterior and lateral full-length radiographs of each patient were provided to a central site for radiographic measurements using validated software (SpineView, ENSAM Laboratory of Biomechanics, Paris, France).¹⁵

Spinopelvic parameters, including PI-LL, PT, and T1PA, were used to assess deformity severity utilizing the modifiers from the SRS-Schwab classification for ASD (Table 1).^{12,13} The T1PA modifier, a validated surrogate for sagittal vertical axis (SVA) in the SRS-Schwab classification, represents global sagittal alignment independent of pelvic compensatory mechanisms and thus is a reflection of both PT and SVA.¹⁴ T1PA is also readily available from most full-length lateral spine radiographs, including uncalibrated images. The sum of

the SRS-Schwab sagittal alignment modifiers was then used to categorize the deformity severity as mild, moderate, or severe for each patient (Table 2), as previously described.^{16,17}

AEs and Complications

AEs were assessed for severity based on National Institutes of Health guidelines for serious adverse event (SAE) definitions from the National Institute of Arthritis and Musculoskeletal and Skin Diseases.¹⁸ Complications for this study were defined as SAEs that include any death, life-threatening event, an event that caused significant or permanent disability, or an event that resulted in prolonged or new hospitalization.¹⁹ Occurrences, treatments, and outcomes for AEs were extracted from patient medical records. AEs and complications were categorized as medical or surgical according to the International Spine Study Group-AO Spine complication classification system.^{20,21} Complications were further categorized by (a) occurrence either ≤90 days postoperatively, including intraoperatively, or >90 days postoperatively and (b) for relatedness to a personalized interbody device. Mechanical complications were identified as SAEs resulting from adjacent segment disease

Table 1. Definitions for SRS-Schwab modifiers and severity thresholds for sagittal deformity.

Severity of Deformity	SRS-Schwab Modifier	Modifier Threshold Values		
		PI-LL	PT	T1PA (SVA surrogate)
Mild/none	0	<10°	<20°	<10°
Moderate	+	10°–20°	20°–30°	10°–20°
Severe	++	>20°	>30°	>20°

Abbreviations: PI-LL, pelvic incidence minus lumbar lordosis; PT, pelvic tilt; SVA, sagittal vertical axis; T1PA, T1 pelvic angle.

Table 2. Definition of the sum of SRS-Schwab modifiers.

Deformity Severity	Sum of SRS-Schwab Modifiers
Mild/none	0 to 1+
Moderate	2+ to 3+
Marked/severe	4+ to 6+

including proximal/distal junctional kyphosis and/or implant failure or dislodgement that resulted in reoperation.^{17,20,22,23}

Statistical Methods

Statistical analysis was performed using SPSS software version 29.0.2.0. Demographic, radiographic, and operative data were assessed with descriptive statistics using mean and SD or median and range for continuous data, depending on the distribution and frequencies with percentages for categorical variables. Pre- and postoperative data were compared using a paired *t* test for continuous variables and nonparametric Wilcoxon signed-rank test for ordinal data. Correlations of each SRS-Schwab modifier with the SRS-Schwab modifier sum were performed using Spearman's rank correlation. All tests were 2-tailed with a *P* value <0.05 considered significant.

RESULTS

Cohort Overview

Study data collection for 67 eligible patients occurred at 9 centers (5 academic and 4 nonacademic). Descriptive data for these COMPASS deformity patients are summarized in Table 3. The majority (70%) of patients were women. The mean age was 66.2 ± 10.1 years, and the mean body mass index was 28.6 ± 5.7 kg/m². Half (50%) of patients had a history of previous spine surgery. The mean preoperative spinopelvic alignment measurements exceeded thresholds for moderate or severe deformity for all 3 SRS-Schwab modifiers (Table 3).

The median postoperative follow-up from surgery was 14.7 months and ranged from 3.9 to 39.2 months (Table 4). Forty patients had more than 12-month

Table 3. Demographics, spine surgery history, and preoperative radiographic parameters of the study population.

Variable	Value
Demographics	
<i>N</i>	67
Sex, women, <i>n</i> (%)	47 (70.1)
Age, y, mean (SD)	66.2 (10.1)
BMI, mean (SD)	28.6 (5.7)
Previous spine surgery	
Total, <i>n</i> (%)	34 (50.7)
With instrumentation, <i>n</i> (%)	29 (43.3)
Previous instrumented fusion levels, median (range)	2 (1, 14)
Preoperative radiographic sagittal alignment parameters	
PI-LL mismatch, degrees, mean (SD)	21.0 (16.2)
PT, degrees, mean (SD)	23.8 (8.6)
T1PA, degrees, mean (SD)	25.0 (10.1)

Abbreviations: BMI, body mass index; PI-LL, pelvic incidence minus lumbar lordosis; PT, pelvic tilt; T1PA, T1 pelvic angle.

Table 4. Operative parameters of the study population.

Operative Parameters	Value
Time since surgery, mo, median (range)	14.7 (3.9, 39.2)
Instrumented vertebrae during surgery, median (range)	9 (4, 18)
Personalized interbody devices implanted, median (range)	2 (1, 5)
Cases treated with implant type(s), <i>n</i> (%)	
ALIF	14 (20.9%)
ALIF, LLIF	10 (14.9%)
LLIF	14 (20.9%)
TLIF	29 (43.3%)
UIV, <i>n</i> (%)	
T1	1 (1.5%)
T2	4 (6%)
T3	3 (4.5%)
T4	9 (13.4%)
T5	2 (3%)
T8	1 (1.5%)
T9	13 (19.4%)
T10	24 (35.8%)
L1	2 (3%)
L2	8 (11.9%)
LIV, <i>n</i> (%)	
L2	2 (3%)
L5	2 (3%)
S1	23 (34.3%)
Pelvis	40 (59.7%)

Abbreviations: ALIF, anterior lumbar interbody fusion; LIV, lower instrumented vertebra; LLIF, lateral lumbar interbody fusion; TLIF, transforaminal lumbar interbody fusion; UIV, upper instrumented vertebra.

follow-up, and 9 patients exceeded 24-month follow-up. Surgeries included 4 to 18 posteriorly instrumented vertebra. Among the patients, 43.3% underwent posterior-only approaches with transforaminal lumbar interbody fusion devices, whereas 56.7% had anterior lumbar interbody fusion, lateral lumbar interbody fusion, or combined approaches with anterior lumbar interbody fusion and lateral lumbar interbody fusion devices (Table 4). Interbody fusions included personalized interbody devices at L5 to S1 in 42 cases and L4 to S1 in 26 cases. Eleven patients received 1 or more additional nonpersonalized interbody devices.

Radiographic Alignment

Spinopelvic alignment parameters were measured from preoperative and most recent postoperative sagittal radiographs for each patient. Postoperative radiographic measurements were available from follow-up patient visits at 6 weeks (*n* = 11), 6 months (*n* = 30), 12 months (*n* = 24), and 24 months (*n* = 2).

Pre- and postoperative alignment measurements are summarized in Figure 2. Mean preoperative PI-LL decreased significantly from $21.0^\circ \pm 16.2^\circ$ to $7.1^\circ \pm 12.7^\circ$ postoperatively (*P* < 0.001). Similarly, T1PA decreased from $25.0^\circ \pm 10.1^\circ$ to $17.7^\circ \pm 9.0^\circ$ (*P* < 0.001), whereas PT did not change significantly. These trends are reflected in the decreases in mean SRS-Schwab

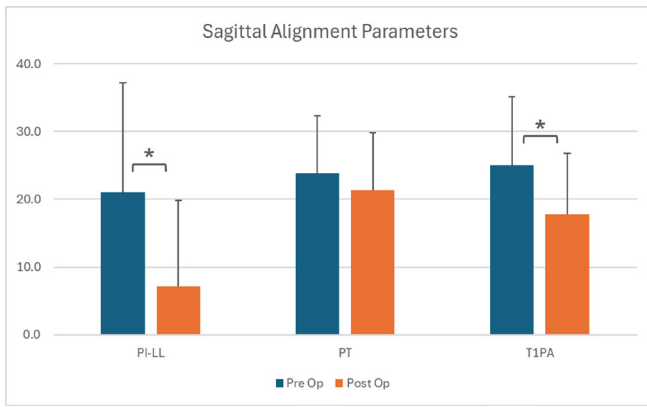


Figure 2. Radiographic sagittal alignment measurements for 67 study patients. Mean postoperative pelvic incidence minus lumbar lordosis (PI-LL) and T1 pelvic angle (T1PA) were significantly reduced compared with preoperative measurements.

modifiers for PI-LL and T1PA, as well as the significant drop in the mean sum of SRS-Schwab modifiers (Figure 3). The sum of SRS-Schwab modifiers correlated strongly to the PI-LL modifier and moderately to PT and T1PA modifiers (Figure 3). Patient distributions of SRS-Schwab component modifiers are summarized in Figure 4. The percentage of patients starting in the severe (++) PI-LL modifier category was reduced from 55% preoperatively to 12% postoperatively. While only 12 preoperative patients (18%) were categorized as mild (0), 34 patients (51%) met this criterion postoperatively. Similarly, preoperative severe T1PA modifier distribution decreased from 72% to 39% of patients, and T1PA mild modifiers increased from 7% to 16%. This is consistent with the distribution of the summed modifier scores that decreased from 66% to 31% of patients with severe (4+ to 6+) and increased from 12% to 37% of patients with mild (0 to 1+) summed scores.

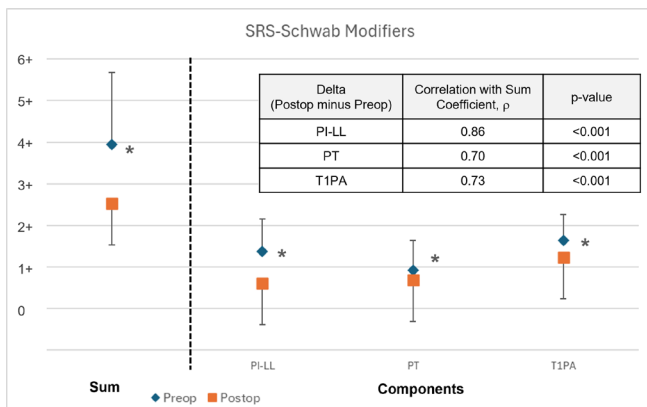


Figure 3. Pre- vs postoperative sum of SRS-Schwab modifiers and component SRS-modifiers (mean \pm SD). The postoperative change (delta) in pelvic incidence minus lumbar lordosis (PI-LL) modifier has the strongest correlation to the change in the sum of modifiers.

Directional changes in patient deformity status are represented in Figure 5, with a change in status represented by a modifier change from one score to another. PI-LL modifiers were improved in 63% of patients and maintained in 30%. PT modifiers were improved in 31% of patients and maintained in 60%. T1PA modifiers were improved in 42% and maintained in 55%. Directional changes to summed modifiers in this study were improved for 52% of patients, maintained for 32%, and worsened for 6%.

Both magnitude and directional changes in patient deformity status are represented in Figure 6. Among 44 patients with preoperative severe sum of modifiers scores, 9 improved to mild, 16 improved to moderate, and 19 maintained severe. Preoperative moderate scores improved to mild for 10 of 15 patients, and preoperative mild scores were maintained in 6 of 8 patients. The sum of modifier scores worsened for 4 of 67 patients in the study cohort.

Eight patients (12%) had preoperative mild/no deformity according to the SRS-Schwab modifier classification, as shown in the lower panel of Figure 4 and the preoperative mild status group in Figure 6. These patients were diagnosed and treated for coronal plane malalignment. Sagittal correction was not a treatment priority for these patients, and the resulting postoperative sum of modifier scores was either maintained ($n = 6$) or slightly worsened to moderate ($n = 2$).

The reduction in mean postoperative PI-LL was primarily due to the 10° increase in mean postoperative LL ($P < 0.05$). Lumbar lordosis is the sum of segmental lordosis angles between L1 and S1. The contribution to LL from levels treated with personalized interbody devices is represented in Figure 7 and compared with the contribution from other levels. The postoperative mean sum of segmental angles increased by 7.9° ($P < 0.05$) for levels treated with personalized devices.

Two patient examples with pre- and postoperative imaging along with personalized interbody device designs are shown in Figures 8 and 9.

Complications

AE reports and complications are listed in Table 5 and include nonserious AEs and complications. Complications occurred for 13 patients (19.4%), including 2 medical and 10 surgical complications ≤ 90 days postoperatively and 1 surgical complication > 90 days postoperatively. Two patients (3%) with surgical complications required reoperation ≤ 90 days postoperatively to address screw malposition or loosening. One mechanical complication with PJK required reoperation

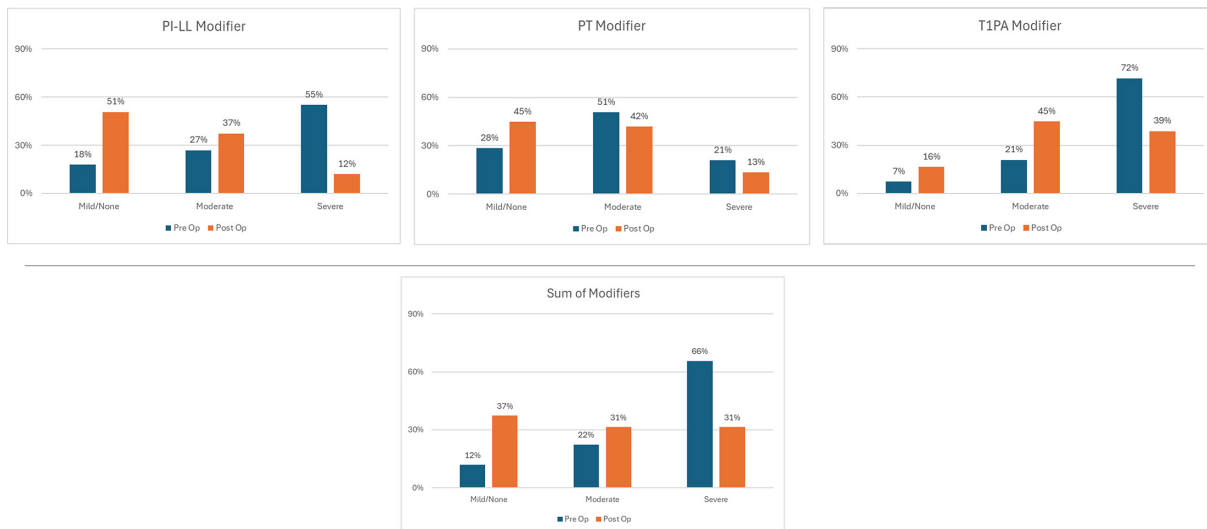


Figure 4. Pre- vs postoperative patient distributions of SRS-Schwab component modifiers and sum of modifiers. Data presented are the percentage of patients.

9 months postoperatively. No complications directly related to the personalized interbody devices were identified.

DISCUSSION

Although surgery for ASD can offer significant clinical improvement, these procedures have high rates of complications and risk of revision surgery. Postoperative persistent or new spinal malalignment is a significant risk factor for revision surgery, and improved techniques are needed to facilitate better postoperative alignment. The primary tools to correct spinal deformity are osteotomies and interbody releases and fusions. Personalized interbody devices offer the potential to specifically control alignment of the disc space, which may result in more predictable achievement of

segmental, regional, and global spinal alignment. The COMPASS registry prospectively follows patients treated with personalized interbody devices to assess their alignment and outcomes. In the present study, we provide an interim assessment of ASD patients enrolled in COMPASS to date. We demonstrate that the alignment achieved with personalized interbody devices compares favorably with previous reports, and no complications in the series were directly attributable to the personalized devices.

PI-LL stands out as the alignment parameter most affected by surgical intervention in this study population as demonstrated by the significant decrease of 13.9° in mean postoperative PI-LL and improved PI-LL modifiers in 63% of patients, resulting in improved summed modifiers in 52% of patients. This outcome is attributable to the increase of 7.9° in mean postoperative lumbar

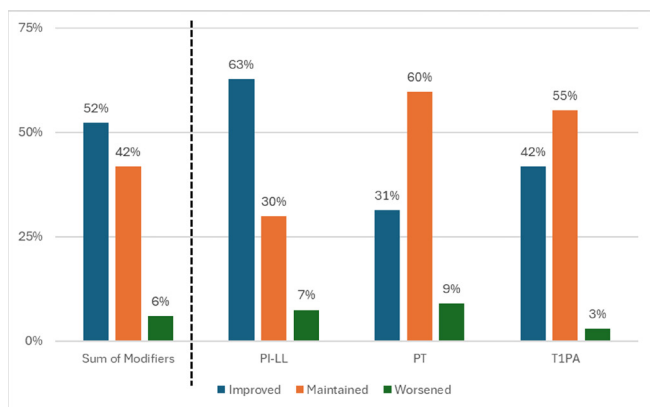


Figure 5. Distribution of patients according to directional postoperative changes in sagittal SRS-Schwab alignment modifier scores for pelvic incidence minus lumbar lordosis (PI-LL), pelvic tilt (PT), and T1 pelvic angle (T1PA). Data presented are the percentage of patients with improved, maintained, or worsened postoperative modifier scores.

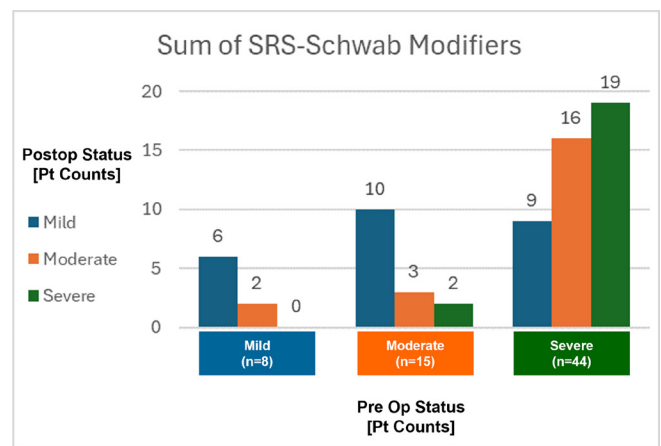


Figure 6. Postoperative changes in magnitude and direction of summed modifiers for 67 study patients.

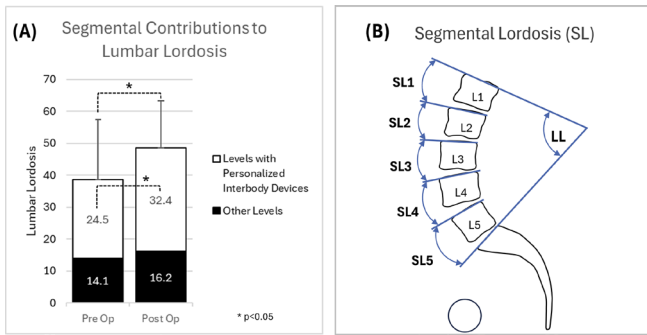


Figure 7. Contribution of segmental corrections to changes in lumbar lordosis for 67 study patients (A). Lumbar lordosis is the sum of segmental lordosis angles between L1 and S1 (B). “Other Levels” include (a) levels with posterior instrumentation and fusion only, (b) levels treated with nonpersonalized interbody devices, and (c) levels not treated.

lordosis, resulting from segmental corrections at levels treated with personalized interbody devices. These results are corroborated by data from Sadrameli et al who describe the achievement of planned corrections to intervertebral lordosis in 82% of lumbar fusion levels treated with personalized interbody devices.²⁴ Anterior column realignment is typically a priority during ASD surgery, and data from this COMPASS series demonstrate that personalized interbody devices may directly and controllably adjust lumbar lordosis.

Among the 67 patients in this study, 26 (38%) improved from preoperative moderate (+) or severe (++) PI–LL modifiers to PI–LL modifier zero. This compares to results by Moal et al who reported that 13% of patients improved from preoperative moderate or severe PI–LL modifiers to modifier zero.² The majority of lumbar lordosis occurs in the distal lumbar spine (L4–S1), and this study included 42 cases (63%) with personalized interbody devices implanted at L4 to L5 or L4 to S1. T1PA also improved postoperatively, although to a lesser extent than PI–LL mismatch. This may be due to the modest changes to PT in study patients, and T1PA is related in part to PT and SVA as a measure of global alignment.

Directional changes to component SRS–Schwab modifiers in the current study are comparable to published results by Passias et al who reported that PI–LL modifiers were improved in 46% of patients and maintained in 47%, PT modifiers were improved in 28% and maintained in 59%, and SVA modifiers were improved in 53% and maintained in 39%.²²

This study included 8 patients (12%) who presented with primary coronal plane malalignment. COMPASS surgeon investigators chose to address deformity in these patients with personalized interbody devices

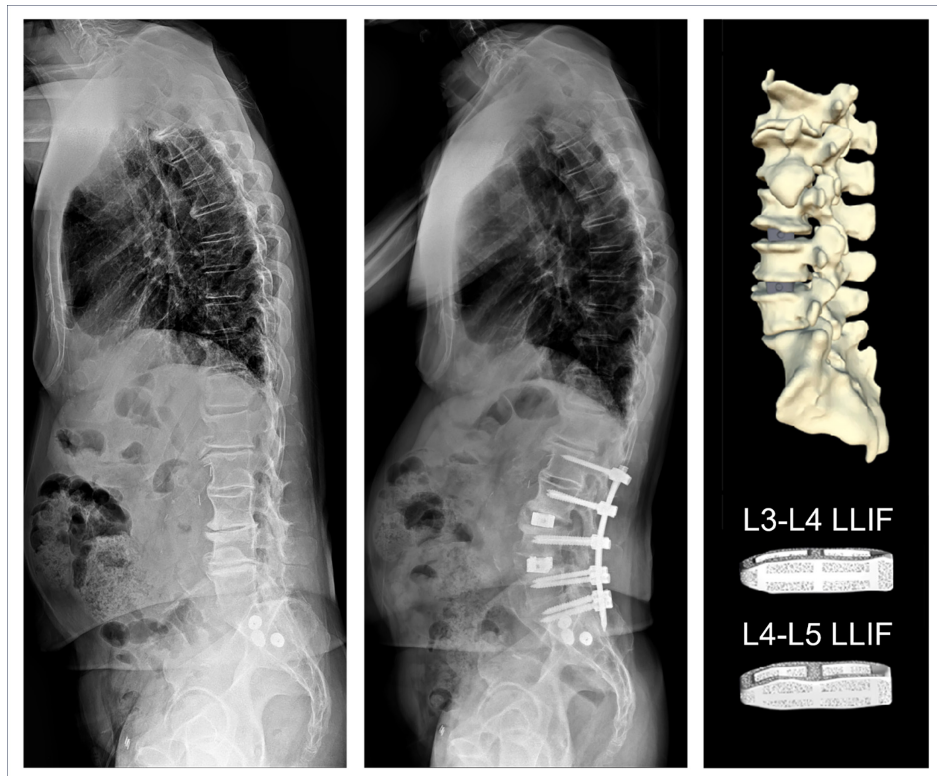


Figure 8. Baseline and 6-month radiographs of a 77-year-old man who underwent L2–S1 posterolateral fusion with lateral lumbar interbody fusion (LLIF) interbody devices at L3–L5.

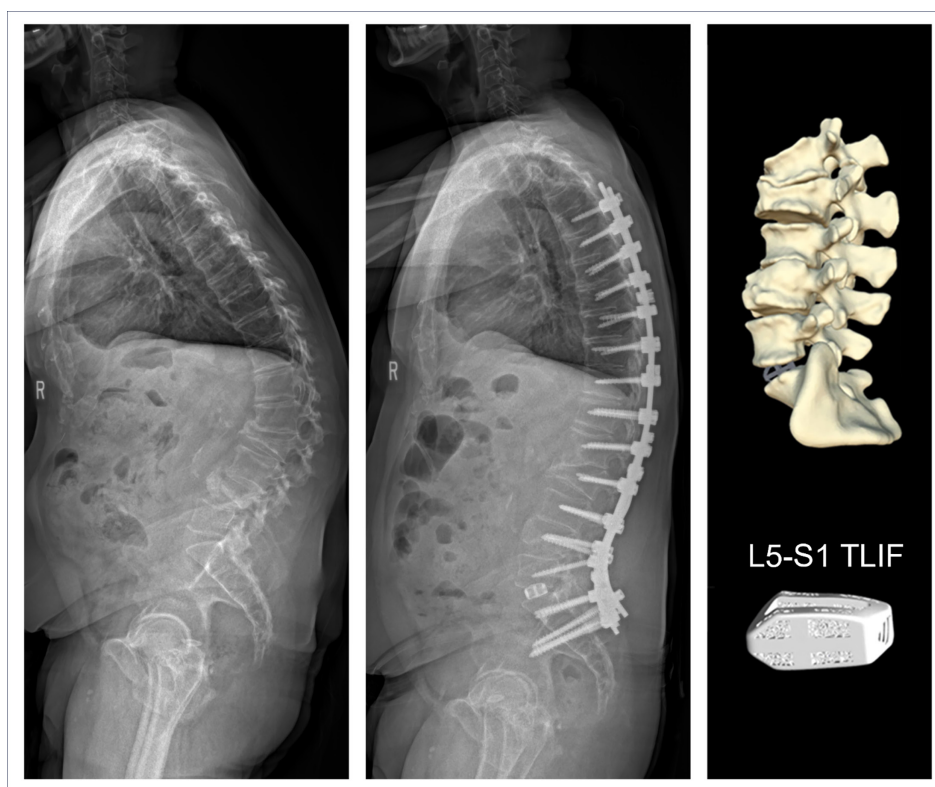


Figure 9. Baseline and 6-month radiographs of a 59-year-old man who underwent L5–S1 transforaminal lumbar interbody fusion (TLIF) and posterolateral fusion from T4 to the pelvis.

designed to match anatomic contours and adjust the orientation of adjacent vertebral endplates in their plans to surgically improve or maintain alignment. A worsened postoperative sum of SRS-Schwab modifiers was observed for 4 subjects (6%), which could be due to the discrete thresholds for SRS-Schwab modifiers such that small changes in continuous angular measurements result in ordinal shifts to a higher modifier state. For comparison, Passias reported between 7% and 12% of patients had worsened postoperative SRS-Schwab component modifiers.²²

Complications in the study include a reoperation rate of 3% during the 90-day postoperative period that can be cautiously compared with the 7% reoperation rate for the 6-week postoperative period recently published for a larger ASD cohort of 1260 patients.²⁰ There were low rates of reoperation in the current study, including 1 revision due to a mechanical complication that occurred 9 months postoperatively. Recent publications report rates of reoperation for mechanical complications between 10% and 32% over postoperative periods

Table 5. AEs and complication SAEs.

Category	≤90 d Postoperatively		>90 d Postoperative	
	Patients, <i>n</i> (%)	No. of Events	Patients, <i>n</i> (%)	No. of Events
Medical AE	6 (9%)	8	3 (4%)	4
Medical complication (SAE)	2 (3%)	2 ^a	0	0
Surgical AE	6 (9%)	9	1 (1.5%)	1 ^b
Surgical complication (SAE)				
Prolonged surgery/recovery	8 (12%)	8 ^c	0	0
Reoperation	2 (3%)	2 ^d	1 (1.5%)	1 ^e

Abbreviations: AE, adverse event; DVT, deep vein thrombosis; PJK, proximal junctional kyphosis; SAE, serious adverse event.

Note: None of reported AEs or complications were related to personalized interbody devices.

^aPostoperative DVT (2).

^bAdjacent segment disease treated nonoperatively, 18 months postoperatively (1).

^cVascular injury (2), dural tear (2), pneumothorax (1), anemia (1), seroma (1), and lymphocele (1).

^dScrew malposition or loosening (2).

^eMechanical complication: adjacent segment disease with PJK (1), reoperation 9 months postoperatively.

of 1 to 2 years.^{17,20,23} Importantly, there were no complications in this study attributable to the personalized interbody devices. These findings are favorable, albeit preliminary, and will be updated in subsequent reports on a larger cohort with longer follow-up.

Although the present study benefits from the prospective multicenter design and the inclusion of both academic and nonacademic surgeon practices, there are limitations. Since this is an interim assessment of an ongoing registry study, the length of postoperative follow-up is limited and varies among participating subjects, although the majority of patients have achieved at least 1-year follow-up. In addition, the number of patients limits the granularity of assessments that can be performed at the present time. The chosen SRS-Schwab classification for this study is appropriate for sagittal alignment assessment but does not assess radiographic outcomes for patients with primarily coronal deformities. Future studies of COMPASS patients should include rigorous analysis of coronal deformity parameters.

CONCLUSION

This study demonstrates that ASD patients whose surgical treatment included personalized interbody devices can obtain postoperative alignment status during the early postoperative period that is at least comparable to published results without complications directly attributable to the personalized interbody devices. As patient enrollment continues to increase and follow-up matures, we anticipate the ability to more definitively assess the potential short- and long-term benefits of personalized interbody devices.

REFERENCES

1. Teles AR, Mattei TA, Righesso O, Falavigna A. Effectiveness of operative and nonoperative care for adult spinal deformity: systematic review of the literature. *Global Spine J.* 2017;7(2):170–178. doi:10.1177/2192568217699182
2. Moal B, Schwab F, Ames CP, et al. Radiographic outcomes of adult spinal deformity correction: a critical analysis of variability and failures across deformity patterns. *Spine Deform.* 2014;2(3):219–225. doi:10.1016/j.jspd.2014.01.003
3. Cerpa M, Lenke LG, Fehlings MG, Shaffrey CI, Cheung KMC, Carreon LY. Evolution and advancement of adult spinal deformity research and clinical care: an overview of the scoliosis-RISK-1 study. *Global Spine J.* 2019;9(1 Suppl):8S–14S. doi:10.1177/2192568219828729
4. Glassman SD, Dimar JR, Carreon LY. Revision rate after adult deformity surgery. *Spine Deform.* 2015;3(2):199–203. doi:10.1016/j.jspd.2014.08.005
5. Glassman SD, Carreon LY, Shaffrey CI, et al. Cost-effectiveness of adult lumbar scoliosis surgery: an as-treated analysis from the adult symptomatic scoliosis surgery trial with 5-year follow-up. *Spine Deform.* 2020;8(6):1333–1339. doi:10.1007/s43390-020-00154-w
6. Hellsten EK, Hanbidge MA, Manos AN, et al. An economic evaluation of perioperative adverse events associated with spinal surgery. *Spine J.* 2013;13(1):44–53. doi:10.1016/j.spinee.2013.01.003
7. Rothenfluh DA, Mueller DA, Rothenfluh E, Min K. Pelvic incidence-lumbar lordosis mismatch predisposes to adjacent segment disease after lumbar spinal fusion. *Eur Spine J.* 2015;24(6):1251–1258. doi:10.1007/s00586-014-3454-0
8. Jager ZS, İnceoğlu S, Palmer D, Akpolat YT, Cheng WK. Preventing instrumentation failure in three-column spinal osteotomy: biomechanical analysis of rod configuration. *Spine Deform.* 2016;4(1):3–9. doi:10.1016/j.jspd.2015.06.005
9. Tempel ZJ, Gandhoke GS, Bolinger BD, et al. The influence of pelvic incidence and lumbar lordosis mismatch on development of symptomatic adjacent level disease following single-level transforaminal lumbar interbody fusion. *Neurosurgery.* 2017;80(6):880–886. doi:10.1093/neuros/nyw073
10. Phan K, Nazareth A, Hussain AK, et al. Relationship between sagittal balance and adjacent segment disease in surgical treatment of degenerative lumbar spine disease: meta-analysis and implications for choice of fusion technique. *Eur Spine J.* 2018;27(8):1981–1991. doi:10.1007/s00586-018-5629-6
11. Buell TJ, Buchholz AK, Quinn JC, et al. Adjacent segment disease and proximal junctional kyphosis—part 1: etiology and classification. *Contemp Neurosurg.* 2018;40(17):1–7. doi:10.1097/01.CNE.0000549709.01850.03
12. Schwab F, Ungar B, Blondel B, et al. Scoliosis research society—schwab adult spinal deformity classification. *Spine.* 2012;37(12):1077–1082. doi:10.1097/BRS.0b013e31823e15e2
13. Terran J, Schwab F, Shaffrey CI, et al. The SRS-schwab adult spinal deformity classification: assessment and clinical correlations based on a prospective operative and nonoperative cohort. *Neurosurgery.* 2013;73(4):559–568. doi:10.1227/NEU.0000000000000012
14. Protosaltis T, Schwab F, Bronsard N, et al. The T1 pelvic angle, a novel radiographic measure of global sagittal deformity, accounts for both spinal inclination and pelvic tilt and correlates with health-related quality of life. *J Bone Joint Surg Am.* 2014;96(19):1631–1640. doi:10.2106/JBJS.M.01459
15. Champain S, Benchikh K, Nogier A, Mazel C, Guise JD, Skalli W. Validation of new clinical quantitative analysis software applicable in spine orthopaedic studies. *Eur Spine J.* 2006;15(6):982–991. doi:10.1007/s00586-005-0927-1
16. Kyrölä K, Repo J, Mecklin JP, Ylinen J, Kautiainen H, Häkkinen A. Spinopelvic changes based on the simplified SRS-schwab adult spinal deformity classification: relationships with disability and health-related quality of life in adult patients with prolonged degenerative spinal disorders. *Spine.* 1976;43(7):497–502. doi:10.1097/BRS.00000000000002370
17. Jacobs E, van Royen BJ, van Kuijk SMJ, et al. Prediction of mechanical complications in adult spinal deformity surgery—the GAP score versus the schwab classification. *Spine J.* 2019;19(5):781–788. doi:10.1016/j.spinee.2018.11.013
18. National Institute of Arthritis and Musculoskeletal and Skin Diseases. Template and guidelines for developing a multi-site manual of operations and procedures (MOOP). 2017. https://www.niams.nih.gov/sites/default/files/multisite_moop.pdf.
19. Smith JS, Shaffrey CI, Kelly MP, et al. Effect of serious adverse events on health-related quality of life measures

following surgery for adult symptomatic lumbar scoliosis. *Spine*. 2019;44(17):1211–1219. doi:10.1097/BRS.0000000000003036

20. Lafage R, Bass RD, Klineberg E, et al. Complication rates following adult spinal deformity surgery: evaluation of the category of complication and chronology. *Spine*. 2024;49(12):829–839.

21. Klineberg EO, Wick JB, Lafage R, et al. Development and validation of a multidomain surgical complication classification system for adult spinal deformity. *Spine*. 2021;46(4):E267–E273. doi:10.1097/BRS.00000000000003766

22. Passias PG, Bortz C, Pierce KE, et al. Comparing and contrasting the clinical utility of sagittal spine alignment classification frameworks. *Spine*. 2022;47(6):455–462. doi:10.1097/BRS.00000000000004300

23. Teles AR, Aldebeyan S, Aoude A, et al. Mechanical complications in adult spinal deformity surgery: can spinal alignment explain everything? *Spine*. 1976;47(1):E1–E9. doi:10.1097/BRS.00000000000004217

24. Sadrameli SS, Blaskiewicz DJ, Asghar J, et al. Predictability in achieving target intervertebral lordosis using personalized interbody implants. *Int J Spine Surg*. 2024;18(S1):S16–S23. doi:10.14444/8637

Funding: This work was supported by funding from Carlsmed.

Declaration of Conflicting Interests:

Roland S. Kent discloses that he is a clinical research investigator and receives consulting fees from Carlsmed. Christopher P. Ames discloses that he is a clinical research investigator and receives consulting fees from Carlsmed. Jahangir Asghar discloses that he is a clinical research investigator and receives consulting fees from Carlsmed. Donald J. Blaskiewicz discloses that he is a clinical research investigator and receives consulting fees from Carlsmed. Joseph A. Osorio discloses that he is a clinical research investigator and receives consulting fees from Carlsmed. Chun-Po Yen discloses that he is a clinical research investigator and receives consulting fees from Carlsmed. Jeffrey P. Mullin discloses that he is a clinical research investigator and receives consulting fees from Carlsmed. Justin S. Smith discloses that he is a shareholder and receives consulting fees from Carlsmed. John M. Small discloses that he is a clinical research investigator for Carlsmed. Michele Temple-Wong discloses that she is an employee of Carlsmed. Jeffrey D. Schwardt discloses that he is an employee of Carlsmed.

Disclosures: In addition to the relationships listed in the Declaration of Conflicting Interests, Christopher Ames reports grants/contracts from SRS; royalties/

licenses from DePuy Synthes, K2M, Next Orthosurgical, Stryker, Biomet Zimmer Spine, Medicea, and NuVasive; consulting fees from DePuy Synthes, Medicea, Agada Medical, Medtronic, and K2M; is the chair of the SRS Safety and Value Committee and serves on the executive committee of ISSG; serves on the editorial board for *Operative Neurosurgery* and *Neurospine*; is the director of Global Spinal Analytics, and has research interests with Titan Spine, ISSG, and DePuy Synthes. Roland Kent reports consulting fees from SI Bone and Globus Medical; payment/honoraria from SI Bone, Globus Medical, and Premia Spine; and patents pending for SI Bone. Jeffrey Mullin reports consulting fees from Medtronic, Globus, and SI Bone, and serves on the CNS and AANS/CNS Joint Spine Section Executive Committees. Joseph Osorio reports grants/contracts from Medtronic; royalties/licenses from Alphatec; and consulting fees from Alphatec, Medtronic, and DePuy. John Small reports royalties/licenses from Astura Spine. Justin Smith reports grants/contracts from SeaSpine/Orthofix, NREF, AO Spine, and DePuy Synthes/ISSGF; royalties/licenses from Highridge and Globus/NuVasive; consulting fees from Highridge, SeaSpine/Orthofix, Medtronic, Cerapedics, and Globus/NuVasive; support for attending meetings/travel from AO Spine; serving on the SRS Board of Directors and ISSGF Executive Committee; and stock/stock options from Alphatec and Globus/NuVasive. Chun-Po Yen reports consulting fees from Life Spine and Medtronic and support for teaching a cadaveric course from Life Spine.

Ethics Statement: Institutional Review Board approval was obtained prior to patient enrollment. All patients provided informed consent.

Corresponding Author: Roland S. Kent, Axis Spine Center, 7600 N Mineral Dr, Suite 700, Coeur d'Alene, ID 83815, USA; r.kent@axisspinecenter.com

Published 23 August 2024

This manuscript is generously published free of charge by ISASS, the International Society for the Advancement of Spine Surgery. Copyright © 2024 ISASS. To see more or order reprints or permissions, see <http://ijssurgery.com>.