

## Prospective Evaluation of the Time Required for Insertion of 380 Lumbar and Sacral Pedicle Screws Using Navigation with an Intraoperative 3-Dimensional Imaging System

Benjamin Tze Keong Ding, Arun-Kumar Kaliya-Perumal, Jacob Yoong-Leong Oh and Chun-Sing Yu

*Int J Spine Surg* published online 12 June 2020  
<https://www.ijssurgery.com/content/early/2020/06/10/7048>

This information is current as of December 26, 2024.

---

**Email Alerts** Receive free email-alerts when new articles cite this article. Sign up at:  
<http://ijssurgery.com/alerts>

# Prospective Evaluation of the Time Required for Insertion of 380 Lumbar and Sacral Pedicle Screws Using Navigation with an Intraoperative 3-Dimensional Imaging System

BENJAMIN TZE KEONG DING, MBBS (S'PORE), MRCS (EDIN), ARUN-KUMAR KALIYA-PERUMAL, MBBS, MS, JACOB YOONG-LEONG OH, MBChB (NZ), MMED (ORTHO), FRCS TR & ORTH (EDIN), CHUN-SING YU, MBBS (S'PORE), FRCS (EDIN)

*Department of Orthopaedic Surgery, Tan Tock Seng Hospital, Singapore*

## ABSTRACT

**Background:** The aim of this study was to evaluate the time required for various parts of the procedure to insert lumbar and sacral pedicle screws using navigation with an intraoperative, 3-dimensional imaging system. Comparison of these timings was carried out for different surgical indications.

**Methods:** This was a single-surgeon prospective cohort study of 69 consecutive patients (between August 2013 and June 2018) who underwent insertion of 380 pedicle screws into the lumbar and sacral vertebrae. Surgical indications, average time required for surgical exposure and attachment of the reference frame, average time required until completion of the first pedicle screw insertion, and average time required for insertion of a single pedicle screw were evaluated.

**Results:** The average time required from skin incision to reference frame attachment was  $28.3 \pm 20.4$  (mean  $\pm$  SD) minutes, and the average time required from reference frame attachment to completion of first pedicle screw insertion was  $22.3 \pm 9.6$  minutes. The average time required for insertion of a single pedicle screw was  $7.8 \pm 2.7$  minutes. When surgical indications were compared, the average time required for insertion of a single pedicle screw was  $7.7 \pm 2.6$  minutes in surgery for spondylosis-related stenosis,  $8.1 \pm 2.8$  minutes for degenerative scoliosis, and  $8.2 \pm 3.6$  minutes for metastatic tumor ( $P = .89$ ). There were no significant changes in these timings over consecutive 6-month periods.

**Conclusions:** There is no significant learning curve and no significant difference in navigation setup and pedicle screw insertion timings with intraoperative 3-dimensional navigation systems for surgeries of different pathologies and levels of surgery.

**Level of Evidence:** Level 2.

New Technology

Keywords: navigation, O-arm, 3-dimensional fluoroscopy, lumbar spine, lumbar pedicle screw, degenerative scoliosis, lumbar spondylosis

## INTRODUCTION

Spinal instrumentation using pedicle screws has become the standard of care in the treatment of many spinal conditions because it offers an instrumentation construct with high biomechanical strength for the support of the spinal column.<sup>1–4</sup> Conventional methods of spinal instrumentation, however, are prone to misplacement due to the considerable variability in the human anatomy, spinal deformities arising from various diseases, and variability in the surgeon's experience because the screws are usually inserted "blind."<sup>4–6</sup> Computer-assisted navigation using preoperative 3-dimensional (3D) computed tomography has been used

for guiding pedicle screw insertions but has been demonstrated to be prone to navigation errors and prolonged surgical time due to changes in intervertebral anatomical relationships when the patient is prone, resulting in the need for point or surface registration of each vertebra.<sup>7,8</sup>

Intraoperative 3D image-based navigation avoids changes in anatomical relationships due to patient positioning and can potentially provide greater accuracy, improved safety, and reduced surgical time for pedicle screw insertion.<sup>1,2,9–12</sup> The O-arm (Medtronic, Minneapolis, MN) is an intraoperative imaging system that provides high-definition 3D image reconstructions that can be

automatically uploaded to the S7 Stealth Station (Medtronic, Minneapolis, MN) navigation system.

Spinal tumor surgery and deformity correction surgery have been shown to be associated with increased surgical times, higher rates of complications, greater blood loss, and longer inpatient stays.<sup>13,14</sup>

Our study aims to prospectively evaluate the time required for various parts of the procedure to insert lumbar and sacral pedicle screws using navigation with the O-arm and Stealth Station. The study also compares these timings for different surgical indications and increasing number of instrumentation levels. Changes in these timings over consecutive 6-month periods were also evaluated to provide insight into the learning curve.

## MATERIALS AND METHODS

This was a prospective longitudinal cohort study. Patients were enrolled if they were admitted to our institution for primary spine surgery by a single surgeon involving up to a maximum of 3 levels in the lumbar or lumbosacral spine between July 2013 and June 2018. Patient demographics, diagnoses, and outcomes were recorded from patient interviews, physical examinations, and imaging studies.

Surgeries were performed for the following indications: spinal stenosis related to lumbar spondylosis in 56 patients, degenerative scoliosis in 10 patients, and metastatic vertebral tumors in 3 patients. Two of the patients in the lumbar spondylosis group had concomitant osteoporotic vertebral body fractures, but the cause of spinal stenosis was spondylosis. Extension of instrumentation to the sacral vertebrae was performed in 21 patients. Preoperative planning of screw length, size, direction, and prediction of entry point was not performed prior to surgery with preoperative computed tomography (CT) or magnetic resonance imaging scans.

Patients were induced under general anesthesia and placed prone on a Jackson table. A posterior midline or paramedian approach was used. After obtaining adequate exposure, the navigation reference frame was attached rigidly to the spinous process just above the level where the most cranial pedicle screw insertion was planned. The patient's breathing was suspended temporarily by the anesthesiologist, and image acquisition was performed with the O-arm. After image transfer to the Stealth Station, navigable instruments such as the awl, bone

tap, and pedicle screwdriver were registered to the Stealth Station by pointing them to a designated point on the reference frame. A pedicle screw track was then created by advancing the navigated awl into the vertebra with the use of a mallet. The dimensions of the pedicle and vertebral body were measured with the Stealth Station software to determine the optimum diameter and length for the pedicle screw. The screw track was tapped if required and the appropriate screw inserted with the use of the respective navigable instruments. After inserting a desired number of pedicle screws, 2-dimensional and/or 3D images were obtained with the O-arm to detect any malpositioned screws, which were then revised accordingly. Decompression and spinal fusion were then performed as necessary.

The times at 4 points of each surgery were recorded by a clinical assistant who was trained to measure the timings at different reference points and was not involved in the surgery. Data on time of skin incision, time of reference frame attachment, time at completion of first pedicle screw insertion, and time at completion of last pedicle screw insertion were recorded. From the data collected, the following time periods were calculated: (1) time required from skin incision to reference frame attachment; (2) time required from reference frame attachment to completion of first pedicle screw insertion; and (3) average time required for insertion of a single pedicle screw (this was derived from total time taken for inserting all the pedicle screws divided by the total number of screws inserted—any time taken to revise malpositioned screws was also included in the total time taken).

We compared the above durations with the following variables: (1) surgical indication (spondylosis-related stenosis, degenerative scoliosis, metastatic tumor); (2) number of levels of pedicle screw instrumentation; and (3) consecutive 6-month periods based on the date of surgery. For cases where the O-arm was unavailable, a C-arm was used without a computerized navigation system.

## STATISTICAL METHODS

All statistical analyses were done using Graph Pad Prism 5 (GraphPad Software Inc, San Diego, CA). The Pearson correlation coefficient,  $r$ , was used to look for correlation between continuous variables. An  $r$  value between .7 and 1.0 indicates variables that are highly correlated; between .5 and

.7 indicates moderate correlation; and between .3 and .5 indicates variables with low correlation. One-way analysis of variance (ANOVA) was used to analyze the significance of differences between groups. A probability value of less than .05 was considered statistically significant.

## RESULTS

A total of 74 patients underwent primary instrumented lumbar or lumbosacral spine surgery during the period between July 2013 and June 2018. C-arm without navigation was used for 5 patients due to unavailability of the O-arm or Stealth navigation system. The 69 patients who underwent O-arm imaging with the Stealth System–navigated pedicle screw insertion included 27 men and 42 women with a mean age of  $63.1 \pm 12.4$  years at the time of surgery. 56 surgeries were performed for spondylosis related stenosis, 10 for degenerative scoliosis and 3 for metastatic tumour. There were 21 single-level, 32 two-level, and 16 three-level spinal instrumentation surgeries performed. All surgeries were primary operations for their respective pathologies and patient demographics, surgical indications and levels of surgery are shown in Table 1.

For O-arm cases, the average time required from skin incision to reference frame attachment was  $28.3 \pm 20.4$  (mean  $\pm$  SD) minutes. The average time required from reference frame attachment to completion of insertion of the first pedicle screw was  $22.3 \pm 9.6$  minutes. The average time required for inserting a single pedicle screw was  $7.8 \pm 2.7$  minutes. For C-arm cases, the average time required for inserting a single pedicle screw was  $16.3 \pm 10.0$  minutes ( $P = .001$ ).

There was no significant difference in age or gender between groups when categorized on the basis of pathology and number of levels of surgery performed. There was no significant correlation between age and the average time required from skin incision to reference frame attachment,  $r = .05$ ; from reference frame attachment to insertion of a single pedicle screw,  $r = -.11$ ; and average time required for insertion of a single pedicle screw,  $r = -.04$ . When evaluating for the effect of gender on surgical timings, the average time required from skin incision to reference frame attachment was  $32.3 \pm 29.6$  minutes for men and  $25.8 \pm 11.3$  minutes for women ( $P = .20$ ). The average time required from reference frame attachment to completion of first pedicle screw insertion was  $20.8 \pm 8.5$  minutes for

**Table 1.** Patient demographics, surgical indications, number of levels of pedicle screw instrumentation, and average time required for various parts of the surgical procedure.

	O-Arm Group
No. of patients	69
Age, y	$63.1 \pm 12.4$
Males / females, n	27 / 42
Surgical indications, n	
Spondylosis-related stenosis	56
Degenerative scoliosis	10
Metastatic tumor	3
Pedicle screw instrumentation at each level, n	
Single level	21
2 levels	32
3 levels	16
Average time required from skin incision to reference frame attachment (min)	$28.3 \pm 20.4$
Average time required from reference frame attachment to completion of first pedicle screw insertion (min)	$22.3 \pm 9.6$
Average time required for insertion of single pedicle screw (min)	$7.8 \pm 2.7$

men and  $23.2 \pm 10.4$  minutes for women ( $P = .32$ ). The average time required for inserting a single pedicle screw was  $8.9 \pm 3.0$  minutes for men and  $7.1 \pm 2.2$  minutes for women ( $P = .005$ ).

When comparing different surgical indications, the average time required from skin incision to reference frame attachment was  $28.9 \pm 22.0$  minutes for spondylosis-related stenosis,  $28.9 \pm 11.4$  minutes for degenerative scoliosis, and  $15.3 \pm 13.5$  minutes for metastatic tumor ( $P = .54$ ). The average time required from reference frame attachment to completion of first pedicle screw insertion was  $23.0 \pm 10.1$  minutes for spondylosis-related stenosis,  $18.7 \pm 8.0$  minutes for degenerative scoliosis, and  $21.0 \pm 5.0$  minutes for metastatic tumor ( $P = .43$ ). The average time required for inserting a single pedicle screw was  $7.7 \pm 2.6$  minutes for spondylosis-related stenosis,  $8.1 \pm 2.8$  minutes for degenerative scoliosis, and  $8.2 \pm 3.6$  minutes for metastatic tumor ( $P = .89$ ). The average time required for various parts of the surgical procedure when performed for different surgical indications are shown in Table 2.

When comparing number of levels of pedicle screw instrumentation, the average time required from skin incision to reference frame attachment was  $23.4 \pm 8.2$  minutes for single-level instrumentation,  $28.3 \pm 28.0$  minutes for 2-level instrumentation and  $34.9 \pm 11.3$  minutes for 3-level instrumentation ( $P = .25$ ). The average time required from reference frame attachment to completion of first pedicle screw insertion was  $20.3 \pm 9.3$  minutes for single-level instrumentation,  $24.4 \pm$

**Table 2.** Average time required for various parts of the surgical procedure when performed for different surgical indications.

	Spondylosis-Related Stenosis	Degenerative Scoliosis	Tumor	P Value
Average time required from skin incision to reference frame attachment, min	28.9 ± 22.0	28.9 ± 11.3	15.3 ± 13.5	.54
Average time required from reference frame attachment to completion of first pedicle screw insertion, min	23.0 ± 10.1	18.7 ± 8.0	21.0 ± 5.0	.43
Average time required for insertion of single pedicle screw, min	7.7 ± 2.6	8.1 ± 2.8	8.2 ± 3.6	.89

10.9 minutes for 2-level instrumentation, and 20.7 ± 6.8 minutes for 3-level instrumentation ( $P = .24$ ). The average time required for inserting a single pedicle screw was 8.4 ± 3.2 minutes for single-level instrumentation, 7.5 ± 2.8 minutes for 2-level instrumentation, and 7.4 ± 2.1 minutes for 3-level instrumentation ( $P = .46$ ). The average time required for various parts of the surgical procedure when performed for the increasing number of levels of pedicle screw instrumentation are shown in Table 3. There was no significant difference in pedicle screw insertion timings when patients who required sacral pedicle screw insertions were compared against patients who only required lumbar pedicle screw insertions. The time taken for pedicle screw insertion was 8.02 ± 2.21 minutes for patients requiring sacral pedicle screw insertions and 7.68 ± 2.84 minutes for those who required only lumbar pedicle screw insertions ( $P = .62$ ).

The patients were divided into 9 groups of consecutive 6-month periods based on their date of surgery. For 1-way ANOVA to be performed, each group required at least 2 readings. There were no significant differences among the 9 groups of patients in average time required from skin incision to reference frame attachment ( $P = .76$ ), average time required from reference frame attachment to completion of first pedicle screw insertion ( $P = .31$ ), and average time required for inserting a single pedicle screw ( $P = .41$ ). A scatterplot of average time required for insertion of a single pedicle screw over consecutive 6-month periods is shown in Table 4.

Twelve patients required intraoperative re-siting of screws due to unsatisfactory placement. There was no statistically significant correlation between patients requiring re-siting of screws and pathology

( $P = .37$ ) or number of levels of surgery performed ( $P = .63$ ). Re-siting of screws significantly increased pedicle screw insertion time, 11.9 ± 1.86 minutes when compared against patients who did not require pedicle screw re-siting, 6.91 ± 1.84 minutes ( $P < .001$ ). None of the patients who required re-siting of screws developed neurological deficits or complications from screw misplacement after surgery.

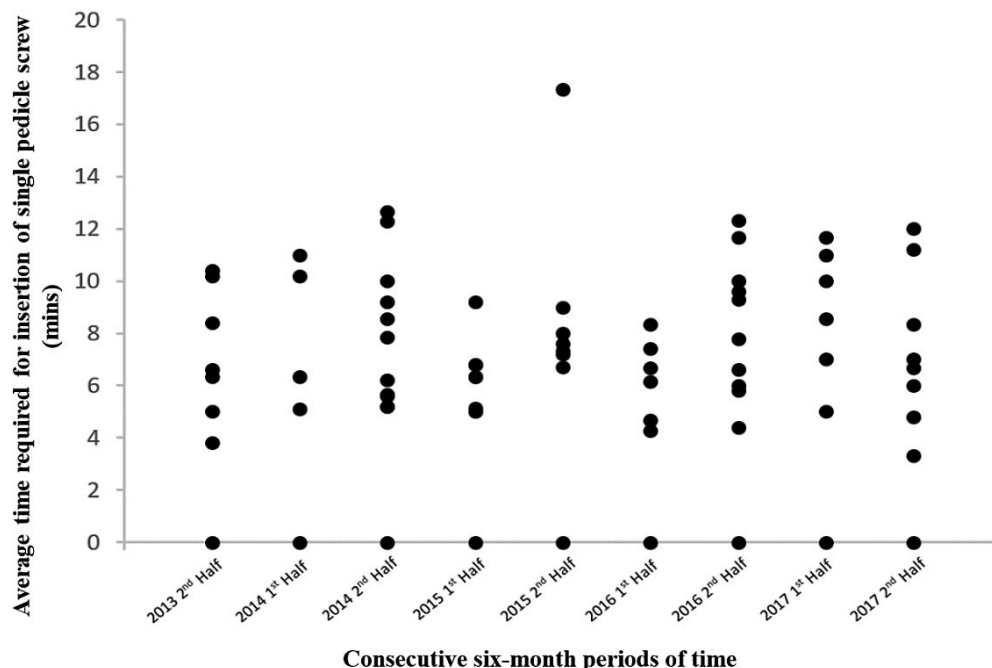
There were 9 complications from surgery in this cohort of patients; however, none of them were due to screw misplacement or early loosening. Three patients had dural tears requiring intraoperative repair, and 1 patient had surgical site infection requiring debridement and an extended course of antibiotics. One patient developed deep vein thrombosis and required a course of anticoagulation until resolution. Two patients had cage displacement without loss of alignment or pedicle screw and rod loosening. Both patients underwent revision of the cage with a larger-sized cage without any further complications. Two of the patients developed adjacent segment disease requiring secondary surgery for decompression and extension of instrumentation and fusion.

## DISCUSSION

Technological advances in spine surgery have increased the interest in intraoperative, O-arm-based navigation systems to improve the accuracy, radiation safety, and efficiency of pedicle screw placement. Multiple studies and meta-analyses have reported the superior accuracy and outcomes of intraoperative 3D imaging-based navigation when compared against fluoroscopy, C-arm-based navigation, and preoperative CT-based navigation for

**Table 3.** Average time required for various parts of the surgical procedure when performed for increasing number of levels of pedicle screw instrumentation.

	Single Level	2 Levels	3 Levels	P Value
Average time required from skin incision to reference frame attachment, min	23.4 ± 8.2	28.3 ± 28.0	34.9 ± 11.3	.24
Average time required from reference frame attachment to completion of first pedicle screw insertion, min	20.3 ± 9.3	24.4 ± 10.9	20.7 ± 6.8	.24
Average time required for insertion of single pedicle screw, min	8.4 ± 3.2	7.5 ± 2.8	7.4 ± 2.1	.46

**Table 4.** Average time required for insertion of single pedicle screw over consecutive 6-month periods.

the insertion of pedicle screws.<sup>1,11,15–20</sup> However, few studies have prospectively analyzed the durations of the various parts of the procedure when using an intraoperative 3D imaging–based navigation system.

Khanna et al<sup>21</sup> evaluated whether setup time or procedural time was increased with the use of O-arm–based navigation versus freehand techniques in a retrospective series of 136 consecutive single-level lumbar fusion surgeries. They found no significant difference in the setup times of the techniques, but procedure time was significantly shorter in navigated cases (3 hours 39 minutes vs 4 hours 4 minutes;  $P = .0003$ ). Their study, however, did not give details of the time taken for procedural steps such as from skin incision to reference frame attachment and from reference frame attachment to completion of insertion of the first pedicle screw.

In our series, the average time required from skin incision to reference frame attachment was  $28.3 \pm 20.4$  minutes. The average time required from reference frame attachment to completion of insertion of the first pedicle screw was  $22.3 \pm 9.6$  minutes. The average time required for inserting a single pedicle screw was  $7.8 \pm 2.7$  minutes. The time required from skin incision to reference frame attachment was mainly to perform the surgical

exposure. The time required from reference frame attachment to completion of insertion of the first pedicle screw was for positioning of the O-arm, image acquisition, data transfer to the Stealth Station, preparation of the pedicle screw track, and insertion of the pedicle screw.

Shin et al<sup>20</sup> reported an initial preparation time of 30 minutes for setting up of the O-arm and navigation system, which eventually decreased to an average of 19 minutes as compared with a setup time of 4 minutes in the fluoroscopy-guided C-arm group. In our practice, the setting up of the O-arm and navigation system occurs while the patient is being positioned for surgery. Hence, we did not separately record the setup time prior to skin incision.

Zhang et al<sup>17</sup> reported an average time of 10.2 minutes from anatomical registration to complete insertion of 1 pedicle screw using preoperative CT-guided navigation. For a single-level construct, the process would have to be repeated 4 times, resulting in an overall timing of 40 minutes for insertion of 4 pedicle screws, without including the time taken for exposure and image acquisition.

In a cadaveric study, Tabaraee et al<sup>11</sup> reported 4.8 minutes for placement of pedicle screws using O-arm imaging-based navigation. Zhang et al<sup>17</sup>

reported a pedicle screw insertion time of  $5.6 \pm 1.3$  minutes, whereas Kotani et al<sup>1</sup> reported  $5.4 \pm 1.1$  minutes in patients undergoing scoliosis surgery. Shin and colleagues reported a pedicle screw insertion time of 4.5 minutes<sup>20</sup> in the initial retrospective series in 2012 and 4.3 minutes<sup>19</sup> in the subsequent prospective randomized cohort study between O-arm and fluoroscopy guided navigation in 2015. Liu et al<sup>22</sup> reported an average time of  $5.3 \pm 2.8$  minutes in the O-arm group and  $6.6 \pm 3.6$  minutes in the C-arm group for pedicle screw insertion in patients with thoracic vertebral fractures. For pedicle screw insertion using preoperative CT-based navigation systems, Laine et al<sup>5</sup> reported a mean insertion time of 7.5 minutes, Meng et al<sup>18</sup> reported an average insertion time of  $6.3 \pm 1.6$  minutes, Rajasekaran et al<sup>23</sup> and Han et al<sup>24</sup> reported an average insertion time of  $4.6 \pm 1.0$  minutes, whereas Kapoor et al<sup>25</sup> reported an average time of 12.0 minutes.

Our study found no significant difference in the average time required for various parts of the procedure to insert pedicle screws in patients with spinal stenosis, degenerative scoliosis, or metastatic tumor. Pedicle screw insertion timings appeared to be significantly increased for men than for women. Jin et al<sup>26</sup> reported an increased difficulty in placing pedicle screws and a greater risk of screw malposition at the L5 segment due to the effect of erector spinae and soft tissue extrusion by the iliac wing toward the rear of the pelvis, which appeared to be more significant in men. Given that only 1 female patient required surgery without L5 involvement, we hypothesize that the difference in pedicle screw insertion timings may be secondary to this effect as surgical exposure timings and time from reference frame attachment to insertion of the first pedicle screw was not affected by gender differences. We acknowledge that the number of patients in our series is relatively small, but the findings suggest that the average time required does not significantly change with different surgical pathologies.

Khanna et al<sup>21</sup> observed a time-dependent decrease in operative time with the use of O-arm navigation over 4 years, which they implied may be due to an initial learning curve. The study, however, did not take into account the different parts of the surgical procedure. By analyzing the various parts of the surgical procedure, we found no significant difference when the surgeries were categorized into groups spanning 6 months of at least 4 surgeries.

The reasons may be related to plateauing of the learning curve and the frequency (every 2 to 4 months) of change in surgical trainees assigned to the operating theater.

Our study does have limitations. The study protocol excluded patients with surgeries on greater than 3 segments because that would have required repositioning the machine and a repeat scan for the additional levels. There were fewer patients undergoing surgery for metastatic tumor and degenerative scoliosis than for degenerative spinal stenosis. Data on curve measurements and spinopelvic parameters to determine the severity of scoliosis were not collected. There were also no patients who underwent surgery for vertebral fracture. This is because our study protocol excluded patients whose instrumentation included the thoracic spine, and most lumbar fractures tend to be at the thoracolumbar junction. The lack of learning curve may have been linked to the experience of the single surgeon, and therefore it may not be possible to extrapolate the results to junior surgeons embarking on the technique.

Although our results may not be generalizable to all surgical teams performing spinal navigation surgery due to the differences in experience and training, the study aims to provide a reference timing for surgical teams to aim toward when using navigation.

## CONCLUSION

This prospective study provides an indication of the time required for various parts of the procedure to insert lumbar and sacral pedicle screws using navigation with an intraoperative, 3D imaging system. It adds to the growing pool of knowledge about this type of surgery.

## REFERENCES

1. Kotani T, Akazawa T, Sakuma T, et al. Accuracy of pedicle screw placement in scoliosis surgery: a comparison between conventional computed tomography-based and O-arm-based navigation techniques. *Asian Spine J.* 2014;8(3):331–338.
2. Mason A, Paulsen R, Babuska JM, et al. The accuracy of pedicle screw placement using intraoperative image guidance systems. *J Neurosurg Spine.* 2014;20(2):196–203.
3. Vaccaro AR, Garfin SR. Internal fixation (pedicle screw fixation) for fusions of the lumbar spine. *Spine.* 1995;20(suppl 24):S157–S165.
4. Girardi FP, Cammisa FP, Jr., Sandhu HS, Alvarez L. The

placement of lumbar pedicle screws using computerised stereotactic guidance. *J Bone Joint Surg Br.* 1999;81(5):825–829.

5. Laine T, Lund T, Ylikoski M, Lohikoski J, Schlenzka D. Accuracy of pedicle screw insertion with and without computer assistance: a randomised controlled clinical study in 100 consecutive patients. *Eur Spine J.* 2000;9(3):235–240.

6. Castro WH, Halm H, Jerosch J, Malms J, Steinbeck J, Blasius S. Accuracy of pedicle screw placement in lumbar vertebrae. *Spine.* 1996;21(11):1320–1324.

7. Ishikawa Y, Kanemura T, Yoshida G, et al. Intraoperative, full-rotation, three-dimensional image (O-arm)-based navigation system for cervical pedicle screw insertion. *J Neurosurg Spine.* 2011;15(5):472–478.

8. Ito Y, Sugimoto Y, Tomioka M, Hasegawa Y, Nakago K, Yagata Y. Clinical accuracy of 3D fluoroscopy-assisted cervical pedicle screw insertion. *J Neurosurg Spine.* 2008;9(5):450–453.

9. Tang J, Zhu Z, Sui T, Kong D, Cao X. Position and complications of pedicle screw insertion with or without image-navigation techniques in the thoracolumbar spine: a meta-analysis of comparative studies. *J Biomed Res.* 2014;28(3):228–239.

10. Tormenti MJ, Kostov DB, Gardner PA, Kanter AS, Spiro RM, Okonkwo DO. Intraoperative computed tomography image-guided navigation for posterior thoracolumbar spinal instrumentation in spinal deformity surgery. *Neurosurg Focus.* 2010;28(3):E11.

11. Tabaraee E, Gibson AG, Karahalios DG, Potts EA, Mobasser JP, Burch S. Intraoperative cone beam-computed tomography with navigation (O-arm) versus conventional fluoroscopy (C-arm): a cadaveric study comparing accuracy, efficiency, and safety for spinal instrumentation. *Spine.* 2013;38(22):1953–1958.

12. Gelalis ID, Paschos NK, Pakos EE, et al. Accuracy of pedicle screw placement: a systematic review of prospective in vivo studies comparing free hand, fluoroscopy guidance, and navigation techniques. *Eur Spine J.* 2012;21(2):247–255.

13. Imagama S, Kawakami N, Tsuji T, et al. Perioperative complications and adverse events after lumbar spinal surgery: evaluation of 1012 operations at a single center. *J Orthop Sci.* 2011;16(5):510–515.

14. Proietti L, Scaramuzza L, Schiro' GR, Sessa S, Logroscino CA. Complications in lumbar spine surgery: a retrospective analysis. *Indian J Orthop.* 2013;47(4):340–345.

15. Ling JM, Dinesh SK, Pang BC, et al. Routine spinal navigation for thoraco-lumbar pedicle screw insertion using the O-arm three-dimensional imaging system improves placement accuracy. *J Clin Neurosci.* 2014;21(3):493–498.

16. Wang Y, Chen K, Chen H, et al. Comparison between free-hand and O-arm-based navigated posterior lumbar interbody fusion in elderly cohorts with three-level lumbar degenerative disease. *Int Orthop.* 2019;43(2):351–357.

17. Zhang W, Takigawa T, Wu Y, Sugimoto Y, Tanaka M, Ozaki T. Accuracy of pedicle screw insertion in posterior scoliosis surgery: a comparison between intraoperative navigation and preoperative navigation techniques. *Eur Spine J.* 2017;26(6):1756–1764.

18. Meng XT, Guan XF, Zhang HL, He SS. Computer navigation versus fluoroscopy-guided navigation for thoracic pedicle screw placement: a meta-analysis. *Neurosurg Rev.* 2016;39(3):385–391.

19. Shin MH, Hur JW, Ryu KS, Park CK. Prospective comparison study between the fluoroscopy-guided and navigation coupled with O-arm-guided pedicle screw placement in the thoracic and lumbosacral spines. *J Spinal Disord Tech.* 2015;28(6):E347–E351.

20. Shin MH, Ryu KS, Park CK. Accuracy and safety in pedicle screw placement in the thoracic and lumbar spines : comparison study between conventional C-arm fluoroscopy and navigation coupled with O-arm® guided methods. *J Korean Neurosurg Soc.* 2012;52(3):204–209.

21. Khanna AR, Yanamadala V, Coumans JV. Effect of intraoperative navigation on operative time in 1-level lumbar fusion surgery. *J Clin Neurosci.* 2016;32:72–76.

22. Liu H, Wang Y, Pi B, Qian Z, Zhu X, Yang H. Comparison of intraoperative O-arm- and conventional fluoroscopy (C-arm)-assisted insertion of pedicle screws in the treatment of fracture of thoracic vertebrae. *J Orthop Surg.* 2017;25(1):2309499016684090.

23. Rajasekaran S, Vidyadhara S, Ramesh P, Shetty AP. Randomized clinical study to compare the accuracy of navigated and non-navigated thoracic pedicle screws in deformity correction surgeries. *Spine.* 2007;32(2):E56–E64.

24. Han W, Gao Z-L, Wang J-C, et al. Pedicle screw placement in the thoracic spine: a comparison study of computer-assisted navigation and conventional techniques. *Orthopedics.* 2010;33(8):10.3928/01477447-20100625-14.

25. Kapoor S, Sharma R, Garg S, Jindal R, Gupta R, Goe A. Navigated pedicle screw placement using computed tomographic data in dorsolumbar fractures. *Indian J Orthop.* 2014;48(6):555–561.

26. Jin HM, Bai XQ, Pan XX, et al. Does the iliac wing influence L5 pedicle screw fixation? *World Neurosurg.* 2018;113:e302–e308.

**Disclosures and COI:** The authors declare no financial or intellectual conflicts of interest. No funding was received for the purpose of this study. Permissions have been granted to reproduce copyrighted materials and for patient consent forms. The study was approved by the institutional review board.

**Corresponding Author:** Benjamin T. K. Ding, MBBS, MRCS, Senior Resident, Tan Tock Seng Hospital, Singapore, 11 Jalan Tan Tock Seng, S308433. Phone: +65 97936549; Email: ding.tze.keong.benjamin@gmail.com. ORCID iD: 0000-0002-4099-720X

Published 0 Month 2020

This manuscript is generously published free of charge by ISASS, the International Society for the Advancement of Spine Surgery. Copyright © 2020 ISASS. To see more or order reprints or permissions, see <http://ijssurgery.com>.