

Single-Level Endoscopic TLIF Has Decreased Surgery Duration, Blood Loss, and Length of Hospital Stay While Achieving Similar 1-Year Clinical and Radiological Outcomes Compared With Conventional Minimally Invasive TLIF

David Shaoen Sim, Craigven Hao Sheng Sim, Lei Jiang and Zhixing Marcus Ling

Int J Spine Surg published online 14 June 2023
<https://www.ijssurgery.com/content/early/2023/06/09/8455>

This information is current as of November 27, 2024.

Email Alerts Receive free email-alerts when new articles cite this article. Sign up at:
<http://ijssurgery.com/alerts>

Single-Level Endoscopic TLIF Has Decreased Surgery Duration, Blood Loss, and Length of Hospital Stay While Achieving Similar 1-Year Clinical and Radiological Outcomes Compared With Conventional Minimally Invasive TLIF

DAVID SHAOEN SIM, MbChB¹; CRAIGVEN HAO SHENG SIM, MbChB¹; LEI JIANG, FRCS¹; AND ZHIXING MARCUS LING, FRCS¹

¹Department of Orthopaedic Surgery, Singapore General Hospital, Singapore, Singapore

ABSTRACT

Background: This study presents a single surgeon's experience comparing 1-year outcomes of endoscopic transforaminal lumbar interbody fusion (E-TLIF) vs minimally invasive transforaminal lumbar interbody fusion (MIS-TLIF) in an Asian population.

Methods: Retrospective review of consecutive patients who underwent single-level E-TLIF or MIS-TLIF by a single surgeon in a tertiary spine institution from 2018 to 2021 with 1-year follow-up. Inclusion criteria for both procedures were degenerative disc disease with grade I or II spondylolisthesis and mild to moderate central canal stenosis. Clinical outcomes assessed included surgery duration, blood loss, and length of stay. Patient-reported outcomes assessed included the visual analog score for back pain and lower limb pain, Oswestry Disability Index, and North American Spine Society Neurogenic Symptom Score. Radiographic parameters assessed included segmental lordosis, posterior disc height, listhesis, and the presence of cage migration or subsidence.

Results: Twelve E-TLIF and 34 MIS-TLIF patients were identified. E-TLIF had shorter surgery duration (165 ± 15 vs 259 ± 43 min for E-TLIF and MIS-TLIF groups, respectively; $P < 0.001$), reduced blood loss (83 ± 75 vs 181 ± 225 mL; $P = 0.033$), and decreased length of stay (1.8 ± 0.9 vs 4.7 ± 2.9 days; $P < 0.001$) compared with MIS-TLIF. E-TLIF and MIS-TLIF patients had significant improvements ($P < 0.05$) at 1 year in all patient-reported outcomes scores and radiographic parameters assessed. Both E-TLIF and MIS-TLIF patient groups also had similar postoperative patient-reported outcomes scores and radiographic parameters. No complications were recorded for E-TLIF, while MIS-TLIF had a case of dura tear and another case of meralgia paresthetica. There were no instances of cage subsidence, cage migration, or implant loosening in either group at 1 year.

Conclusions: Although the study size was limited because E-TLIF is a relatively new technique in our institution, 1-year results demonstrate that E-TLIF can be a safe and efficacious option that achieves clinical and radiological results similar to MIS-TLIF with the additional benefits of decreased surgical duration, blood loss, and length of hospital stay.

Clinical Relevance: The results of this study support the effectiveness and potential advantages of endoscopic TLIF compared with MIS-TLIF.

Level of Evidence: 3

Endoscopic Minimally Invasive Surgery

Keywords: Endoscopic transforaminal lumbar interbody fusion, minimally invasive transforaminal lumbar interbody fusion, lumbar degenerative disc disease, spinal stenosis

INTRODUCTION

Endoscopic spine surgery has seen significant advancements over the past few decades with technological improvements in optics and the design of surgical instruments. Endoscopic transforaminal lumbar interbody fusion (E-TLIF) represents the latest generation of endoscopic spine surgery, and early results are promising.¹ E-TLIF can be performed via the transforaminal approach or the posterior-lateral approach using either a

uniportal or a biportal technique.² In this study, E-TLIF was performed via a uniportal transforaminal approach under general anesthesia and neuromonitoring. E-TLIF involves a smaller skin incision and decreased soft tissue disruption compared with conventional minimally invasive transforaminal lumbar interbody fusion (MIS-TLIF).³ Unlike MIS-TLIF, E-TLIF largely depends on indirect decompression, which can be facilitated through the use of expandable cage technology.

There is limited literature evaluating E-TLIF in Asians with a smaller surface area for interbody fusion. This study presents a single surgeon's experience comparing 1-year outcomes of E-TLIF vs MIS-TLIF in an Asian population.

METHODS

Patient Population

A retrospective review was conducted on all consecutive patients who underwent single-level E-TLIF or MIS-TLIF by a single surgeon in a tertiary spine institution from 2018 to 2021 with at least 1-year follow-up. This study was reviewed and approved by our institution's ethics committee. Inclusion criteria for both procedures were patients who experience persistent neurological symptoms or intermittent claudication and do not respond to appropriate conservative treatment with concordant imaging evidence of single-level mild to moderate spinal stenosis or degenerative disc disease with grade I or II spondylolisthesis. Exclusion criteria were severe spinal stenosis causing cauda equina syndrome or footdrop, trauma, infection, high-grade spondylolisthesis, and previous lumbar spine surgical treatment or radiofrequency ablation. The choice of technique was dependent on the availability of endoscopic technology in later years, surgeon, and patient preference.

Surgical Technique

Both E-TLIF and MIS-TLIF techniques were done under general anesthesia and neuromonitoring. Patients were positioned prone on a Jackson table.

MIS-TLIF was performed through a paramedian Wiltse plane approach and the use of tubular retractors to expose the posterior elements. This is followed by facetectomy, discectomy, interbody cage insertion,

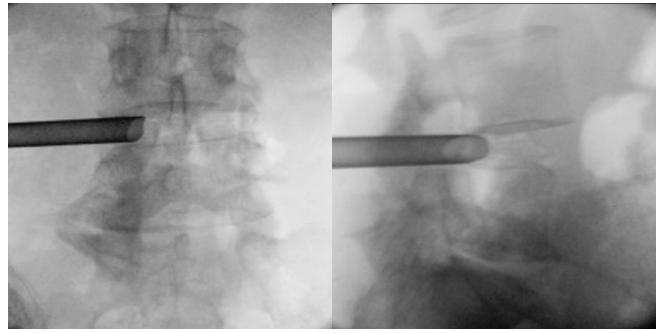


Figure 2. Working cannula inserted after sequential dilation.

packing of the bone graft, laminectomy, and finally nerve root decompression to ensure that all affected neural elements at that level are thoroughly decompressed.

In E-TLIF, a small skin incision is made about 8 to 13 cm from the midline with the aid of fluoroscopic localization. The disc space is initially accessed through Kambin's triangle with an 18G spinal needle. A Nitinol wire is inserted through the spinal needle (Figure 1), which is used to guide a series of dilators into the disc space, followed by a 7-mm working cannula (Figure 2).

An endoscope is then introduced to visualize the interbody disc and other anatomical landmarks. Discectomy is achieved using specialized tools specifically designed for E-TLIF, including micropituitary rongeurs (Figure 3), expandable shavers (Figure 3), back-biting curettes (Figure 3), electrocautery, and stainless-steel brushes on a powered drill system. The endoscope is reintroduced to the disc space directly to visualize the adequacy of endplate preparation.

The working cannula is subsequently changed to a larger 8.5-mm diameter cannula. Cage height and length are templated using an adjustable trial with fluoroscopic aid. Allogeneous bone grafts are packed into the disc space together with recombinant human

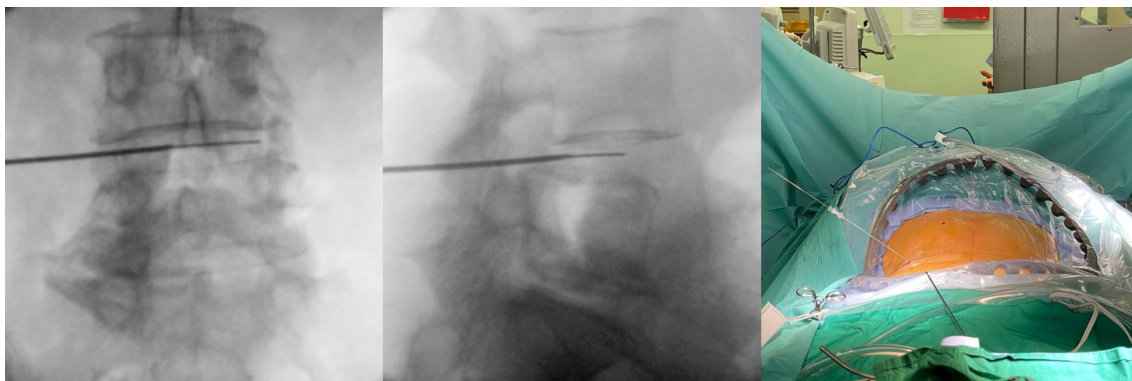


Figure 1. Nitinol wire inserted through 18G spinal needle into the disc space after fluoroscopic confirmation of correct positioning.

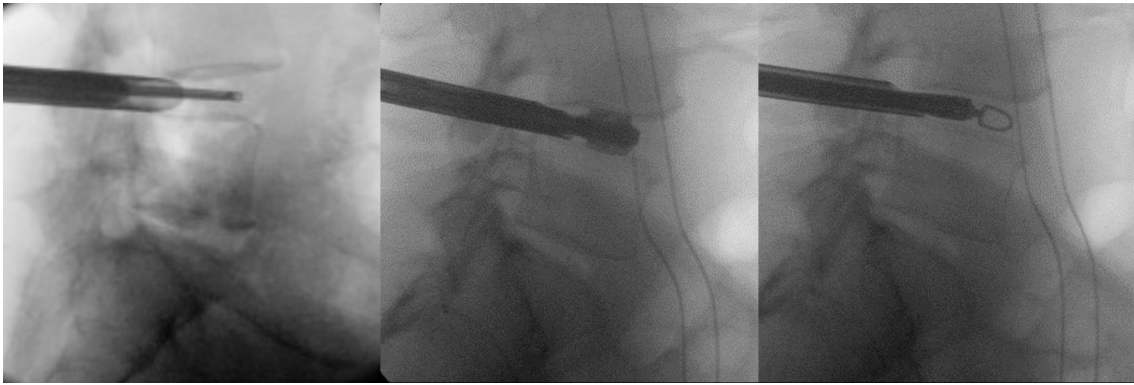


Figure 3. Discectomy and endplate preparation performed through working cannula with aid of fluoroscopy using micropituitary rongeurs (left), expandable shavers (middle), and back-biting currettes (right).

bone morphogenetic protein-2. This is followed by the insertion of an expandable titanium interbody cage (Figure 4).

The titanium interbody cage is then expanded in situ (Figure 4). The amount of expansion is first estimated by preoperative templating and subsequently confirmed with expansion under lateral view fluoroscopy. The use of a torque-limiting handle prevents expansion beyond the safety threshold.

For both E-TLIF and MIS-TLIF, the surgery is completed with the instrumentation of bilateral pedicles with screws and rods (Figure 5).

Clinical and Radiological Outcomes

This study assessed clinical outcomes including surgery duration, blood loss, length of stay, and patient-reported outcomes, as well as radiological outcomes. Patient-reported outcomes included the visual analog score (VAS) for back pain and lower limb pain, Oswestry Disability Index (ODI), and North American Spine Society (NASS) Neurogenic Symptom Score (NSS). All clinical assessments were performed by third-party independent health care professionals not

involved in the study within our institution's Orthopedic Diagnostic Center using a standardized procedure at routine time intervals.

Radiographic parameters assessed included segmental lordosis, posterior disc height, and amount of listhesis (Figure 6). Standard anterior-posterior and lateral radiographs of the lumbar spine were also taken at routine time intervals, including preoperatively and at final follow-up. Segmental lordosis was defined as the angle between the inferior endplate of the cephalad vertebral body and the superior endplate of the caudal vertebral body. Posterior disc height was defined as the distance between the inferior endplate of the cephalad vertebra and superior endplate of the caudal vertebra at the posterior vertebral body line, as described by Hsieh et al.⁴ The amount of listhesis was measured by calculating the horizontal distance between the posterior vertebral body line of the cephalad vertebral body and that of the caudal vertebral body. Radiographs were also evaluated for cage migration or subsidence as defined in previous studies.^{5,6}



Figure 4. Expandable titanium interbody cage before expansion (left) and after expansion with a torque-limiting handle (middle). Final height and position of the expandable cage was confirmed with intraoperative fluoroscopy (right).

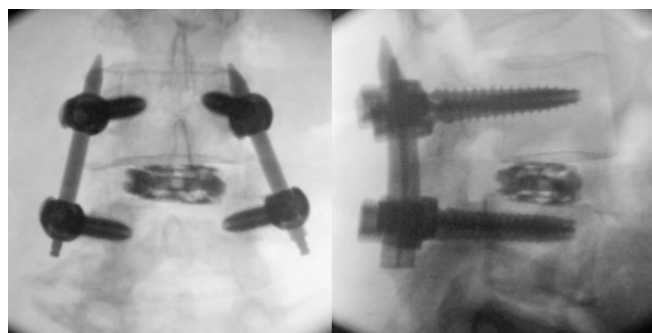


Figure 5. Final intraoperative fluoroscopic images following insertion of expandable titanium interbody cage and instrumentation of bilateral pedicles with screws and rods.

Statistical Analysis

Descriptive statistics were reported as means and SDs. Statistical analyses were used to compare the above outcome measures. A paired *t* test was used to compare continuous variables between the same group of patients, while an unpaired *t* test was used to compare continuous variables between different groups of patients. The χ^2 test was used to compare dichotomous variables. Statistical significance was determined at $P < 0.05$. Data analysis was conducted using SPSS Statistics for Windows version 22.0 (IBM Corp., Armonk, NY).

RESULTS

Twelve E-TLIF and thirty-four MIS-TLIF patients were included in this study. Both groups were similar in age, body mass index (BMI), gender, and levels at which surgery was performed (Table 1). The average BMI for both groups was overweight according to World Health Organization Asian BMI standards, and the E-TLIF group had 5 overweight patients and 3 obese patients.

E-TLIF had shorter surgery duration (165 ± 15 vs 259 ± 43 minutes for E-TLIF and MIS-TLIF group, respectively; $P < 0.001$), reduced blood loss (83 ± 75

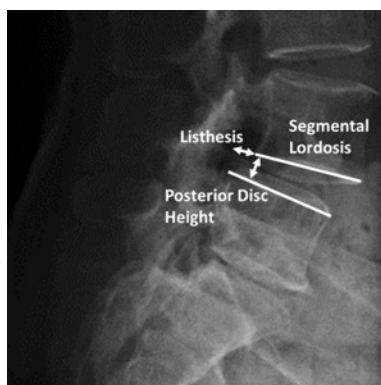


Figure 6. Lateral lumbar radiograph demonstrating the measurement of segmental lordosis, posterior disc height, and amount of listhesis.

Table 1. Patient demographics.

Demographics	Endoscopic TLIF (n = 12)	Minimally Invasive TLIF (n = 34)	P Value
Sex, man:woman	5:7	17:17	0.619
Age, y	67.4 ± 7.1	66.3 ± 9.9	0.684
BMI, kg/m ²	25.4 ± 4.8	25.3 ± 4.1	0.952
Spinal level operated			
L3–L4	1 (8%)	3 (9%)	0.336
L4–L5	11 (92%)	27 (79%)	
L5–S1	0 (0%)	4 (12%)	

Abbreviation: TLIF, transforaminal lumbar interbody fusion.

181 ± 225 mL; $P = 0.033$), and decreased length of stay (1.8 ± 0.9 vs 4.7 ± 2.9 days; $P < 0.001$) compared with MIS-TLIF (Table 2).

E-TLIF and MIS-TLIF patients had significant improvements at 1 year in all patient-reported outcomes assessed, comprising VAS for back pain, VAS for lower limb pain, ODI, and NSS (Table 3). E-TLIF and MIS-TLIF patients also had significant improvements in the radiographic parameters assessed, comprising segmental lordosis, posterior disc height, and amount of listhesis (Table 3).

Between the E-TLIF and MIS-TLIF groups, there was no significant difference in postoperative VAS for back pain (0.6 ± 1.5 vs 0.7 ± 1.8 ; $P = 0.777$), VAS for lower limb pain (0.8 ± 1.9 vs 0.3 ± 1.1 ; $P = 0.355$), ODI (19.2 ± 10.0 vs 15.9 ± 13.1 ; $P = .378$), or NSS (11.1 ± 16.9 vs 14.6 ± 16.4 ; $P = 0.673$; Table 2). There was also no significant difference in the change in segmental lordosis (2.9 ± 1.9 vs 2.3 ± 2.6 ; $P = 0.444$), posterior disc height (2.7 ± 1.2 vs 2.0 ± 1.4 ; $P = 0.145$), or listhesis (-4.4 ± 2.8 vs -3.1 ± 2.4 ; $P = 0.157$) between the E-TLIF and MIS-TLIF groups (Table 2), making both groups comparable.

No complications were recorded for E-TLIF, while MIS-TLIF had a case of dura tear and another case of

Table 2. Comparison of postoperative outcomes between endoscopic TLIF and minimally invasive TLIF.

Outcome	Endoscopic TLIF	Minimally Invasive TLIF	P Value
Clinical outcomes			
Length of stay, d	1.8 ± 0.9	4.7 ± 2.9	<0.001
Blood loss, mL	83 ± 75	181 ± 225	0.033
Surgery duration, min	165 ± 15	259 ± 43	<0.001
Patient-reported outcome scores			
VAS back pain	0.6 ± 1.5	0.7 ± 1.8	0.777
VAS lower limb pain	0.8 ± 1.9	0.3 ± 1.1	0.355
Oswestry Disability Index	19.2 ± 10.0	15.9 ± 13.1	0.378
Neurogenic Symptom Score	12.1 ± 17.4	14.6 ± 16.4	0.673
Radiological outcomes			
Change in segmental lordosis, °	2.9 ± 1.9	2.3 ± 2.6	0.444
Change in posterior disc height, mm	2.7 ± 1.2	2.0 ± 1.4	0.145
Change in listhesis, mm	-4.4 ± 2.8	-3.1 ± 2.4	0.157

Abbreviation: VAS, visual analog score.

Note: Data presented as mean ± SD.

Table 3. Endoscopic TLIF clinical and radiological outcomes.

Endoscopic TLIF	Preoperative	Postoperative	Difference	P Value
Patient-reported outcome scores				
VAS back pain	5.5 ± 3.0	0.6 ± 1.5	-4.9 ± 2.7	<0.001
VAS lower limb pain	5.8 ± 3.0	0.8 ± 1.9	-4.9 ± 2.8	<0.001
Oswestry Disability Index	39.8 ± 14.1	19.2 ± 10.0	-20.7 ± 15.0	<0.001
Neurogenic Symptom Score	35.4 ± 11.2	12.1 ± 17.4	-23.3 ± 21.5	0.003
Radiological outcomes				
Segmental lordosis, °	6.0 ± 3.1	8.9 ± 1.5	2.9 ± 1.9	<0.001
Posterior disc height, mm	6.8 ± 1.5	9.5 ± 1.3	2.7 ± 1.2	<0.001
Listhesis, mm	7.1 ± 3.7	2.7 ± 1.4	-4.4 ± 2.8	<0.001

Abbreviations: TLIF, transforaminal lumbar interbody fusion; VAS, visual analog score.

meralgia paresthetica. There was no cage subsidence, cage migration, or implant loosening in either group at 1 year.

DISCUSSION

This study demonstrates that E-TLIF performed through a uniportal transforaminal approach can treat degenerative spine conditions successfully with significant improvement in patients’ symptoms and a reduction in VAS for back pain and lower limb pain, ODI, and NSS. This echoes the findings of similar studies that demonstrate the effectiveness of E-TLIF.^{7,8} This study also shows that E-TLIF can lead to similar improvements in clinical patient-reported outcomes as compared with MIS-TLIF following surgery. Recent reviews confirm no significant differences between the 2 procedures in clinical efficacy.^{2,9}

Compared with MIS-TLIF, E-TLIF had significantly decreased surgery duration, blood loss, and length of hospital stay. The benefits of decreased blood loss and length of hospital stay with E-TLIF have also been reported in recent studies.^{9,10} A decreased length of hospital stay is likely due to less postoperative pain from a smaller incision and decreased soft tissue violations, resulting in earlier ambulation and rehabilitation (Figure 7).³ In our experience, decreased surgical time is because E-TLIF depends on indirect decompression as opposed to MIS-TLIF, which requires direct decompression of neural elements.¹¹ E-TLIF performed through Kambin’s triangle avoids the need to perform a facetectomy to access the disc space for the insertion of an interbody fusion device. Nevertheless, a recent meta-analysis comparing E-TLIF and MIS-TLIF shows that E-TLIF has a longer operating time compared with MIS-TLIF, suggesting that our results may not be replicated in other institutions.²

This study demonstrates that E-TLIF can restore posterior disc height and correct listhesis (Figure 8), thereby indirectly resulting in neuroforaminal and lateral recess decompression. Despite the fact that

E-TLIF requires operating through an even smaller surgical window compared with MIS-TLIF, we have shown in this section that the degree of posterior disc height restoration and listhesis correction after E-TLIF is not inferior to that of MIS-TLIF. The use of expandable titanium interbody cages is essential to achieving this goal, as the interbody cages, which are inserted through an 8.5-mm working cannula, can reach a final height of up to 14 mm after in situ expansion. Overexpansion of the cage can be prevented by preoperative templating, using a torque-limiting handle, and finally confirmation with lateral view fluoroscopy to prevent the risk of future subsidence. Additional correction of spondylolisthesis and stabilization of the operated spinal segments were obtained through the reduction of pedicle screws to rods. Lv et al¹² also reported in their study that E-TLIF, though the posterior-lateral

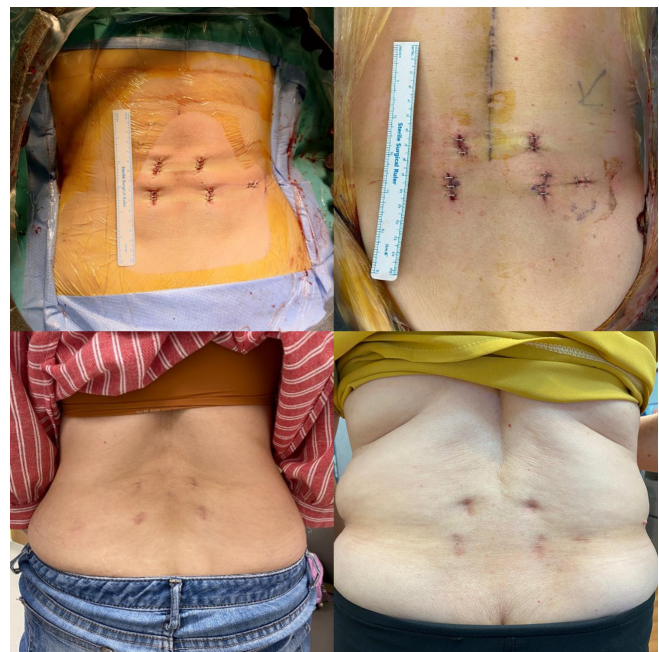


Figure 7. Postoperative and 1-year photographs of stab incisions following single-level endoscopic transforaminal lumbar interbody fusion.

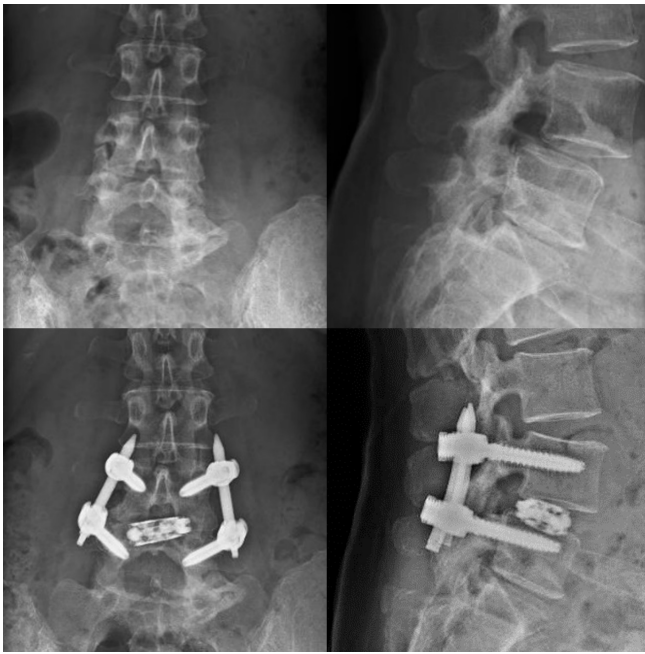

Figure 8. Preoperative (top) and postoperative (bottom) lumbar spine radiographs of a patient who underwent successful endoscopic transforaminal lumbar interbody fusion for treatment of lower limb radiculopathy and lower back pain with significant improvement of symptoms at 1 year. Postoperative radiographs demonstrate reduction of L4-L5 anterolisthesis and improvement of posterior disc height.

approach, can achieve similar reduction of spondylolisthesis as MIS-TLIF.

This study also demonstrates that E-TLIF can be performed safely on overweight and obese patients with good results. Five overweight and 3 obese patients underwent E-TLIF without complications or significantly increased surgical difficulty and had improvement in their symptoms. Given this positive early experience with E-TLIF in patients with high BMI, there may be a further role for E-TLIF in these patients. MIS-TLIF has previously been demonstrated to be safe in obese patients and has better outcomes compared with open TLIF with regards to decreased blood loss, shorter hospitalization, reduced dural tear, and wound infection rates.¹³ Nevertheless, performing conventional MIS-TLIF using METREx tubes in obese patients is technically more challenging as longer tubes must be utilized due to the thickness of subcutaneous fat, resulting in a greater working distance. However, this technical challenge is not present when performing E-TLIF in obese patients, as the endoscopic view during endoscopic lumbar spine surgery is independent of the working distance between skin and intervertebral disc.¹⁴ Further studies will be useful to further elucidate the benefits of E-TLIF in patients with a high BMI.

Previous systematic reviews suggest similar complication rates between the 2 procedures.^{2,9} In this study,

no complications were recorded for E-TLIF, while the MIS-TLIF group had a case of dura tear and another case of meralgia paresthetica. The E-TLIF approach avoids direct decompression of neural elements, and the thecal sac is not exposed directly, thus reducing the incidence of dura tear. The second patient who underwent MIS-TLIF developed paresthesia over her right thigh—likely due to compression of the lateral femoral cutaneous nerve that occurred due to positioning on the surgical table during the MIS-TLIF procedure. Patients who lie prone on the Jackson table for a prolonged period have a risk of compression of the lateral femoral cutaneous nerve at the level of the anterior superior iliac spine, resulting in meralgia paresthetica, and this is an unfortunate complication of positioning. This also highlights an advantage of E-TLIF, which is shorter operative duration, as decreased surgical time has been associated with lower rates of postoperative meralgia paresthetica.¹⁵

This study assessed all consecutive E-TLIF and MIS-TLIF cases performed by a single surgeon from a tertiary spine institution. All patients had at least a 1-year follow-up. Another advantage of this study is that the surgical technique is consistent for all patients since it is performed by the same surgeon. While patients who underwent E-TLIF had good results postoperatively in our study, we concede that E-TLIF may not be suitable in certain cases. Extremely narrow Kambin's triangle due to collapsed foramen or intervertebral disc height is a relative contraindication for the endoscopic technique. Anatomical limitations can restrict the application of the transforaminal endoscopic approach.¹⁶ A smaller working space through a narrow Kambin's triangle can also cause technical difficulties for thorough disc preparation and safe cage insertion, leading to complications such as exiting nerve root injury, nonunion, or case migration.⁸

CONCLUSION

While study size was limited as E-TLIF is a relatively new technique in our institution, 1-year results are encouraging and demonstrate that in an Asian population, E-TLIF can be a safe and efficacious option that achieves similar clinical and radiological results to MIS-TLIF, with the additional benefits of decreased surgical duration, blood loss, and length of hospital stay.

REFERENCES

1. Kim M, Kim H-S, Oh SW, et al. Evolution of spinal endoscopic surgery. *Neurospine*. 2019;16(1):6–14. doi: 10.14245/ns.1836322.161
2. Son S, Yoo BR, Lee SG, Kim WK, Jung JM. Full-endoscopic versus minimally invasive lumbar Interbody fusion for lumbar degenerative diseases: A systematic review and meta-analysis. *J Korean Neurosurg Soc*. 2022;65(4):539–548. doi: 10.3340/jkns.2021.0168
3. Ahn Y, Youn MS, Heo DH. Endoscopic transforaminal lumbar Interbody fusion: a comprehensive review. *Expert Rev Med Devices*. 2019;16(5):373–380. doi: 10.1080/17434440.2019.1610388
4. Hsieh PC, Koski TR, O’Shaughnessy BA, et al. Anterior lumbar Interbody fusion in comparison with transforaminal lumbar interbody fusion: implications for the restoration of Foraminal height, local disc angle, lumbar lordosis, and sagittal balance. *J Neurosurg Spine*. 2007;7(4):379–386. doi: 10.3171/SPI-07/10/379
5. Parisien A, Wai EK, ElSayed MSA, Frei H. Subsidence of spinal fusion cages: a systematic review. *Int J Spine Surg*. 2022;16(6):1103–1118. doi: 10.14444/8363
6. Hu YH, Niu CC, Hsieh MK, Tsai TT, Chen WJ, Lai PL. Cage positioning as a risk factor for posterior cage migration following transforaminal lumbar interbody fusion - an analysis of 953 cases. *BMC Musculoskelet Disord*. 2019;20(1):260. doi: 10.1186/s12891-019-2630-0
7. Kolcun JPG, Brusko GD, Basil GW, Epstein R, Wang MY. Endoscopic transforaminal lumbar Interbody fusion without general anesthesia: operative and clinical outcomes in 100 consecutive patients with a minimum 1-year follow-up. *Neurosurg Focus*. 2019;46(4):2018.12.FOCUS18701. doi: 10.3171/2018.12.FOCUS18701
8. Wu J, Liu H, Ao S, et al. Percutaneous endoscopic lumbar Interbody fusion: technical NOTE and preliminary clinical experience with 2-year follow-up. *Biomed Res Int*. 2018;2018:5806037. doi: 10.1155/2018/5806037
9. Kou Y, Chang J, Guan X, Chang Q, Feng H. Endoscopic lumbar interbody fusion and minimally invasive transforaminal lumbar Interbody fusion for the treatment of lumbar degenerative diseases: a systematic review and meta-analysis. *World Neurosurg*. 2021;152:e352–e368. doi: 10.1016/j.wneu.2021.05.109
10. Ao S, Zheng W, Wu J, et al. Comparison of preliminary clinical outcomes between percutaneous endoscopic and minimally invasive transforaminal lumbar Interbody fusion for lumbar degenerative diseases in a tertiary hospital: is percutaneous endoscopic procedure superior to MIS-TLIF? A prospective cohort study. *Int J Surg*. 2020;76:136–143. doi: 10.1016/j.ijsu.2020.02.043
11. Lioumakos JI, Wang MY. The endoscopic approach to lumbar discectomy, fusion, and enhanced recovery: a review. *Global Spine J*. 2020;10(2 Suppl):65S–69S. doi: 10.1177/2192568219884913
12. Lv Y, Chen M, Wang S-L, et al. Endo-TLIF versus MIS-TLIF in 1-segment lumbar spondylolisthesis: a prospective randomized pilot study. *Clin Neurol Neurosurg*. 2022;212:107082. doi: 10.1016/j.clineuro.2021.107082
13. Tan JH, Liu G, Ng R, Kumar N, Wong HK, Liu G. Is MIS-TLIF superior to open TLIF in obese patients? A systematic review and meta-analysis. *Eur Spine J*. 2018;27(8):1877–1886. doi: 10.1007/s00586-018-5630-0
14. Bae JS, Lee SH. Transforaminal full-endoscopic lumbar discectomy in obese patients. *Int J Spine Surg*. 2016;10:18. doi: 10.14444/3018
15. Yang S-H, Wu C-C, Chen P-Q. Postoperative meralgia parasthetica after posterior spine surgery: incidence, risk factors, and clinical outcomes. *Spine (Phila Pa 1976)*. 2005;30(18):E547–50. doi: 10.1097/01.brs.0000178821.14102.9d
16. Hussain I, Yeung AT, Wang MY. Challenges in spinal endoscopy. *World Neurosurg*. 2022;160:132–137. doi:10.1016/j.wneu.2021.11.082

Funding: The authors received no financial support for the research, authorship, and/or publication of this article.

Declaration of Conflicting Interests: The authors report no conflicts of interest in this work.

Ethical Standards: Approval was obtained from the institution's ethics committee. The procedures used in this study adhere to the tenets of the Declaration of Helsinki.

Corresponding Author: David Shaoen Sim, Department of Orthopaedic Surgery, Singapore General Hospital, 18 Wilkinson Road, Singapore 436674, Singapore; davidssimshaoen@gmail.com

This manuscript is generously published free of charge by ISASS, the International Society for the Advancement of Spine Surgery. Copyright © 2023 ISASS. To see more or order reprints or permissions, see <http://ijssurgery.com>.