

## Anterior Cervical Osteotomy and Corpectomy for Rigid Kyphosis: A Surgical Video

Jacob Greenberg, Matt Magro, R. Shane Tubbs and Alexander Spiessberger

*Int J Spine Surg* published online 12 December 2023  
<https://www.ijssurgery.com/content/early/2023/12/10/8555>

This information is current as of November 23, 2024.

---

**Email Alerts** Receive free email-alerts when new articles cite this article. Sign up at:  
<http://ijssurgery.com/alerts>

# Anterior Cervical Osteotomy and Corpectomy for Rigid Kyphosis: A Surgical Video

JACOB GREENBERG, MD<sup>1</sup>; MATT MAGRO, BS<sup>2</sup>; R. SHANE TUBBS, PhD, MS, PA-C<sup>3</sup>; AND  
ALEXANDER SPIESSBERGER, MD<sup>1</sup>

<sup>1</sup>Department of Neurosurgery, Cleveland Clinic, Cleveland, OH, USA; <sup>2</sup>Ohio University Heritage College of Osteopathic Medicine Cleveland, Warrensville Heights, OH, USA; <sup>3</sup>Department of Neurosurgery, Tulane University School of Medicine, New Orleans, LA, USA

Keywords: cervical deformity, osteotomy, cervical kyphosis, cervical correction, spinal cord, decompression, uncinete resection

Kyphotic cervical deformities are rare and can lead to an inability to maintain neutral gaze, pain, and neurological dysfunction. Surgery can restore normal alignment, leading to decreased pain and neurological improvement. Anterior osteotomies, involving complete resection of the uncovertebral joints in combination with corpectomy and expandable cage placement, are a powerful strategy for treating these pathologies. In the present article, we demonstrate indications and surgical techniques for an anterior cervical osteotomy through a surgical video. .

The Supplemental Video shows a patient undergoing anterior cervical osteotomy and corpectomy to treat focal kyphosis at C4/C5. An 18-year-old male patient presented with increasing spasticity of the upper and lower extremities. On imaging, he was found to have

20° of focal kyphosis at C4 to C5 with cord draping. The patient underwent discectomies at C4 to C5 and C5 to C6 with an uncinete resection at C4 to C5 and C5 corpectomy. An expandable interbody cage was placed, which helped realign the spine after the anterior release has been completed. We achieved almost complete correction of kyphosis and undrapping of the spinal cord, and the patient's spasticity subjectively improved quickly.

Anterior over posterior cervical surgery has the advantage of significantly less postoperative pain and lower infection rates, which seemed appealing in this patient with pre-existing chronic pain. The key in reducing the kyphosis was sufficient anterior release by means of uncinectomy and intraoperative traction in extension. Furthermore, an expandable corpectomy

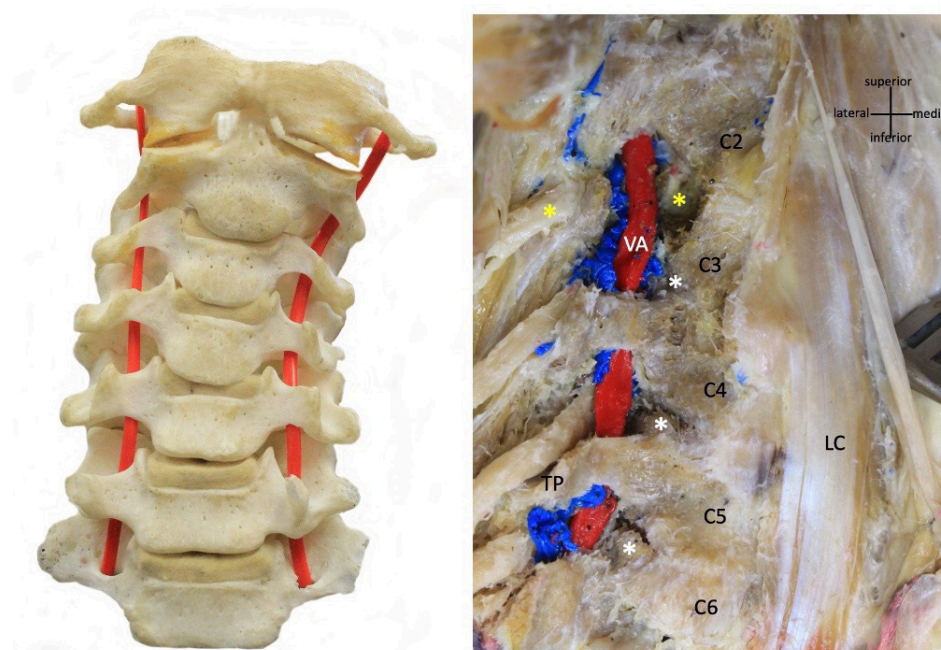


Figure. Cervical spine cadaveric specimen. LC, longus colli muscle; TP, transverse process; VA, vertebral artery. The yellow asterisk indicates the C2 nerve root.

cage has an additional advantage of further increasing segmental lordosis by cage expansion. Posterior longitudinal ligament release is optional.

A combination of anterior cervical osteotomy, corpectomy, and placement of an expandable cage can provide substantial segmental sagittal plane correction, provided the posterior elements are mobile. The intimate relationship of the unciniate process with the vertebral artery, perivertebral venous plexus, and nerve root is outlined in Figure.

## ACKNOWLEDGMENTS

This study was supported by Globus Medical.

**Funding:** Globus Medical paid the journal's article processing fee for this article.

**Declaration of Conflicting Interests:** The authors report no conflicts of interest in this work.

**Disclosures:** Jacob Greenberg received grants/contracts from BJC/WU Big Ideas Competition, the National Congress of Surgeons, and NINDS and

reports participation on a data safety monitoring board or advisory board for the Department of Defense. R. Shane Tubbs received royalties/licenses from Elsevier, Springer, Wiley, Thieme, and Charles Thomas and support for attending meetings/travel from Wiley and Elsevier and had a leadership/fiduciary role for the American Association of Clinical Anatomists. Alexander Spiessberger received grants from SI-BONE, EDS Society Germany, and Globus.

**Corresponding Author:** Alexander Spiessberger, Department of Neurosurgery, Cleveland Clinic, 9500 Euclid Ave, Cleveland, OH 44195, USA; Alexander.s.spiessberger@gmail.com

Received 05 April 2023

Accepted 16 July 2023

This manuscript is generously published free of charge by ISASS, the International Society for the Advancement of Spine Surgery. Copyright © 2023 ISASS. To see more or order reprints or permissions, see <http://ijssurgery.com>.