

Elective Spinal Transpedicular Ablation of the Basivertebral Nerve of the Vertebral Segment in Adult Spinal Deformity Patients

Guy Fogel, Jake Dickinson and Sunny Vuong

Int J Spine Surg published online 24 August 2024
<https://www.ijssurgery.com/content/early/2024/08/19/8632>

This information is current as of August 25, 2024.

Email Alerts Receive free email-alerts when new articles cite this article. Sign up at:
<http://ijssurgery.com/alerts>

Elective Spinal Transpedicular Ablation of the Basivertebral Nerve of the Vertebral Segment in Adult Spinal Deformity Patients

GUY FOGEL, MD¹; JAKE DICKINSON, MD²; AND SUNNY VUONG³

¹Christus Santa Rosa Spine Clinic, San Antonio, TX, USA; ²University of Texas Health Science Center San Antonio, San Antonio, TX, USA; ³Yale University New Haven Connecticut, New Haven, CT, USA

ABSTRACT

Background: Ablation of the basivertebral nerve (BVNA) innervating the vertebral endplate has become a standard treatment of vertebrogenic chronic low back pain (CLBP) arising from vertebral endplate damage. BVNA treatment of CLBP in clinical trials was successful and durable for pain relief and return to daily activities. This case review adds new information about older patients with adult degenerative spinal deformity (ASD) and associated comorbidities not previously described in clinical trials.

Methods: One hundred and eighteen ASD patients with vertebrogenic CLBP in a community practice setting underwent 503 levels of BVNA (average 4.3 levels). Forty-one patients with minimal comorbidities (Group A) were compared to 77 patients with significant comorbidities (Group B). Visual analog scale (VAS 10 cm) and Oswestry Disability Index (ODI 100-point scale) were obtained before BVNA and at a last follow-up (LFU).

Results: Group A VAS at LFU was an average of 2 cm, a 7 cm improvement. Group B VAS at LFU was 3 cm, a 6 cm improvement. At LFU, Group A ODI mean was 14 points or minimal disability, with a 39-point improvement, and Group B improved 28 points to 29 but remained moderately disabled. At LFU, the lumbar stenosis with laminectomy and BVNA subgroup of 26 had mean VAS 2 cm and ODI 28-point improvement but remained on average 21 points with a final low moderate disability. Eleven laminectomy and BVNA patients had continued posterior column pain related to radiculopathy, and or peripheral neuropathy, and sacroiliac joint pain in 30%. Mobile spondylolisthesis in 21 patients in Group B at LFU had a 6 cm improvement of VAS and 25-point improvement of ODI but remained moderately disabled on ODI. At LFU in group B, there was a 20% incidence of continued stenosis and radiculopathy symptoms. At LFU, Lumbar fusion was recommended in 9. Vertebral compression fracture (VCF) occurred in 9 after BVNA (10%) of Group B. These patients were older (mean 78 years), and all had significant osteoporosis. Eight fractures were within the area of the BVNA, and 1 was an S2 sacral fracture. These VCF patients were treated with vertebroplasty or kyphoplasty and continued preventive care with added teriparatide. At LFU, the VCF subgroup had a modest 6 cm improvement in VAS to 4 cm and continued to have significant severe to moderate disability (Oswestry Disability Index average of 38 points).

Conclusion: Clinical trials of BVNA treatment of CLBP found success and durability for pain relief and daily activities. Patients with ASD without comorbidities showed durable pain relief of vertebrogenic CLBP and return of daily activities similar to clinical trials. In those with comorbidities, the result was an improvement in pain and disability that could be diminished by the complications related to the comorbidities. This is new information about BVNA for older patients with spinal deformity and other comorbidities. This study could impact research practice and policy to expand indications of BVNA to patients with adult spinal deformity.

Clinical Relevance: This case series represents the only literature regarding patients with adult spinal deformity treated with BVNA. The results were predictable and reproducible. Many patients were satisfied, would have the procedure again and would recommend BVNA to friends and family. This finding should encourage acceptance of patients with ASD for BVNA and, in fact, BVNA should probably be done before any fusion to limit and choose levels for inclusion in fusion.

Level of Evidence: 4.

Novel Techniques & Technology

Keywords: chronic low back pain, basivertebral nerve ablation, radiofrequency, endplate degeneration, modic changes, community practice setting

INTRODUCTION

Chronic low back pain (CLBP) is the most costly occupational injury and the leading cause of disability

in the world.¹ CLBP may lead to a compromised quality of life that strains societal relationships and increases absenteeism and work-related disability. The lack of validated diagnostic standards leads most patients

to be diagnosed as having nonspecific low back pain (LBP), which leads to nonvalidated and nonscientific treatments. Traditional treatments for CLBP include avoidance of pain aggravating activities, specific home exercises, heat-cold modalities, low-impact aerobic activities, and pharmacotherapy. Patients are often treated with palliative injections in the hope that the CLBP will regress. Fusion surgical intervention may be recommended in refractory cases.²

Research has shown that disc degeneration (DD) is strongly associated with CLBP, and more recently, there is evidence that the vertebral endplate (VEP) and the disc combine as a functional unit with pathological innervation of the VEP associated with DD. The VEP is susceptible to damage causing inflammation and nerve proliferation.^{3,4} The damage to VEP is readily identified by type 1 and/or type 2 Modic changes on magnetic resonance imaging, a specific biomarker for CLBP.⁵⁻⁷ These Modic biomarkers are associated with more severe CLBP, higher levels of disability, and worse outcomes of conservative care leading to higher costs of treatment.⁸⁻¹² Vertebrogenic pain was recently validated by the Centers for Disease Control and Prevention with International Classification of Diseases, 10 Revision, code M54 to M51. Patients with lumbar vertebrogenic pain have anterior column symptoms of midline LBP aggravated by sitting and bending (forward flexion). This is contrasted to posterior column pain associated with paraspinal discomfort, buttock and posterior thigh pain, and pain in extension commonly seen with lumbar facet joint pain.¹³

Anatomically, the innervation of both VEPs comes together in the center of the vertebral body as the basivertebral nerve (BVN) and exits posteriorly in the midline. The pain transmitted from the VEP through the BVN is said to be “vertebrogenic pain.” The interruption of pain transmission from the VEPs via destruction of the intraosseous BVN using radiofrequency ablation is a treatment option for patients with vertebrogenic pain [BVN ablation (BVNA)]. The American Medical Association Current Procedural Terminology Editorial Panel recently recognized the evidence for this minimally invasive outpatient treatment by approving Current Procedural Terminology Category I codes for thermal destruction of intraosseous BVN: 64628 and 64629.

BVNA is a minimally invasive spinal procedure targeting the nerve (BVN) within the vertebral body that is responsible for carrying nociceptive information from a damaged VEP. BVNA is an accepted and effective treatment for vertebrogenic CLBP based on prospective trials, including a Level 1 sham-controlled

randomized controlled trial and a second Level 1 randomized controlled trial against standard conservative management. Data suggest the durability of the result through 24 months and to 9 years in the Smart trial.¹⁴⁻²⁰ Treatment guidelines, systemic reviews, and meta-analyses of BVNA have been conducted by spine care organizations including the International Society for the Advancement of Spine Surgery (ISASS), the North American Spine Society, and the American Society of Pain and Neuroscience.^{2,12,21-25} ISASS issued the 2020 guidelines for the usage of BVNA in the treatment of CLBP where, at the time, there was no specific diagnostic code for vertebrogenic LBP or CPT codes for the procedure.² Lorio et al concluded that BVNA was a new minimally invasive procedure to treat CLBP diagnosed by clinical evidence and magnetic resonance imaging (MRI) Modic changes, which were proven in 2 RCTs to be beneficial and durable at 24 months. In 2022, ISASS published a literature review,²³ which demonstrated the best results occurred with the most precise targeting of the BVN. The new diagnosis code for vertebrogenic LBP was announced (ICD10 M54.51), and the new category 1 CPT codes for the procedure were announced as 64628 and 64629. These guidelines, based on clinical evidence and literature reviews, demonstrate the safety, effectiveness, durability, and, most importantly, reproducibility of the BVNA procedure for a well-defined population of CLBP patients.

As BVNA treatment came to community practice, it was offered to patients with adult degenerative spinal deformity (ASD) such as spondylolisthesis and scoliosis. ASD is degenerative in origin, progressive, and always has VEP damage, with DD often asymmetrically located at the apex, as well as top and bottom of the deformity. ASD occurs adjacent to still segments and is often seen in adjacent segments following surgical intervention with fusion or laminectomy. ASD results in accumulative damage to the VEP, intervertebral discs, and facet joints that occur asymmetrically within the deformity that causes progression of the rotation angulation of scoliosis and displacement in spondylolisthesis. This damage produces severe and significant CLBP or vertebrogenic anterior column pain.

Older patients with variations of ASD were excluded from the clinical trials, failing the strict inclusion criteria (CLBP without deformity, i.e., no scoliosis or spondylolisthesis or osteopenia). The rationale for the BVNA treatment of patients with ASD and CLBP is that VEP damage and DD are frequently present in an increased number of levels in patients with ASD. Lumbar instrumented fusion to control pain and deformity is the

ultimate surgical treatment for this group. The hypothesis of this case review is that with these older patients, BVNA, a minimally invasive outpatient treatment, could improve CLBP in patients previously indicated for a lumbar fusion, delaying the need for the fusion operation. Would elderly patients get CLBP relief and improvement of daily activities with BVNA? This review demonstrates the effectiveness and durability of BVNA as a treatment tool to consider before proceeding with lumbar fusion in the treatment of elderly patients with ASD and vertebrogenic CLBP in community spine practice.

Clinical trials of BVNA treatment of CLBP proved success and durability for pain relief and daily activities. This is new information about BVNA for older patients with spinal deformities and other comorbidities. This study could impact research practice and policy to expand indications of BVNA to adult spinal deformity.

METHODS

This was a consecutive case series performed by 1 surgeon (G.F.). Retrospectively, this series was divided into a collection of patients with minimal comorbidities (Group A) and those with significant comorbidities (Group B). Patients were separated by their comorbidities to compare to results from previously published clinical trials.

Visual analog scale (VAS 10 cm) and Oswestry Disability Index (ODI 100-point scale) were used as measures of pain relief and function before BVNA and at the time of the last follow-up (LFU). For the ODI and VAS, published guidelines were used.^{26,27} Higher scores indicate more pain and disability. The ODI percentages are grouped into categories: (1) 0% to 20%, minimal disability; (2) 21% to 40%, moderate disability; (3) 41% to 60%, severe disability; (4) 61% to 80%, crippling disability; (5) 81% to 100%, bed bound or exaggeration of symptoms. The VAS score is an 11-point scale between “no pain” (0) and the highest score (10) indicating “greater pain intensity.”

Inclusion Criteria

Inclusion criteria were vertebrogenic CLBP for more than 6 months with MRI Modic type 1 and/or 2 changes. Exclusion criteria were severe pulmonary or cardiac disease or local or systemic infection. Patients with posterior column or facet joint symptoms associated with findings consistent with facet joint inflammation or effusion were treated separately with facet

injection and/or ablation and were also excluded in this series. However, patients were not excluded for treated osteoporosis, lumbar stenosis, lumbar scoliosis, or spondylolisthesis.

The authors subdivided these series into 2 groups based on the number of comorbidities. Group A comprised patients with minimal comorbidities that would compare readily with the clinical trials; no patient had comorbidities other than scoliosis and spondylolisthesis and did not require additional surgery. Group B consisted of patients with additional comorbidities, including lumbar stenosis, radiculopathy, polyneuropathy, osteoporotic fracture, previous fusion surgery, mobile spondylolisthesis with instability, previous sacroiliac (SI) joint fusion, and other medical comorbidities such as chronic renal failure and Parkinson’s disease. These 2 groups were compared and reported separately. Laminotomy or laminectomy was offered along with BVNA for patients with stenosis and/or radiculopathy. In some cases, insurance authorized a laminectomy several months sooner, which was performed separately and was followed by the BVNA when approved.

Identification of Levels to Be Included in the BVNA

In those patients who met medical and clinical inclusion criteria, lumbar MRIs were evaluated at each level from L2 to S1 for Modic 1 and/or 2 changes associated with degenerative disc disease. These segmental levels of the lumbar spine were included in the BVNA. Many of these patients with ASD were lumbar fusion candidates meeting surgical criteria of pain and disability and failure of conservative treatment. BVNA was offered as an alternative to be performed before consideration of lumbar fusion.

Surgical Procedure BVNA

BVNA was performed on 118 consecutive patients by a single surgeon (G.F.) utilizing the Intracept device (Relieva MedSystems Inc./Boston Scientific Edina, MN, USA) as previously described by Fischgrund et al.¹⁴ The BVNA procedures were completed between October 2020 and May 2023.

The procedure was performed unilaterally at each segment with the patient in a prone position on a spinal frame with general anesthesia. Using standard anatomical landmarks and fluoroscopic guidance, an introducer cannula is advanced via a transpedicular approach through the posterior vertebral body and curved to the midline in the vertebral body near the posterior and central BVN. A bipolar radio frequency probe was then

Table 1. Demographics of study participants.

Demographics	Group A (n = 41)	Group B (n = 77)
Women, n (%)	18	44
Men, n (%)	23	33
Age, y, mean (range)	68 (40–90)	71 (43–88)
Working before BVNA	12	18
CLBP \geq 2 y	41 (100%)	74 (96%)
Opioid use, preoperative	9 (22%)	9 (11%)
VAS score, preoperative, mean (range)	9 (5–10)	9 (7–10)
ODI score, preoperative, mean (range)	53 (32–78)	58 (19–80)

Abbreviations: BVNA, basivertebral nerve ablation; CLBP, chronic low back pain; ODI, Oswestry Disability Index; VAS, visual analog scale.

placed and positioned to ablate the BVN. If targeted accurately, the current recommendation is a 7.5-minute radiofrequency ablation at 85°C, and if targeting was not within 3 mm, then the treatment time was increased to 15 minutes.

Opioid Usage

Opioid usage was based on Board of Pharmacy records available with the electronic record of each patient.

RESULTS

Demographics

There were 41 patients in Group A without significant comorbidities and 77 in Group B with comorbidities as were previously described. The duration of vertebrogenic CLBP was more than 2 years in almost every patient (Table 1). The average age was 70 with nonsignificant differences in the distribution of men and women. All patients had some type of previous treatment, including home exercises, application of heat and/or cold, physical therapy, and spinal injections (including interlaminar and transforaminal epidural injections and facet injections). Opioid usage before the BVNA was 22% in Group A and 53% in Group B. The preoperative VAS was 9 on average in both groups. The initial ODI was higher in Group B with an average of 60 but with scores ranging up to 80 (Table 1).

Imaging Review

Imaging was reviewed on the picture archiving and communication system. Spinal x-rays demonstrated a similar incidence of scoliosis (ASD) in both groups. Spondylolisthesis (ASD) without instability was in Group A, while mobile spondylolisthesis was common (40%) in Group B (Figure 1, Figure 2, and Table 2). Spinal stenosis was present in both groups, but stenosis requiring surgical treatment was only in Group B.

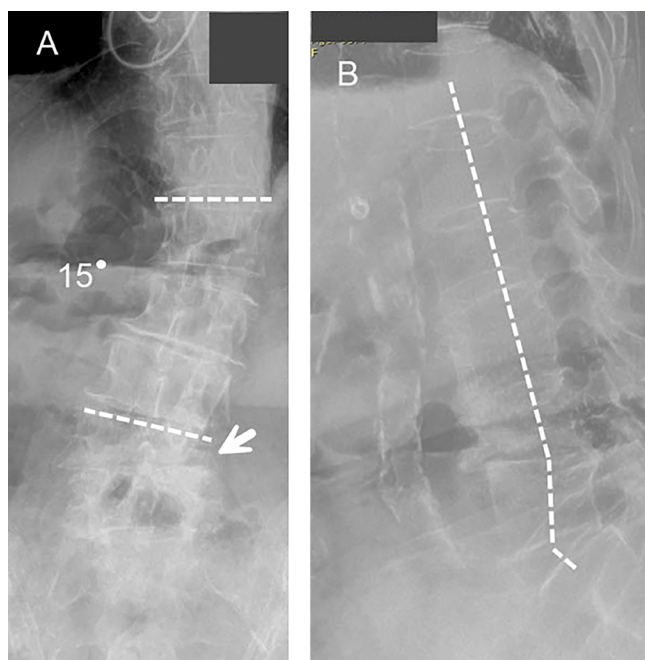


Figure 1. Anteroposterior (A) and lateral (B) conventional radiographs of the lumbar spine taken in a 73-year-old patient with a 15° lumbar scoliosis (A; white lines Cobb angle measurement) and L4–L5 lateral spondylolisthesis (white arrow). (B) Loss of lumbar lordosis (white line). After basivertebral nerve ablation L1–S1 with previous laminectomy. The patient had good improvement of Oswestry Disability Index (60 points) to 24 points (moderate disability of daily activities) and VAS (6 cm) to 2 cm at the last follow-up.

Radiographic evidence of previous laminectomy was noted in approximately 20% in each group. Significant lumbar sagittal imbalance with pain and disability with daily activities and anatomic changes of a decreased lumbar lordosis with a fixed postural flexion was seen in 12 patients overall, and was symptomatic in 9 patients, all included in Group B. Patients with previous fusions in 10 were included in Group B. Primary osteopenia or osteoporosis was noted in 60 patients (52%) overall and was contemporaneously treated with medications such as bisphosphonates or teriperitide. Previous vertebroplasty was seen in 1 patient from each group. Schmorl's nodes (Figure 3) and hemangiomas were evenly distributed in both groups,

BVNA

Five hundred three levels of BVNA equally distributed between 2 groups (mean 4 levels) were performed in 118 patients (Table 3). General anesthetic with intubation was used for all patients. The L2 level was included in 57 patients (17 patients in Group A and 40 patients in Group B). In Group B, laminotomy or laminectomy was indicated for severe stenosis with claudication and radiculopathy and was done at the time of the BVNA in 28 patients (24%) and separately before the BVNA in 12 (10%) at a mean of 100 days (range 77–407 days).

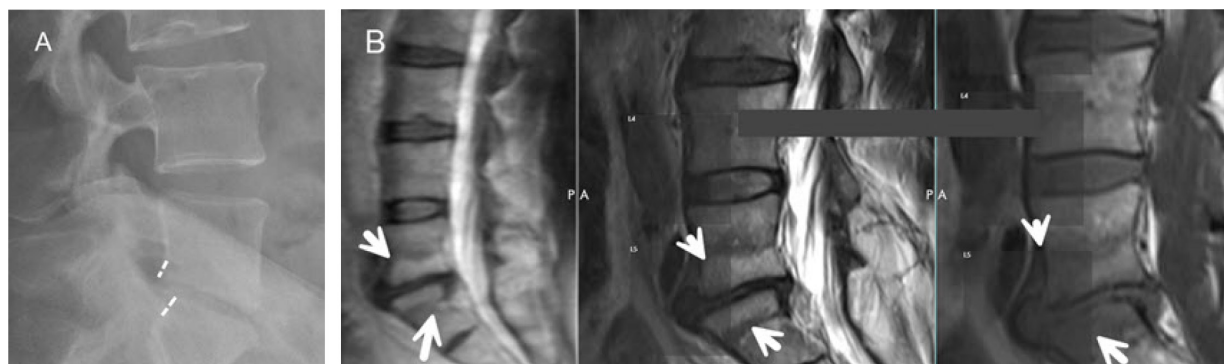


Figure 2. (A) Lateral x-ray retrolisthesis with disc narrowing seen at L5–S1 in 42-year-old nurse. (B) Sagittal T2-weighted, short T1 inversion recovery, and T1 weighted magnetic resonance images show Modic 1 changes of L5 and S1 with moderate-severe disc degeneration. This spondylolisthesis without pars defect responded well to basivertebral nerve ablation. The preoperative visual analog scale score of 8 cm improved to 1 cm and Oswestry Disability Index improved from 52 to 10 points.

Opioid usage was diminished by 50% in both groups at LFU. Group A VAS at LFU was an average of 2.0 cm, a 7.0 cm improvement. Group B VAS at LFU was 3.0 cm, a 6.0 cm improvement. The Group A ODI mean was 14 points, or minimal disability, with a 39-point improvement, and Group B improved 28 points to 29 but remained moderately disabled. Fusion recommendations dropped nearly 50% following BVNA. Fusions were likely to be required at only 1 level rather than multiple levels as recommended prior to the BVNA.

Complications

At LFU, the number of complications was significantly different in the 2 groups. In Group A, there were 5 patients (12%) with SI joint pain and continued anterior column nonspecific CLBP in 1 patient. There was 1 revision BVNA that resulted in improved VAS and ODI (Table 4).

In Group B, there were 22 patients (27%) with continued symptoms related to spinal stenosis, radiculopathy, SI joint pain, and facet pain. Nonspecific CLBP was seen in 15 patients (19%) and attributed to mobile spondylolisthesis. Lumbar fusion was recommended in 17 patients (22%) with incomplete pain relief from BVNA, all in Group B. Nine of those had symptomatic mobile spondylolisthesis. One revision BVNA was

unsuccessful with the patient experiencing continued CLBP. There were 9 vertebral compression fractures (VCFs) after BVNA in Group B discussed below.

Subgroup B After BVNA

Adjacent to Fusion

BVNA done at levels adjacent to a previous fusion subgroup showed a 7-cm improvement of VAS pain and a 16-point improvement of ODI daily activity disability, but patients remained moderately disabled as determined by the ODI.

Sagittal Imbalance

The group with sagittal imbalance had a substantial improvement in VAS and a 40-point improvement of ODI to minimal or lowest moderate disability. None of the patients with sagittal imbalance had a subsequent lumbar osteotomy at the time of this writing.

Laminectomy

At LFU, the laminectomy group had mean VAS 2.0 cm and 28-point ODI improvement but remained on average at 21 points with a final low moderate disability. Twelve laminectomies were done at the same time as the BVNA, 12 were done separately prior to the BVNA, and 2 were done after the BVNA 3 months later.

Laminectomy Complications

At LFU, the laminectomy patients had continued posterior column pain related to radiculopathy and/or peripheral neuropathy in 30%. Three had SI joint pain and 1 underwent sacroiliac joint fusion. In addition, 1 lumbar fusion was performed.

Table 2. Imaging review.

Adult Spinal Deformity	Group A, n (%)	Group B, n (%)
Scoliosis	33 (80)	54 (70)
Severe scoliosis (>20°)	2 (5)	4 (5)
Loss of sagittal balance	3 (7)	9 (12)
Spondylolisthesis	39 (95)	54 (70)
Spondylolisthesis + mobility	0	22 (29)
Stenosis	12 (29)	33 (43)
Previous laminectomy	7 (17)	17 (22)
Previous fusion	0	10 (13)
Previous vertebroplasty	1 (2)	1 (1)

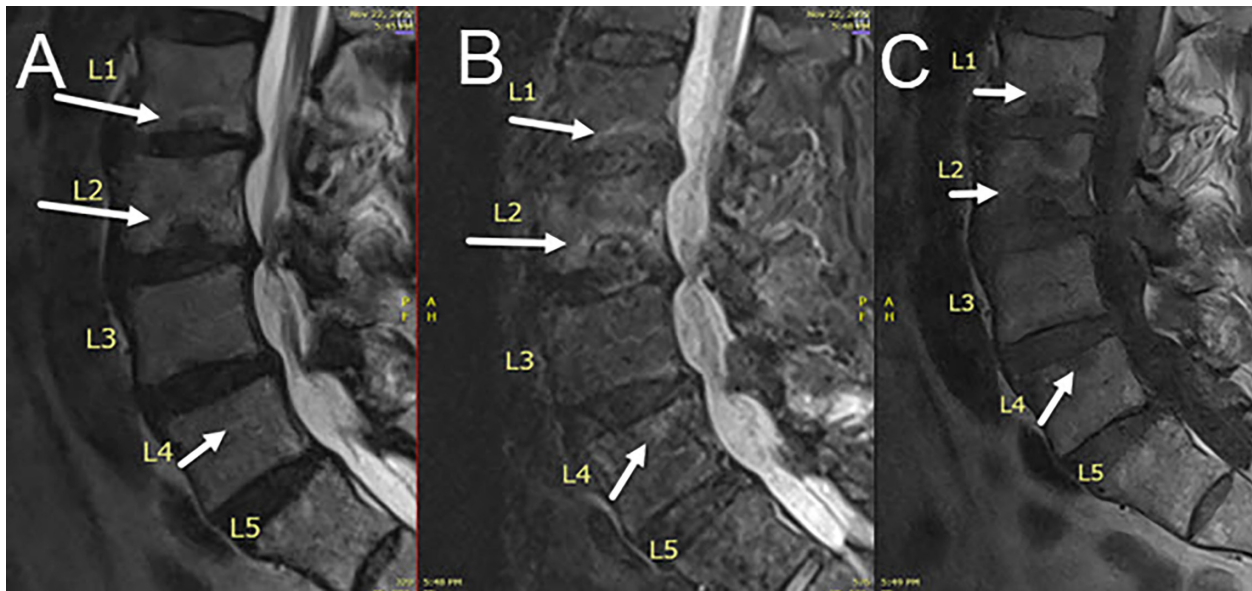


Figure 3. Sagittal T2-weighted (A), short TI inversion recovery (B), and sagittal T1 weighted (C) magnetic resonance images of a patient with old injury from parachuting. Panels A, B, and C show Modic 1 and Modic 2 changes around Schmorl's nodes at L1–L4 (white arrows at each VEP disruption). After basivertebral nerve ablation L1–L5, the visual analog scale improved 8 cm to 0 and the Oswestry Disability Index improved 40 points from 52 to 10 at the last follow-up.

Declined Laminectomy

Five patients declined laminectomy surgery and opted for the BVNA alone with continued severe stenosis, radiculopathy, and neuroclaudication symptoms that should be decompressed for the most optimal pain relief. Three of the 5 patients with untreated stenosis improved with VAS of 2 and an ODI average of 20 points, but 2 remained severely disabled with an ODI >50. One of these patients had a diagnosis of polyneuropathy, and the other had significant comorbidities of osteoporosis and Parkinson's disease.

Pedicle Screw Removal

Pedicle screws were removed to allow pedicular access adjacent to a previous interbody fusion in 6 patients (5%). One pedicle screw tract could not be cannulated to approach the BVN. That patient declined revision BVNA and remained moderately disabled (Table 5).

Table 3. Post-BVNA results.

After BVNA	Group A	Group B
Total No. of BVNA levels	167	336
L2 level included, <i>n</i>	17	40
Opioid use at LFU, <i>n</i> (%)	5 (12%)	15 (20%)
Fusion recommended after BVNA, <i>n</i> (%)	0	17 (22%)
VAS score at LFU, mean (range)	2 (0–5)	3 (0–10)
ODI score at LFU, mean (range)	14 (0–52)	29 (0–78)
Interval to LFU, d, mean (range)	261 (11–844)	300 (6–783)

Abbreviations: BVNA, basivertebral nerve ablation; LFU, last follow-up; ODI, Oswestry Disability Index; VAS, visual analog scale.

Mobile Spondylolisthesis

Mobile spondylolisthesis grades 2 to 3 with >5 mm instability were seen in 21 patients in Group B. At LFU, there was a 6.0 cm improvement of VAS, and this group had a 25-point improvement in ODI but remained moderately disabled. At LFU, in the mobile spondylolisthesis group, there was a 20% incidence of spinal stenosis and radiculopathy symptoms. Lumbar fusion was recommended in patients with failed pain and disability relief after BVNA in 22 patients, 9 with significant mobile grade 2 or grade 3 spondylolisthesis. Two of the 3 revision BVNA procedures failed in this mobile spondylolisthesis group.

Table 4. Complications.

Complications	Group A	Group B
Posterior column pain (radiculopathy, facet, sacroiliac joint, and hip)	5 (12)	21 (27)
Nonspecific CLBP	1 (2)	15 (19)
Stenosis radiculopathy peripheral neuropathy	2 (5)	22 (28)
SI joint pain	0	8 (10)
SI fusion performed	0	2 (3)
VCF fragility fracture	0	9 (13)
Fusion recommended	0	17 (22)
Fusion performed	0	1 (1)
Revision BVNA	1 (2)	1 (1)
Failed revision BVNA	0	1 (1)

Abbreviations: BVNA, basivertebral nerve ablation; CLBP, chronic low back pain; VCF, vertebral compression fracture.

Table 5. Results in Group B subgroups.

Subgroups in Group B	n	VAS Score, Preoperative	VAS Score, LFU	ODI Score, Preoperative	ODI Score, Postoperative	LFU, d
Adjacent to previous fusion	12	9	2	41	25	309
Sagittal imbalance	9	9	3	62	19	125
Laminectomy	26	9	2	52	21	283
Fusion recommended after BVNA	22	9	4	64	37	300
Removal pedicle screws	5	9	3	57	29	183
Mobile spondylolisthesis	21	9	3	55	28	264
Osteoporotic fracture VCF	8	10	4	65	47	370

Abbreviations: BVNA, basivertebral nerve ablation; LFU, last follow-up; ODI, Oswestry Disability Index; VAS, visual analog scale; VCF, vertebral compression fracture.
 Note: VAS, ODI, and LFU data are presented as means. VAS was measured on a 10-cm scale. ODI was measured on a 100-point scale.

BVNA Targeting

After BVNA, 5 patients had continued vertebrogenic pain, and new MRI examinations showed BVNA levels that may have been targeted less than perfectly. Three had revision BVNA of the involved levels, but only 1 patient improved, leaving 2 with continued CLBP. The other 2 were denied by insurance for revision BVNA, and both had continued CLBP. These patients with inadequate targeting during the BVNA had continued moderate disability on ODI.

Osteoporotic Vertebral Compression Fracture

VCFs after BVNA occurred in 9 patients (10%) in Group B. These patients were older (mean age of 78 years), and all had significant osteoporosis. Eight of the 9 patients had VCF within the area of the BVNA, and 1 had a seemingly unrelated S2 sacral insufficiency fracture. One VCF involved an endplate adjacent to a fused level, with a superior endplate subsidence below an interbody fusion cage. These VCF patients were treated with vertebroplasty or kyphoplasty, and all had follow-up medication therapy with teriparatide. At LFU, the VCF group (8 fractures at vertebral levels with prior BVNA) had a 6.0-cm improvement in VAS to 4.0 cm and continued significant and almost severe moderate disability with an mean ODI of 38.

DISCUSSION

We report BVNA treatment of vertebrogenic CLBP in patients in a community spinal surgery practice. Adult spinal deformities, which are common in community spinal surgery practices, would not meet inclusion criteria for the initial Level I randomized controlled trials performed comparing BVNA to sham treatment and to patients undergoing conservative treatment. There was a subset of this case review (Group A) that had ASD without other comorbidities that could meet the inclusion criteria for the clinical trials and could act as a comparison group to the subjects within the early

clinical trials. Interestingly, despite the spinal deformity diagnoses and the more advanced age, group A showed VAS and ODI had similar improvements in durable pain relief and minimal disability of daily activities.

Group B, with more comorbidities, had almost all the complications, increased opioid usage, and less success in regard to the improvements in VAS and ODI, with this group lagging behind Group A. By separating the group with significant comorbidities, the differences in outcomes between the 2 groups are more visible. Certainly, comorbidities can worsen outcomes, but even the worst patient results in Group B did show improvements in ODI and VAS scores.

The patients most likely to fail BVNA and require a lumbar fusion for CLBP were the cases with mobile spondylolisthesis and significant instability (>5 mm). Patients with spondylolisthesis, segmental rotational deformity, and scoliosis will respond to BVNA, but success may be limited with significant instability. However, CLBP with fixed spondylolisthesis did improve significantly with BVNA.

Patients receiving osteoporosis treatment with parathyroid hormone analogs may be deriving relief of their CLBP partially from the medication. The osteoporotic patients with fractures showed some improvement in pain and disability at LFU but, on average, remained moderately disabled.

Patients with loss of sagittal balance had significant relief of their CLBP and improvement of ODI to the level of minimal disability. Based on the results of this series, the vertebrogenic CLBP related to the loss of sagittal balance may be improved with BVNA without any change to the sagittal balance.

Several additional points may be made:

1. Pre-existing osteopenia or osteoporosis should be treated in advance of BVNA to optimize the patient's bone strength and decrease the risk of osteoporotic vertebral compression fracture.²⁸ The assessment and treatment of patients with

early VCFs following BVNA in this series have been recently reported.²⁹ These VCF patients were older (mean age 78 years), and advanced age is a very likely contributor to this higher prevalence of VCFs.

2. Failure of BVNA to give pain relief may predict those that require fusion. Also, by improving the degree of pain and functional improvement of adjacent segments, BVNA may limit the extent of lumbar fusion ultimately required. In addition, the fusion was most likely to be indicated, especially in cases of mobile spondylolisthesis. In the presence of significant mobile spondylolisthesis, lumbar fusion should be recommended.
3. Sagittal imbalance is a general description of spinal deformities that include a significant anteriorly directed postural instability usually due to a decrease in the normal amount of lumbar lordosis. This sagittal imbalance may be associated with severe CLBP. Correction is surgical, generally with instrumentation and osteotomy. BVNA may be helpful for back pain but will not correct the sagittal imbalance spinal deformity. An example of a good result in sagittal imbalance with pain and disability improvement after BVNA is seen in Figure 4.
4. Schmorl's nodes cause VEP damage and respond to BVNA³⁰ (Figure 3). Hemangiomas around the area of targeting do not seem to interfere and should not preclude BVNA.
5. Removal of pedicle screws to gain pedicular access usually leads to a conventional BVNA, but occasionally, the Jamshidi needle may deflect out of position. Troubleshooting, as a result of an erroneous trajectory, may be done by an extrapedicular approach.³¹ At the sacrum, a lateral approach to S1 through the iliac under fluoroscopic guidance is a low-risk approach, as is done with a lateral approach to a minimally invasive lateral SI joint fusion. The lateral approach to the BVN can be done when the standard transpedicular approach is too difficult related to overhanging of the posterior iliac crest or the presence of a previous sacral pedicle screw.³² Every case requiring pedicle screw removal has at least 1 VEP involved in fusion that should be treated by BVNA.
6. Most pacemakers nowadays do not need adjustment, but 1 may turn the device off for the procedure when possible. A cardiologist should always be consulted to ensure that the patient

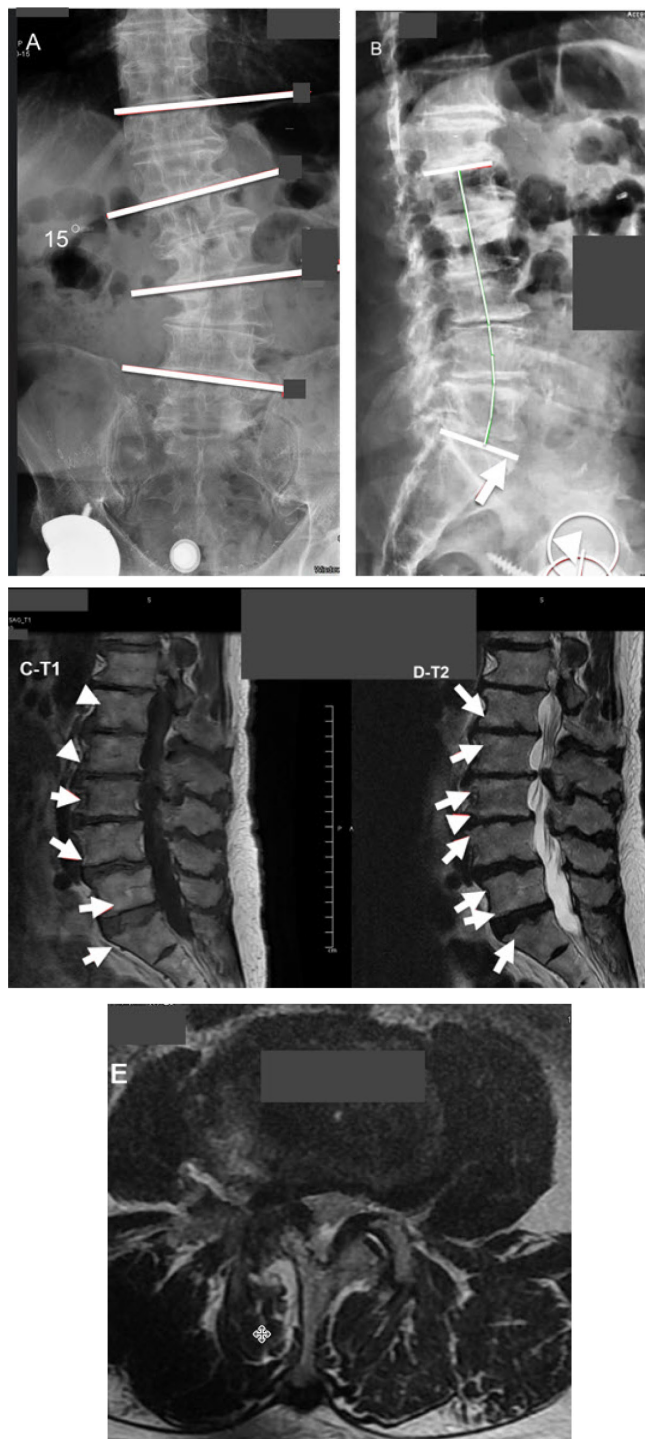


Figure 4. Anteroposterior (A) and lateral (B) conventional radiographs of the lumbar spine taken in a 79-year-old patient (A) with a 15° lumbar scoliosis (white lines Cobb angle measurement). (B) Sagittal imbalance with loss of lumbar lordosis (white curved line; pelvic tilt [PT] = 37, pelvic incidence [PI] = 54.4, PI-L1 = 30.7). (C) sagittal T1 and (D) T2-weighted magnetic resonance images of same patient show Modic 1 and Modic 2 changes around Schmorl's nodes vertebral endplate (VEP) damage at L1-L4 (white arrows at each VEP disruption in panels C and D). (E) T2-weighted axial image shows severe central and foraminal stenosis. This patient refused corrective subtraction osteotomy or laminectomy. After basivertebral nerve ablation (BVNA) L2-S1, VAS improved 9 cm (from 10 to 1) and Oswestry Disability Index improved 58 points (from 70 to 12) at the last follow-up. The patient was very satisfied with the BVNA result and said he would not do an osteotomy.

is not pacemaker dependent prior to turning off the device. Another common precaution is that spinal cord stimulation devices should be placed in “surgery mode” before any radiofrequency ablation. The batteries from any implantable pulse generator act as an energy sink, and energy delivered externally may cause overheating of the electrodes. Under anesthesia, the heat may cause serious burn injury to any neural tissue near the stimulator wires.

7. Single-photon emission computed tomography (SPECT)-computed tomography was used when a patient could not have an MRI. Bone SPECT highlights areas of active bone turnover, and since Modic type 1 (M1) represents inflammation and increased bone turnover edema, it shows up. Modic type 2 (M2) is fatty replacement of the marrow and also has increased bone turnover albeit less bone turnover in type 1 changes. Given these characteristics, bone SPECT tends to increased radiotracer uptake with either M1 or M2.^{33–35}

Limitations

Limitations of this case series include the short follow-up and incomplete ODI data.

The variety of diagnoses associated with ASD, including spinal stenosis, radiculopathy, and osteoporosis, can produce symptoms of anterior as well as posterior column back and leg pain that sometimes may be like those caused by vertebrogenic back pain. Segregation of the comorbidities may have been helpful to show that the outcomes were diminished by the comorbidities but not directly related to the ASD or the BVNA procedure. This separation of the patients by comorbidities does not have definitive supportive data in the literature.

Decompressive laminectomy for spinal stenosis-related pain done in conjunction with BVNA for vertebrogenic pain may make it difficult to tell which procedure provided the most relief. However, in the laminectomy group at LFU, there were 8 (31%) with persistent pain due to radiculopathy or peripheral neuropathy and only 1 patient who had anterior column pain and was successfully treated with a revision BVNA.

The medical treatment of osteoporosis with parathyroid hormone analogs is said to improve CLBP in patients with osteoporosis and may change the outcome of patients with VCF after BVNA.

CONCLUSION

Clinical trials of BVNA treatment of CLBP have shown success in the reduction of pain and the improvement of disability, and these improvements were shown to be durable for more than 5 years. Patients with ASD without comorbidities showed durable pain relief of vertebrogenic CLBP and return of daily activities, like the clinical trials. In those with comorbidities, the result was an improvement in pain and disability; however, the result could be diminished by the complications related to the comorbidities. This is new information regarding the successful treatment of older patients with spinal deformities and several comorbidities with BVNA. This study could impact additional research and could expand indications of BVNA to include these types of patients.

REFERENCES

1. Hoy D, Bain C, Williams G, et al. A systematic review of the global prevalence of low back pain. *Arthritis Rheum.* 2012;64(6):2028–2037. doi:10.1002/art.34347
2. Lorio M, Clerk-Lamallice O, Beall DP, Julien T. International Society for the Advancement of Spine Surgery guideline-intraosseous ablation of the basivertebral nerve for the relief of chronic low back pain. *Int J Spine Surg.* 2020;14(1):18–25. doi:10.14444/7002
3. Cheung KMC, Karppinen J, Chan D, et al. Prevalence and pattern of lumbar magnetic resonance imaging changes in a population study of one thousand forty-three individuals. *Spine.* 2009;34(9):934–940. doi:10.1097/BRS.0b013e3181a01b3f
4. Luoma K, Riihimäki H, Luukkonen R, Raininko R, Viikari-Juntura E, Lamminen A. Low back pain in relation to lumbar disc degeneration. *Spine.* 2000;25(4):487–492. doi:10.1097/00007632-200002150-00016
5. Dudli S, Fields AJ, Samartzis D, Karppinen J, Lotz JC. Pathobiology of modic changes. *Eur Spine J.* 2016;25(11):3723–3734. doi:10.1007/s00586-016-4459-7
6. Dudli S, Sing DC, Hu SS, et al. ISSLS PRIZE IN BASIC SCIENCE 2017: intervertebral disc/bone marrow cross-talk with modic changes. *Eur Spine J.* 2017;26(5):1362–1373. doi:10.1007/s00586-017-4955-4
7. Modic MT, Steinberg PM, Ross JS, Masaryk TJ, Carter JR. Degenerative disk disease: assessment of changes in vertebral body marrow with MR imaging. *Radiology.* 1988;166(1 Pt 1):193–199. doi:10.1148/radiology.166.1.3336678
8. Conger A, Smuck M, Truumees E, Lotz JC, DePalma MJ, McCormick ZL. Vertebrogenic pain: a paradigm shift in diagnosis and treatment of axial low back pain. *Pain Med.* 2022;23(Supplement_2):S63–S71. doi:10.1093/pm/pnac081
9. Kjaer P, Korsholm L, Bendix T, Sorensen JS, Leboeuf-Yde C. Modic changes and their associations with clinical findings. *Eur Spine J.* 2006;15(9):1312–1319. doi:10.1007/s00586-006-0185-x
10. McCormick ZL. Vertebrogenic pain: a phenomenon driving new understanding of chronic axial low back pain. *Pain Med.* 2022;23(Suppl 2):S1. doi:10.1093/pm/pnac051
11. McCormick ZL, Conger A, Smuck M, et al. Magnetic resonance imaging characteristics associated with treatment

success from basivertebral nerve ablation: an aggregated cohort study of multicenter prospective clinical trials data. *Pain Med.* 2022;23(Suppl 2):S34–S49. doi:10.1093/pm/pnac093

12. McCormick ZL, Sperry BP, Boody BS, et al. Pain location and exacerbating activities associated with treatment success following basivertebral nerve ablation: an aggregated cohort study of multicenter prospective clinical trial data. *Pain Med.* 2022;23(Supplement_2):S14–S33. doi:10.1093/pm/pnac069

13. DePalma MJ, Ketchum JM, Saullo TR. Multivariable analyses of the relationships between age, gender, and body mass index and the source of chronic low back pain. *Pain Med.* 2012;13(4):498–506. doi:10.1111/j.1526-4637.2012.01339.x

14. Fischgrund JS, Rhyne A, Franke J, et al. Intraosseous basivertebral nerve ablation for the treatment of chronic low back pain: a prospective randomized double-blind sham-controlled multicenter study. *Eur Spine J.* 2018;27(5):1146–1156. doi:10.1007/s00586-018-5496-1

15. Fischgrund JS, Rhyne A, Franke J, et al. Intraosseous basivertebral nerve ablation for the treatment of chronic low back pain: 2-year results from a prospective randomized double-blind sham-controlled multicenter study. *Int J Spine Surg.* 2019;13(2):110–119. doi:10.14444/6015

16. Fischgrund JS, Rhyne A, Macadaeg K, et al. Long-term outcomes following intraosseous basivertebral nerve ablation for the treatment of chronic low back pain: 5-year treatment arm results from a prospective randomized double-blind sham-controlled multicenter study. *Eur Spine J.* 2020;29(8):1925–1934. doi:10.1007/s00586-020-06448-x

17. Truumees E, Macadaeg K, Pena E, et al. A prospective, open-label, single-arm, multi-center study of intraosseous basivertebral nerve ablation for the treatment of chronic low back pain. *Eur Spine J.* 2019;28(7):1594–1602. doi:10.1007/s00586-019-05995-2

18. Becker S, Hadjipavlou A, Heggeness MH. Ablation of the basivertebral nerve for treatment of back pain: a clinical study. *Spine J.* 2017;17(2):218–223. doi:10.1016/j.spinee.2016.08.032

19. Khalil JG, Smuck M, Koreckij T, et al. A prospective, randomized, multicenter study of intraosseous basivertebral nerve ablation for the treatment of chronic low back pain. *Spine J.* 2019;19(10):1620–1632. doi:10.1016/j.spinee.2019.05.598

20. Koreckij T, Kreiner S, Khalil JG, et al. Prospective, randomized, multicenter study of intraosseous basivertebral nerve ablation for the treatment of chronic low back pain: 24-month treatment arm results. *N Am Spine Soc J.* 2021;8:100089. doi:10.1016/j.xnsj.2021.100089

21. Clerk-Lamallice O, Beall DP, Ong K, Lorio MP. ISASS policy 2018-vertebral augmentation: coverage indications, limitations, and/or medical necessity. *Int J Spine Surg.* 2019;13(1):1–10. doi:10.14444/5096

22. Conger A, Burnham TR, Clark T, Teramoto M, McCormick ZL. The effectiveness of intraosseous basivertebral nerve radiofrequency ablation for the treatment of vertebrogenic low back pain: an updated systematic review with single-arm meta-analysis. *Pain Med.* 2022;23(Suppl 2):S50–S62. doi:10.1093/pm/pnac070

23. Lorio M, Clerk-Lamallice O, Rivera M, Lewandrowski K-U. ISASS policy statement 2022: literature review of intraosseous basivertebral nerve ablation. *Int J Spine Surg.* 2022;16(6):1084–1094. doi:10.14444/8362

24. Nwosu M, Agyeman WY, Bisht A, et al. The effectiveness of intraosseous basivertebral nerve ablation in the treatment of nonradiating vertebrogenic pain: a systematic review. *Cureus.* 2023;15(4):e37114. doi:10.7759/cureus.37114

25. Sayed D, Naidu RK, Patel KV. JPR. 2022;15:2801–2819. doi:10.2147/JPR.S378544

26. Bjelkarøy MT, Benth JS, Simonsen TB, et al. Measuring pain intensity in older adults. can the visual analogue scale and the numeric rating scale be used interchangeably? *Prog Neuropsychopharmacol Biol Psychiatry.* 2024;130:110925. doi:10.1016/j.pnpbp.2023.110925

27. Koivunen K, Widbom-Kolhanen S, Perna K, Arokoski J, Saltychev M. Reliability and validity of Oswestry Disability Index among patients undergoing lumbar spinal surgery. *BMC Surg.* 2024;24(1):13. doi:10.1186/s12893-023-02307-w

28. Lehman RA, Kang DG, Wagner SC. Management of osteoporosis in spine surgery. *J Am Acad Orthop Surg.* 2015;23(4):253–263. doi:10.5435/JAAOS-D-14-00042

29. Fogel G, Musie J, Phillips TR, et al. Assessment and management of patients developing low energy vertebral compression fractures following basivertebral nerve ablation. *Pain Med.* 2024;25(3):249–251. doi:10.1093/pm/pnad132

30. Takatalo J, Karppinen J, Niinimäki J, et al. Association of modic changes, schmorl's nodes, spondylolytic defects, high-intensity zone lesions, disc herniations, and radial tears with low back symptom severity among young finnish adults. *Spine.* 2012;37(14):1231–1239. doi:10.1097/BRS.0b013e3182443855

31. Beall DP, Parsons B, Burner S. Technical strategies and anatomic considerations for an extrapedicular modified inferior endplate access to thoracic and lumbar vertebral bodies. *Pain Physician.* 2016;19(8):593–601.

32. Payne C, Jaffee S, Swink I, et al. Comparative analysis of the lateral and posterolateral trajectories for fixation of the sacroiliac joint-a cadaveric study. *J Orthop Surg Res.* 2020;15(1):489. doi:10.1186/s13018-020-02013-w

33. Weishaupt D, Zanetti M, Hodler J, et al. Painful lumbar disk derangement: relevance of endplate abnormalities at MR imaging. *Radiology.* 2001;218(2):420–427. doi:10.1148/radiology.218.2.r01fe15420

34. Tender GC, Davidson C, Shields J, et al. Primary pain generator identification by CT-SPECT in patients with degenerative spinal disease. *Neurosurg Focus.* 2019;47(6):E18. doi:10.3171/2019.9.FOCUS19608

35. Järvinen J, Niinimäki J, Karppinen J, Takalo R, Haapea M, Tervonen O. Does bone scintigraphy show modic changes associated with increased bone turnover? *Eur J Radiol Open.* 2020;7:100222. doi:10.1016/j.ejro.2020.100222

Funding: The authors received no financial support for the research, authorship, and/or publication of this article.

Declaration of Conflicting Interests: The authors report no conflicts of interest in this work.

Corresponding Author: Guy Fogel, Spinepain-begone Clinic, Edmond, OK, USA; gfogelmd@gmail.com

This manuscript is generously published free of charge by ISASS, the International Society for the Advancement of Spine Surgery. Copyright © 2024 ISASS. To see more or order reprints or permissions, see <http://ijssurgery.com>.