

Efficacy and Safety of Biportal Endoscopic Decompressive Laminectomy in Octogenarians With Severe Lumbar Spinal Stenosis

Sang-Min Park, John I. Shin, Jin-Ho Park, Jonghun Jung, Jiwon Park, Ho-Joong Kim, Jin S. Yeom and Hyun-Jin Park

Int J Spine Surg published online 26 September 2024
<https://www.ijssurgery.com/content/early/2024/09/25/8649>

This information is current as of September 28, 2024.

Email Alerts Receive free email-alerts when new articles cite this article. Sign up at:
<http://ijssurgery.com/alerts>

Efficacy and Safety of Biportal Endoscopic Decompressive Laminectomy in Octogenarians With Severe Lumbar Spinal Stenosis

SANG-MIN PARK, MD¹; JOHN I. SHIN, MD²; JIN-HO PARK, MD³; JONGHUN JUNG, MD⁴; JIWON PARK, MD⁵; HO-JOONG KIM, MD, PhD¹; JIN S. YEOM, MD, PhD¹; AND HYUN-JIN PARK, MD, PhD⁶

¹Spine Center and Department of Orthopedic Surgery, Seoul National University College of Medicine and Seoul National University Bundang Hospital, Seongnam, South Korea; ²Department of Orthopedic Surgery, Cooperman Barnabas Medical Center/Jersey City Medical Center—RWJBarnabas Health, Jersey, NJ, USA; ³Department of Orthopedic Surgery, Hallym University College of Medicine, Kangdong Sacred Heart Hospital, Seoul, South Korea; ⁴Department of Orthopedic Surgery, Healing Bone Orthopedic Clinic, Hanam, South Korea; ⁵Department of Orthopedics, Korea University Ansan Hospital, Ansan, South Korea; ⁶Department of Orthopedic Surgery, Spine Center, Hallym University College of Medicine, Kangnam Sacred Heart Hospital, Seoul, South Korea

ABSTRACT

Background: Lumbar spinal stenosis (LSS) is prevalent among octogenarians, causing significant pain and disability. Surgical intervention is often required because of the ineffectiveness of conservative treatments. This study investigates the efficacy and safety of biportal endoscopic decompressive laminectomy (BED) in octogenarians with severe LSS, evaluating its potential as a minimally invasive surgical option.

Methods: This retrospective study included 107 patients aged 80 years or older who underwent BED for LSS between March 2017 and December 2022. Data were collected from electronic medical records, including demographic information, clinical outcomes, and surgical details. Patients with fractures, infectious spondylitis, herniated discs, and follow-up less than 12 months were excluded. Clinical outcomes were assessed using the visual analog scale, Oswestry Disability Index, European Quality of Life-5 Dimensions, and painDETECT at baseline and at 3, 6, and 12 months after surgery.

Results: The mean age of the 107 patients was 84.1 years, with 59% being women. Significant improvements were observed in visual analog scale scores for lower back and lower extremities pain, Oswestry Disability Index, European Quality of Life-5 Dimensions, and painDETECT scores, indicating reduced pain, decreased disability, and enhanced quality of life. There were no significant differences in outcomes between patients aged 80 to 84 and those 85 or older. Surgery-related outcomes such as operation time, blood loss, and complications were similar in both age groups.

Conclusions: BED is a safe and effective treatment for LSS in octogenarians, providing significant pain relief and functional improvement. This minimally invasive technique is also viable for patients older than 85 years, without increased risk of complications, supporting its broader indications in managing LSS in the elderly.

Clinical Relevance: This study highlights the efficacy and safety of BED for LSS in octogenarians, demonstrating its potential to improve quality of life and function with low risks, making it a feasible option for elderly patients.

Level of Evidence: 4.

Endoscopic Minimally Invasive Surgery

Keywords: biportal endoscopy, laminectomy, old age, octogenarians, spinal stenosis

INTRODUCTION

Lumbar spinal stenosis (LSS) is significantly more prevalent in geriatric patients aged 80 years or older. The degenerative changes in the spine frequently result in substantial pain and disability for these patients.¹ Surgical intervention is often necessary to decompress the spinal canal, as conservative treatments, including physical therapy, medication, and injections, are often insufficient to provide adequate relief.^{2–4} Despite the inherent risks associated with their advanced age and comorbidities, decompressive laminectomy with fusion surgery provides significant pain relief and functional

improvement in geriatric patients.⁵ Nevertheless, carrying out complex procedures such as interbody fusion in geriatric patients is difficult due to the existence of other medical histories, such as osteoporosis, cardiovascular diseases, and other systemic comorbidities. These factors exacerbate the likelihood of perioperative complications and prolong the recovery process.⁶

Minimally invasive techniques, particularly endoscopic decompression surgeries, have been increasingly adopted in recent years and have demonstrated good clinical results.⁷ These procedures provide substantial advantages over conventional microscopic laminectomy, such as shorter hospital stays, faster

recovery periods, and reduced surgical damage.^{2,8,9} Endoscopic decompression has been demonstrated to yield comparable results to conventional open microscopic procedures, particularly in elderly patients.¹⁰ Recently, biportal endoscopic decompressive laminectomy (BED) has emerged as a minimally invasive surgical technique for treating LSS.¹¹⁻¹⁴ A BED technique for LSS resulted in favorable clinical outcomes, reduced pain, and shorter hospital stays.¹⁵ Additionally, different minimally invasive decompressive surgeries for lumbar central stenosis were compared, including biportal endoscopy, uniportal endoscopy, and microsurgery, demonstrating the efficacy of biportal endoscopic approaches.¹⁶

This investigation aims to assess the efficacy and safety of BED in patients aged 80 and older, determining its feasibility as a favored surgical option for LSS. This research looks at the potential to improve the quality of life (QOL) for geriatric patients with LSS by investigating minimally invasive spine surgery techniques that address the specific challenges of advanced age.

MATERIALS AND METHODS

Study Design and Patient Demographics

The design and protocol of this retrospective case series study were approved by the institutional review board at our hospital (B-2309-853-103). This study is a retrospective analysis of patients aged 80 years or older who underwent BED for LSS. The study was conducted at our institution from March 2017 to December 2022. The data were collected from electronic medical records and included patients' demographic information, clinical outcomes, and surgical details.

We included patients who underwent BED for LSS aged 80 years or older. All patients had severe central canal stenosis classified as Schizas grades C or D. The exclusion criteria were as follow: fractures ($n = 14$), infectious spondylitis ($n = 16$), herniated intervertebral disc ($n = 1$), tethered cord syndrome ($n = 1$), thoracic myelopathy ($n = 9$), and less than 12-month follow-up or incomplete medical records during follow-up ($n = 21$).

After applying the exclusion criteria, 107 patients were included in the final analysis. The detailed demographic data and clinical outcomes of these patients were analyzed to assess the efficacy and safety of BED in this elderly population.

Surgical Procedures

The biportal endoscopic laminectomy technique is similar to microscopic decompressive laminectomy, with the main difference being the use of 2 portals.¹⁴ The surgery is performed with the patient in the prone position under general anesthesia. Using this procedure, enough working space is created for both the endoscope viewing portal and the working portal for the spinal instruments. The portals are located 0.5 and 1 cm lateral to the spinous process and are made under C-arm guidance. For a left-sided decompressive laminectomy, which is recommended for right-hand dominant surgeons, the working portal is located at the lower margin of the lamina with a 1-cm incision, while the viewing portal is positioned vertically 1 cm proximal to the working portal with a 7-mm incision. After making the skin incisions, the paraspinal muscles are detached from the lamina using a narrow Cobb elevator to create adequate working space. A 4-mm, 30° endoscope is inserted through the viewing portal under saline irrigation, maintained at a pressure of 30 to 40 mm Hg. Various instruments such as bipolar radiofrequency cautery, burr, Kerrison punch, and pituitary forceps are inserted through the working portal. Muscle and soft tissue debris are cleared using a shaver and bipolar radiofrequency cautery.

The laminectomy technique then proceeds similarly to microscopic laminectomy. A high-speed match-head burr is used to resect the ipsilateral lamina and spinous process base, creating space for instrument movement. An ipsilateral partial laminectomy is performed to facilitate ligamentum flavum (LF) detachment.

The ipsilateral lateral margin of the LF is identified with a Penfield dissector while resecting the hypertrophic facet joint medial margin. The LF is then split from the laminar undersurface to the lower laminar upper border and then removed by Kerrison punch or pituitary forceps. Using a dissector, the LF is detached from the contralateral lamina's undersurface. After removing the contralateral LF, the lateral margin of the dural sac and traversing root pathway are inspected to confirm sufficient decompression. This procedure is repeated at each affected level (Figure 1).

Outcome Assessment

Patient demographics, including body mass index, Charlson Comorbidity Index, and American Society of Anesthesiologists score, were recorded. Additionally, surgical details, such as the operated lumbar levels, operation time, blood loss, postoperative drainage, and length of hospital stay, were collected.

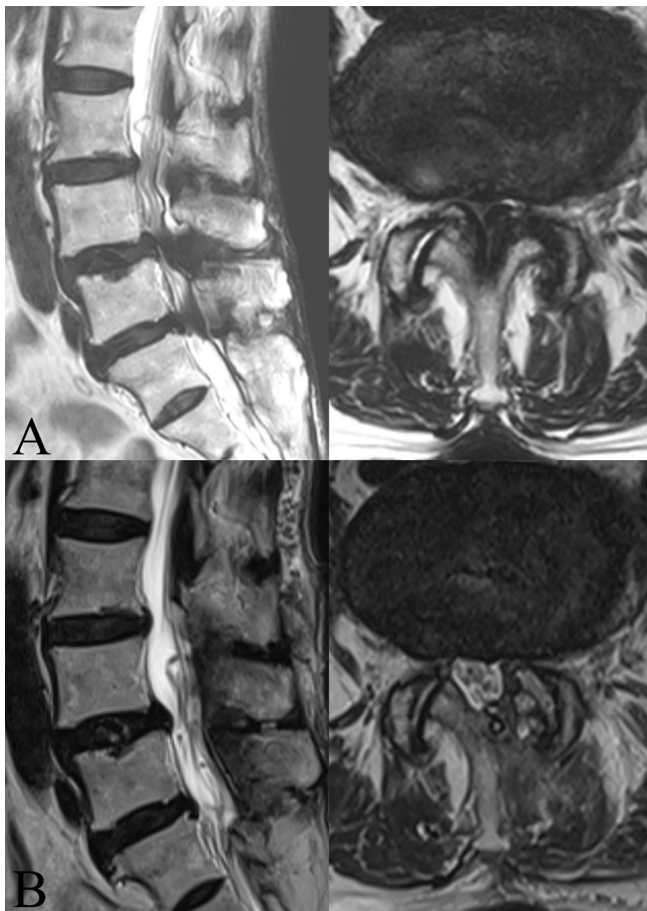

Figure 1. Biportal endoscopic decompressive laminectomy in a 92-year-old woman. (A) Magnetic resonance image (MRI) showing severe central canal stenosis at the L4–L5 and L5–S1 level and moderate central canal stenosis at the L3–L4 level. (B) Postoperative MRI showed fully decompressed dura after surgery.

Patient-reported outcome measures were evaluated at 4 time points: preoperative (baseline), and at 3, 6, and 12 months postsurgery. Clinical assessments included the visual analog scale (VAS) for low back pain and radiating pain in the lower extremities, the Oswestry Disability Index (ODI),¹⁷ the European Quality of Life-5 Dimensions (EQ-5D) score,¹⁸ and the painDETECT questionnaire.¹⁹

The VAS pain score was used to measure the intensity of low back pain and radiating pain in the lower extremities. The VAS pain score ranges from 0 (no pain) to 10 (severe pain), with higher scores indicating greater pain intensity. The ODI score was employed to assess the level of disability in daily activities due to low back pain. It provides a subjective percentage score, with higher scores reflecting greater disability. The ODI is a widely used tool for measuring the functional status of patients with spinal disorders. The EQ-5D score was utilized to evaluate the QOL of the patients. This measure includes 5 dimensions of health: mobility,

self-care, usual activities, pain/discomfort, and anxiety/depression. The EQ-5D index score is converted to a value ranging from -0.066 to 1.000 , with 1 indicating the best possible QOL. The painDETECT questionnaire was used to assess the presence and severity of neuropathic pain in the lower extremities. It consists of 9 questions, with a total score ranging from -1 to 38 points. A score below 12 suggests that neuropathic pain is unlikely, whereas a score above 19 indicates a high likelihood ($>90\%$) of neuropathic pain.

To evaluate clinical outcomes during follow-up, we analyzed serial changes in patient-reported outcome measures from the preoperative period to the final follow-up at 12 months postsurgery. The primary outcomes were the changes in these scores over time and the comparison of these changes between the 2 age groups (80–84 years [Group 1] vs 85 years and older [Group 2]).

Surgery-related outcomes, including total postoperative drainage (mL), operation duration (minutes), postoperative hospital stay (days), and intra- and postoperative complications, were thoroughly analyzed. Total postoperative drainage was quantified as the amount collected in the Hemovac (Zimmer Biomet, Warsaw, IN, USA) drain system up to the second postoperative day. Operation duration was documented from the time of skin incision to skin closure, as recorded in the anesthesia log.

Statistical Analysis

Descriptive statistics were used to summarize the demographic and clinical characteristics of the study population. Continuous variables were reported as means and SDs, while categorical variables were reported as frequencies and percentages. The study population was divided into 2 groups based on age. Group 1 included patients aged 80–84 years, and Group 2 included patients aged 85 years or older. Statistical comparisons between the 2 age groups were conducted to determine whether there were significant differences in baseline characteristics and outcomes. For continuous variables, independent samples *t* tests were used to compare means between the 2 groups. For categorical variables, χ^2 tests were used to compare proportions. To assess the impact of decompressive laminectomy on clinical outcomes, we analyzed changes in clinical outcomes over time. To account for the repeated measures within individuals and to analyze the effect of time and age group on clinical outcomes, we used Generalized Estimating Equations (GEE) with an exchangeable working correlation structure and Gaussian family.

Table 1. Demographic and clinical patient data.

Characteristic	N = 107
Men/women, n	44/63
Age, y mean (range)	84.1 (80–96)
Body mass index, mean (range)	24.5 (17.0–33.6)
CCI score, mean (range)	0.98 (0–5)
ASA score, mean (range)	2.41 (1–4)
Operated level, n (%)	
1-level	60 (56.1%)
2-level	33 (30.8%)
3-level	7 (6.5%)
4-level	6 (5.6%)
5-level	1 (0.9%)
Severity ^a (Schizas grade), n (%)	
C	32 (29.9%)
D	75 (70.1%)
Location, n (%)	
L1–L2	8 (4.6%)
L2–L3	25 (14.4%)
L3–L4	50 (28.7%)
L4–L5	80 (46.0%)
L5–S1	11 (6.3%)

Abbreviations: ASA, American Society of Anesthesiologists; CCI, Charlson Comorbidity Index.

^aMost severe level of operated segments.

The GEE models included the main effects of time and age group as well as their interaction terms to assess whether the change in clinical outcomes over time differed by age group. Stata/MP 17.1 (StataCorp LLC, College Station, Texas, USA) was used for all analyses. All statistical tests were 2-tailed, and results were considered statistically significant if $P < 0.05$.

RESULTS

Demographic Characteristics

The demographic and clinical characteristics of the study population are summarized in Table 1. A total of 107 patients aged 80 years or older who underwent decompressive laminectomy for spinal stenosis were included in the study. The mean age of the patients was 84.1 years. The majority of the patients were women (59%). The mean body mass index was 24.5, and the mean American Society of Anesthesiologists score was 2.41. The mean Charlson Comorbidity Index score was 0.98. The most common levels of surgery were L3 to L4 and L4 to L5.

Group Comparison Based on Age

The study population was divided into 2 groups based on age: Group 1 (aged 80–84 years) and Group 2 (aged 85 years or older). The demographic characteristics of the 2 groups are compared in Table 2. Statistical comparisons between the 2 age groups revealed no significant differences in most baseline characteristics.

Table 2. Clinical characteristics according to age.

Characteristic	Group 1, Age ≥85 y (n = 65)	Group 2, Age <85 y (n = 65)	P
Men/women, n	41/24	22/20	0.27
Age, y, mean (SD)	81.8 (1.6)	87.7 (3.1)	<0.001
Body mass index, mean (SD)	24.5 (3.4)	24.4 (2.9)	0.82
CCI score, mean (SD)	1.0 (1.1)	1.0 (1.0)	0.82
ASA score, mean (SD)	2.4 (0.7)	2.4 (0.6)	0.85
Operated level, n (%)			0.65
1-level	39 (60%)	21 (50%)	
2-level	19 (29%)	14 (33%)	
3-level	3 (5%)	4 (10%)	
4-level	3 (5%)	3 (7%)	
5-level	1 (2%)	0 (0%)	
Severity ^a (Schizas grade), n (%)			0.27
C	22 (34%)	10 (24%)	
D	43 (66%)	32 (76%)	

Abbreviations: ASA, American Society of Anesthesiologists; CCI, Charlson Comorbidity Index.

^aMost severe level of operated segments.

The results of the GEE analysis indicated that time had a statistically significant effect on all clinical outcomes, demonstrating significant changes in scores from baseline to follow-up periods. However, age group did not show a statistically significant effect on any of the clinical outcomes, suggesting that the improvements in clinical outcomes over time were similar across both age groups (Figure 2).

The complications and surgery-related outcomes for biportal endoscopic laminectomy were compared between Group 1 and Group 2 as summarized in Table 3. The mean operation time, hospital stay, blood loss, and postoperative drainage were slightly longer and higher in Group 2 compared with Group 1, but the difference was not statistically significant. All complications, such as incidental durotomy, hematoma, surgical site infection, revision surgery due to recurrent symptoms, delirium, and pneumonia, were not significantly different. Furthermore, no major complications, such as surgery-related death, deep vein thrombosis, pulmonary embolism, stroke, cardiovascular event, and neurological injury, were observed.

DISCUSSION

This study evaluated the outcomes of BED in elderly patients aged 80 years or older with LSS. Our findings indicate significant improvements in patient's symptoms without major complications. These improvements were also observed across both age groups (80–84 years and 85 years or older), with no significant differences between 2 groups. While most existing research has primarily focused on patients younger than 80 years, our study sought to investigate whether the

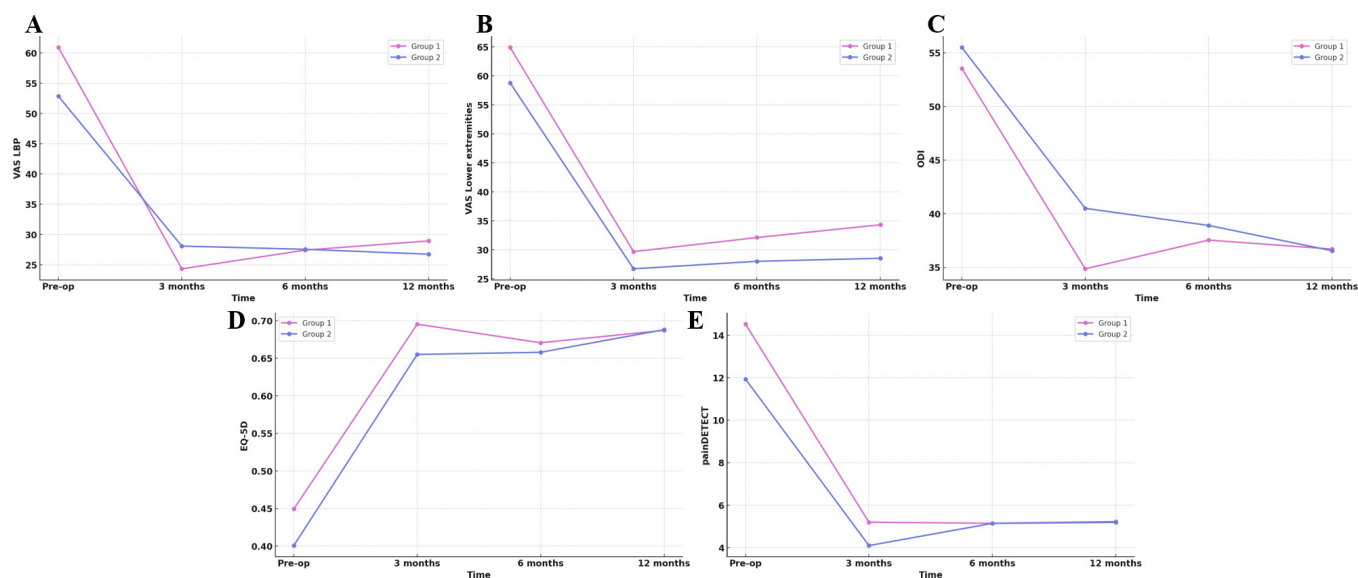


Figure 2. (A and B) Changes in mean VAS score for low back and lower extremities radiating pain, ranging from 0 (no pain) to 10 (worst pain). (C) Changes in mean ODI score, ranging from 0 (no disability) to 100 (high disability). (D) Changes in mean EQ-5D value, ranging from 0 (worst quality of life) to 1.000 (best quality of life). (E) Changes in mean painDETECT score, ranging from -1 (neuropathic pain less likely) to 38 (neuropathic pain most likely). VAS, visual analog scale; ODI, Oswestry Disability Index; EQ-5D, European Quality of Life-5 Dimensions.

benefits of minimally invasive surgery, such as biportal endoscopic techniques, could also be observed in super-aged individuals. The results suggest that biportal endoscopic surgery may offer meaningful benefits even in patients older than 80 years, including those older than 85, without an apparent increase in risk. These findings contribute to the ongoing discussion about the suitability of minimally invasive approaches in managing spinal stenosis in the elderly, particularly in those of advanced age.

Managing LSS in patients aged 80 years or older presents several challenges. While surgery is recommended for patients unresponsive to conservative treatments, symptomatic spinal stenosis is being recognized more frequently in older individuals who may not be suitable candidates for surgery due to their physical status.²⁰ However, surgical treatment for LSS in carefully selected elderly patients has been shown to provide good results with acceptable morbidity.²¹ Advanced age is associated with a higher prevalence of comorbidities, reduced physiological reserve, and increased surgical risks.²² These factors complicate the perioperative management and postoperative recovery in this population. Although fusion surgery is an option for spinal stenosis, it has significant risks and may not be acceptable for many senior individuals due to extended recovery periods, increased risk for complications, and higher demands on their overall health.²³ Given the complexities and risks associated with fusion surgery in the elderly, decompressive laminectomy is frequently preferred for patients older than 80 years.²⁴

The decision between decompression alone and fusion surgery remains a topic of debate, with studies suggesting that decompressive laminectomy alone can yield favorable outcomes in elderly patients with advanced age or poor general condition.²³

Previous studies have reported favorable outcomes with laminectomy in this age group, demonstrating its efficacy in relieving symptoms and improving function.²⁵ Less invasive approaches such as unilateral microsurgical procedures have been increasingly utilized for decompression in elderly patients with LSS.^{24,26,27} These findings highlight the importance of considering laminectomy as a viable option for managing LSS in the elderly, emphasizing its role in improving symptoms and functional outcomes in this population. Full-endoscopic decompression procedures have been highlighted as advantageous due to their small incisions and rapid recovery, making them a viable alternative for treating LSS, especially in elderly patients with comorbidities.²⁸ Additionally, endoscopic spine surgery under local anesthesia has been suggested as an effective option for elderly patients with poor general health, further supporting the utilization of endoscopic techniques in this population.²⁹ However, the use of biportal endoscopic techniques has not been extensively studied in this population.

The emergence of novel techniques such as biportal endoscopic unilateral laminectomy for bilateral decompression has provided minimally invasive options for spinal stenosis treatment, emphasizing

Table 3. Clinical and surgery-related outcomes for biportal endoscopy laminectomy during 12-month follow-up.

Variables	Group 1, Age ≥85 y	Group 2, Age <85 y	P ^a
VAS back			<0.001
Preoperation	60.92 (25.29)	52.86 (28.31)	
3 mo	23.92 (23.16)	29.00 (27.96)	
6 mo	27.40 (23.28)	27.59 (23.55)	
12 mo	29.20 (25.22)	26.07 (25.14)	
Group effect			0.720
VAS lower extremities			<0.001
Preoperation	64.92 (28.84)	58.81 (27.69)	
3 mo	30.00 (27.78)	26.00 (34.20)	
6 mo	32.60 (28.56)	26.90 (31.06)	
12 mo	35.00 (31.64)	26.79 (33.34)	
Group effect			0.612
ODI			<0.001
Preoperation	53.54 (18.00)	55.50 (13.83)	
3 mo	34.25 (19.67)	41.87 (20.93)	
6 mo	37.38 (18.50)	39.28 (22.30)	
12 mo	36.72 (18.26)	36.50 (23.04)	
Group effect			0.805
EQ-5D			<0.001
Preoperation	0.45 (0.21)	0.40 (0.19)	
3 mo	0.70 (0.20)	0.65 (0.25)	
6 mo	0.67 (0.21)	0.65 (0.27)	
12 mo	0.69 (0.20)	0.69 (0.28)	
Group effect			0.617
painDETECT			<0.001
Preoperation	14.53 (7.83)	11.93 (7.06)	
3 mo	5.36 (6.46)	3.83 (4.11)	
6 mo	5.15 (5.77)	5.14 (5.37)	
12 mo	5.23 (5.48)	5.18 (5.31)	
Group effect			0.126
Complications, n (%) ^b			
Incidental durotomy	9 (14%)	6 (14%)	>0.99
Hematoma	4 (6%)	2 (5%)	>0.99
Surgical site infection	1 (2%)	0	>0.99
Revision surgery due to recurrence	0	1 (2%)	0.393
Delirium	4 (6%)	3 (7%)	>0.99
Pneumonia	2 (3%)	1 (2%)	>0.99
Surgery-related outcomes			
Operation time, min	82.11 (30.37)	85.87 (31.70)	0.549
Hospital stay, d	5.25 (1.95)	8.16 (16.24)	0.168
Intraoperative blood loss, mL	98.14 (100.19)	131.94 (144.00)	0.182
Postoperative drainage, mL	130.92 (157.47)	142.71 (119.96)	0.694

Abbreviations: EQ-5D, European Quality of Life-5 Dimensions; ODI, Oswestry disability index; VAS, visual analog scale.

Data are presented as given as mean (SD) unless otherwise indicated.

^aP values are from Generalized Estimating Equations: (1) Overall P values indicate the time effect over 12 months. (2) Group effect P values compare Groups 1 and 2 differences over 12 months.

^bFisher's exact test was used.

the importance of less invasive approaches in managing this condition.^{3,14} In our study, we performed biportal endoscopic laminectomy on a cohort of elderly patients, including those aged 80 years or older. Our results demonstrate that this minimally invasive technique provides significant symptom relief and functional improvement in high-risk elderly patients. Furthermore, the extremely advanced old age (≥85 years) was comparable to those in the 80- to 84-year age group, suggesting

that even the oldest patients can benefit significantly from this procedure. The lack of significant differences in results between the 2 groups indicates that age alone should not discourage consideration of this minimally invasive surgical alternative for older patients with spinal stenosis. Notably, even among the oldest patients, biportal endoscopic laminectomy resulted in positive clinical outcomes, suggesting its safety and efficacy in this challenging patient population.

In our study, the incidence of dura tears was 14%, which is higher than the rates reported in the existing literature. This discrepancy is likely due to the inclusion of only elderly patients. It is plausible that the incidence of dura tears is higher in elderly patients because the dura mater is thinner in this age group compared with younger populations. Additionally, adhesions to the dura and LF may be more severe in cases of severe stenosis. Despite the higher incidence, the management of these tears was conducted in accordance with established protocols from previous studies, and all patients were treated successfully without any further complications.³⁰

Limitations

This study has several limitations. First, its retrospective design may introduce selection bias, and the lack of a control group (younger than 80 years) limits the ability to compare outcomes with other surgical techniques. Second, the relatively small sample size and single-center nature of the study may affect the generalizability of the results. Additionally, making surgical treatment decisions for patients older than 80 years is challenging due to the high risk of complications, and surgery was only considered for those with severe spinal stenosis. This made it difficult to gather a large number of cases. Third, while follow-up was conducted for up to 12 months after surgery, longer-term outcomes were not assessed. Future studies should include larger cohorts, multiple centers, and extended follow-up periods to validate these findings.

CONCLUSION

BED is a safe and effective treatment for LSS in patients aged 80 years or older. This technique offers significant improvements in pain, function, and QOL, even among the oldest patients. These findings support the use of minimally invasive

endoscopic techniques in managing spinal stenosis in the elderly, providing a viable alternative to more invasive surgical options.

REFERENCES

1. Kwon J-W, Moon S-H, Park S-Y, et al. Lumbar spinal stenosis: review update 2022. *Asian Spine J.* 2022;16(5):789–798. doi:10.31616/asj.2022.0366
2. Choi JY, Park SM, Kim HJ, Yeom JS. Recent updates on minimally invasive spine surgery: techniques, technologies, and indications. *Asian Spine J.* 2022;16(6):1013–1021. doi:10.31616/asj.2022.0436
3. Junjie L, Jiheng Y, Jun L, Haixiong L, Haifeng Y. Comparison of unilateral biportal endoscopy decompression and microscopic decompression effectiveness in lumbar spinal stenosis treatment: a systematic review and meta-analysis. *Asian Spine J.* 2023;17(2):418–430. doi:10.31616/asj.2021.0527
4. Mobbs R, Phan K. Minimally invasive unilateral laminectomy for bilateral decompression. *JBJS Essent Surg Tech.* 2017;7(1). doi:10.2106/JBJS.ST.16.00072
5. Hayashi K, Matsumura A, Konishi S, Kato M, Namikawa T, Nakamura H. Clinical outcomes of posterior lumbar interbody fusion for patients 80 years of age and older with lumbar degenerative disease: minimum 2 years' follow-up. *Glob Spine J.* 2016;6(7):665–672. doi:10.1055/s-0036-1578806
6. Choi JM, Choi MK, Kim SB. Perioperative results and complications after posterior lumbar interbody fusion for spinal stenosis in geriatric patients over than 70 years old. *J Korean Neurosurg Soc.* 2017;60(6):684–690. doi:10.3340/jkns.2017.0203
7. Sriphirom P, Siramanakul C, Sumritsopak M, Chokviriyaprasert P, Uttamo N, Songchou K. Clinical outcomes of interlaminar percutaneous endoscopic uniportal pars decompression for lumbar spondylolysis. *Int J Spine Surg.* 2023;17(3):335–342. doi:10.14444/8413
8. Ko YR, Ahn DK, Lee JS, Jung JS, Lee YH, Kim YH. Effect of thrombin-containing local hemostatics on postoperative spinal epidural hematoma in biportal endoscopic spinal surgery. *Asian Spine J.* 2024;18(1):87–93. doi:10.31616/asj.2023.0208
9. Wang L, Wang T, Fan N, et al. Clinical outcome of percutaneous endoscopic lumbar decompression in treatment of elderly patients with lumbar spinal stenosis: a matched retrospective study. *Int Orthop.* 2024;48(1):201–209. doi:10.1007/s00264-023-05947-y
10. Lee CH, Hyun SJ, Kim KJ, Jahng TA, Kim HJ. Decompression only versus fusion surgery for lumbar stenosis in elderly patients over 75 years old: which is reasonable? *Neurol Med Chir.* 2013;53(12):870–874. doi:10.2176/nmc.0a2012-0415
11. Park J, Ahn D-K, Choi D-J. Treatment concept and technical considerations of biportal endoscopic spine surgery for lumbar spinal stenosis. *Asian Spine J.* 2024;18(2):301–323. doi:10.31616/asj.2023.0409
12. Park S-M, Kim G-U, Kim H-J, et al. Is the use of a unilateral biportal endoscopic approach associated with rapid recovery after lumbar decompressive laminectomy? a preliminary analysis of a prospective randomized controlled trial. *World Neurosurg.* 2019;128:e709–e718. doi:10.1016/j.wneu.2019.04.240
13. Park S-M, Lee H-J, Park H-J, et al. Biportal endoscopic versus microscopic discectomy for lumbar herniated disc: a randomized controlled trial. *Spine J.* 2023;23(1):18–26. doi:10.1016/j.spinee.2022.09.003
14. Park S-M, Park J, Jang HS, et al. Biportal endoscopic versus microscopic lumbar decompressive laminectomy in patients with spinal stenosis: a randomized controlled trial. *Spine J.* 2020;20(2):156–165. doi:10.1016/j.spinee.2019.09.015
15. Kang T, Park SY, Kang CH, Lee SH, Park JH, Suh SW. Is biportal technique/endoscopic spinal surgery satisfactory for lumbar spinal stenosis patients? *Medicine.* 2019;98(18). doi:10.1097/MD.00000000000015451
16. Heo DH, Lee DC, Park CK. Comparative analysis of three types of minimally invasive decompressive surgery for lumbar central stenosis: biportal endoscopy, uniportal endoscopy, and microsurgery. *Neurosurg Focus.* 2019;46(5). doi:10.3171/2019.2.FOCUS197
17. Fairbank JC, Pynsent PB. The Oswestry disability index. *Spine.* 2000;25(22):2940–2952. doi:10.1097/00007632-200011150-00017
18. Herdman M, Gudex C, Lloyd A, et al. Development and preliminary testing of the new five-level version of EQ-5D (EQ-5D-5L). *Qual Life Res.* 2011;20(10):1727–1736. doi:10.1007/s11136-011-9903-x
19. Freynhagen R, Baron R, Gockel U, Tölle TR. PainDETECT: a new screening questionnaire to identify neuropathic components in patients with back pain. *Curr Med Res Opin.* 2006;22(10):1911–1920. doi:10.1185/030079906X132488
20. Igarashi T, Hirabayashi Y, Seo N, Saitoh K, Fukuda H, Suzuki H. Lysis of adhesions and epidural injection of steroid/local anaesthetic during epiduroscopy potentially alleviate low back and leg pain in elderly patients with lumbar spinal stenosis. *Br J Anaesth.* 2004;93(2):181–187. doi:10.1093/bja/ae201
21. Hur J-W, Kim S-H, Lee J-W, Lee H-K. Clinical analysis of postoperative outcome in elderly patients with lumbar spinal stenosis. *J Korean Neurosurg Soc.* 2007;41(3). doi:10.3340/jkns.2007.41.3.157
22. Rault F, Briant AR, Kamga H, Gaberel T, Emery E. Surgical management of lumbar spinal stenosis in patients over 80: is there an increased risk? *Neurosurg Rev.* 2022;45(3):2385–2399. doi:10.1007/s10143-022-01756-w
23. Son S, Kim WK, Lee SG, Park CW, Lee K. A comparison of the clinical outcomes of decompression alone and fusion in elderly patients with two-level or more lumbar spinal stenosis. *J Korean Neurosurg Soc.* 2013;53(1):19–25. doi:10.3340/jkns.2013.53.1.19
24. Morgalla MH, Noak N, Merkle M, Tatagiba MS. Lumbar spinal stenosis in elderly patients: is a unilateral microsurgical approach sufficient for decompression? *J Neurosurg Spine.* 2011;14(3):305–312. doi:10.3171/2010.10.SPINE09708
25. Silvers HR, Lewis PJ, Asch HL. Decompressive lumbar laminectomy for spinal stenosis. *J Neurosurg.* 1993;78(5):695–701. doi:10.3171/jns.1993.78.5.0695
26. Son HJ, Chang B-S, Chang SY, Gimm G, Kim H. Midterm outcomes of muscle-preserving posterior lumbar decompression via sagittal splitting of the spinous process: minimum 5-year follow-up. *Clin Orthop Surg.* 2023;15(5):800–808. doi:10.4055/cios22362
27. Yagi M, Okada E, Ninomiya K, Kihara M. Postoperative outcome after modified unilateral-approach microendoscopic midline decompression for degenerative spinal stenosis. *J Neurosurg Spine.* 2009;10(4):293–299. doi:10.3171/2009.1.SPINE08288
28. Fei Y, Chen R, Gu D. Clinical comparison of full-endoscopic and microscopic unilateral laminotomy for bilateral decompression in the treatment of elderly lumbar spinal stenosis: a retrospective study with 12-month follow-up. *J Pain Res.* 2020;11(13):1377–1384. doi:10.2147/JPR.S254275

29. Hashimoto A, Tezuka F, Yamashita K, et al. Planned four-stage transforaminal full-endoscopic lumbar decompression under local anesthesia in a patient with severe comorbidity. *NMC Case Rep J.* 2021;8(1):221–227. doi:10.2176/nmccrj.cr.2020-0104

30. Park HJ, Kim SK, Lee SC, Kim W, Han S, Kang SS. Dural tears in percutaneous biportal endoscopic spine surgery. *Anat Loc Manag World Neurosurg.* 2020;136:e578–e585. doi:10.1016/j.wneu.2020.01.080

Funding: The authors received no financial support for the research, authorship, and/or publication of this article.

Declaration of Conflicting Interests: The authors report no conflicts of interest in this work.

Corresponding Author: Sang-Min Park, Department of Orthopedic Surgery, Spine Center, Hallym University College of Medicine, Kangnam Sacred Heart Hospital 1, Singil-Ro, Yeongdeungpo-Gu, Seoul 07441, Republic of Korea; phjfrog@gmail.com

This manuscript is generously published free of charge by ISASS, the International Society for the Advancement of Spine Surgery. Copyright © 2024 ISASS. To see more or order reprints or permissions, see <http://ijssurgery.com>.