

Lumbar Intramuscular Myxoma: Microsurgical Resection With Assistance From an Endoscopic Microinspection Tool

Juan Antonio Ponce-Gómez, María Fernanda Tejada-Pineda, Marco Muñuzuri-Camacho, Sergio Moreno-Jiménez, Samuel Romano-Feinholz, Víctor Alcocer-Barradas, Marcela Amparo Osuna-Zazueta, José Pablo Zárate-García, Júlia Moscardini-Martelli and Luis Alberto Ortega-Porcayo

Int J Spine Surg published online 2 April 2025
<https://www.ijssurgery.com/content/early/2025/04/01/8733>

This information is current as of April 5, 2025.

Email Alerts Receive free email-alerts when new articles cite this article. Sign up at:
<http://ijssurgery.com/alerts>

Lumbar Intramuscular Myxoma: Microsurgical Resection With Assistance From an Endoscopic Microinspection Tool

JUAN ANTONIO PONCE-GÓMEZ, MD^{1,2}; MARÍA FERNANDA TEJADA-PINEDA, MD¹;
MARCO MUÑUZURI-CAMACHO, MD²; SERGIO MORENO-JIMÉNEZ, MD, PhD^{1,2}; SAMUEL ROMANO-FEINHOLZ,
MD, MSc¹; VICTOR ALCOCER-BARRADAS, MD²; MARCELA AMPARO OSUNA-ZAZUETA,
MD¹; JOSÉ PABLO ZÁRATE-GARCÍA, MD¹; JÚLIA MOSCARDINI-MARTELLI, MD¹; AND
LUIS ALBERTO ORTEGA-PORCAYO, MD, MBE¹

¹Centro Médico ABC, Mexico City, Mexico; ²Instituto Nacional de Neurología y Neurocirugía “Manuel Velasco Suárez”, Mexico City, Mexico

ABSTRACT

Background: Intramuscular myxomas (IMs) are rare benign neoplasms of fibroblastic origin, typically presenting in adults, with a female predominance. IMs are uncommonly located in the skeletal muscles, most frequently in the thighs, but rarely in the paraspinal region. IM may be located deeply in this region and that could present a challenge for complete resection.

Case Presentation: A 66-year-old woman presented with progressive lower back pain and radicular symptoms, which were due to a paraspinal IM.

Case Management: The patient underwent a minimally invasive microsurgical resection assisted by a 45° endoscopic microinspection tool (QEVO) to enhance visualization and access the lateral compartment of the tumor. Microsurgical dissection assisted with endoscopic visualization allowed successful resection of the tumor, including its lateral compartment, without extensive muscle transection. No complications occurred during or after surgery, and the patient reported complete symptom relief with no recurrence after 2 years.

Technology: This case demonstrates the value of integrating endoscopic tools in spinal surgery, particularly in cases where conventional microsurgical techniques are insufficient for complete tumor resection using less invasive approaches. The enhanced visualization provided by the 45° endoscope facilitated the successful resection of a paraspinal lesion, improving surgical precision and patient outcomes.

Conclusions: The QEVO microinspection tool is an effective adjunct to microsurgical techniques, offering enhanced visualization and precision during tumor resection. This case highlights its potential to address the challenges posed by deeply located paraspinal tumors. As further research explores its use in spine surgery, this microinspection tool could become an important asset in minimally invasive spinal tumor resections, improving patient outcomes through better tissue preservation and complete resection.

Level of Evidence: 5.

Novel Techniques & Technology

Keywords: intramuscular myxoma, endoscopic assistance, minimally invasive surgery

INTRODUCTION

Myxomas are benign neoplasms of fibroblastic origin that structurally resemble the umbilical cord, consisting of stellate cells in a loose myxoid stroma with poor vascularity.^{1,2} Despite being rare tumors, intramuscular myxomas (IMs) are the most common mainstream myxomas of soft tissues and occur along any skeletal muscle.² The occurrence rate of IM ranges between 0.1 and 0.3 per 100,000 individuals.³ Myxomas mainly arise in adults between the fifth and eighth decades of life, and 66% of cases present in women.⁴ Most IMs are asymptomatic or are discovered incidentally as painless growing masses in the muscles of the thigh. Rare case reports have documented IM in the

paraspinal muscles, with approximately 40% of these cases occurring in the lumbar spine.⁵ Current treatment advocates for total surgical resection. The long-term biological behavior of the tumor is benign, with no significant risk of distant metastasis and a low potential for local recurrence.^{6,7} The present article reports a rare lumbar paraspinal IM resected using a minimally invasive microsurgical approach assisted with a 45° endoscopic microinspection tool (QEVO by ZEISS).

CASE REPORT

A 66-year-old woman began experiencing progressive mild lower back pain radiating toward the right

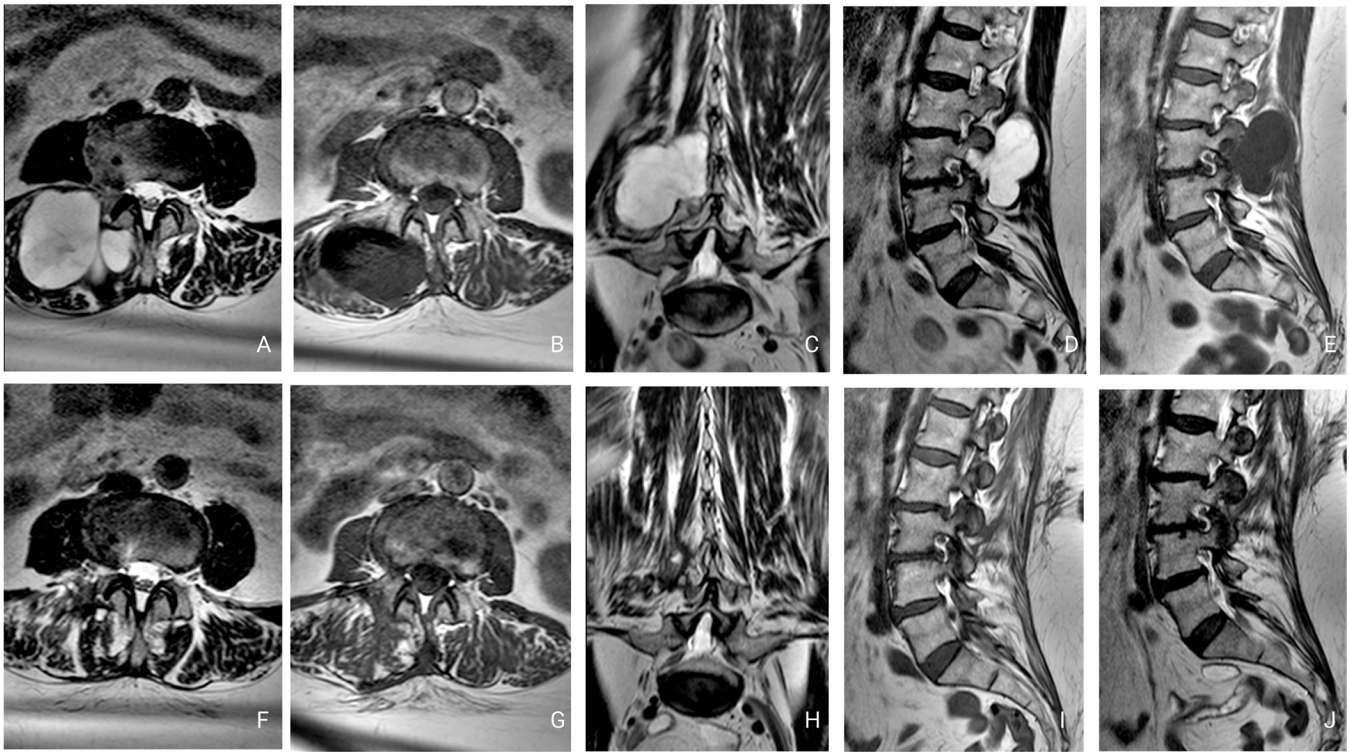


Figure 1. Pre- and postoperative lumbar magnetic resonance images (MRI). Preoperative imaging revealed a lobulated, well-defined lesion with a cystic appearance, measuring 5 × 5.4 × 5.5 cm, at the L3 to L4 level. Postoperative MRI showed complete resection with minimal fascia and paraspinous musculature transgression. (A) Preoperative axial T2-weighted image showed a hyperintense lesion. (B) Preoperative axial T1-weighted image showed a hypointense lesion. (C) Preoperative coronal T2-weighted image. (D) Preoperative sagittal T2-weighted image. (E) Preoperative sagittal T1-weighted image. (F) Postoperative axial T2-weighted image. (G) Postoperative axial T1-weighted image. (H) Postoperative coronal T2-weighted image. (I) Postoperative sagittal T2-weighted image. (J) Postoperative sagittal T1-weighted image.

leg. Conservative treatment with nonsteroidal anti-inflammatory drugs, muscle relaxants, and a facet and radicular block was performed in a different medical center; however, the patient's pain episodes increased in frequency and intensity. Physical examination showed decreased muscle strength of the right leg (4/5 on Daniels scale) and slight hypoesthesia in the right L3 and L4 dermatomes. Lumbar spine magnetic resonance imaging revealed a right intramuscular cystic paravertebral lesion affecting the L3 to L4 nerve root adjacent to the facet joint (Figure 1). Based on our initial evaluation, surgical exploration was recommended.

The surgical procedure involved a paralumbar approach using a 3-cm incision. The procedure began with microscopic visualization utilizing the Kinevo microscope. Intralesional tumor biopsies and decompression were performed using aspiration, dissection, and biopsy forceps facilitated by the tumor's soft consistency and low vascularity. However, the lateral compartment of the tumor was found beyond the reach of the microsurgical view. To overcome this limitation, the lateral compartment of the tumor was effectively resected using a 45° endoscopic microinspection device

(QEVO). This allowed us to complete the resection under the thoracolumbar fascia without fully transecting the paralumbar muscles. No complications were observed during or after the procedure (Video 1 and Figure 1). The patient reported complete relief of her symptoms and remains asymptomatic after 2 years. The histopathological report revealed an IM, and the immunohistochemistry study showed focal CD34 and Ki67 1% (Figure 2).

DISCUSSION

Myxomas are benign neoplasms originating from embryonic mesenchymal cells.^{8,9} Although this type of tumor is most common in the right atrium of the heart, it can arise almost anywhere. These neoplasms are characterized by their abundant myxoid matrix and poor vascularity.²

There are 24 reported cases of paraspinal IMs in the literature.⁷⁻¹⁰ Of these, 10 were in the cervical spine, 2 in the thoracic spine, and 12 in the lumbar spine. Typically, patients presented with intermittent lower back pain and radicular symptoms, although some were asymptomatic. Those who were previously

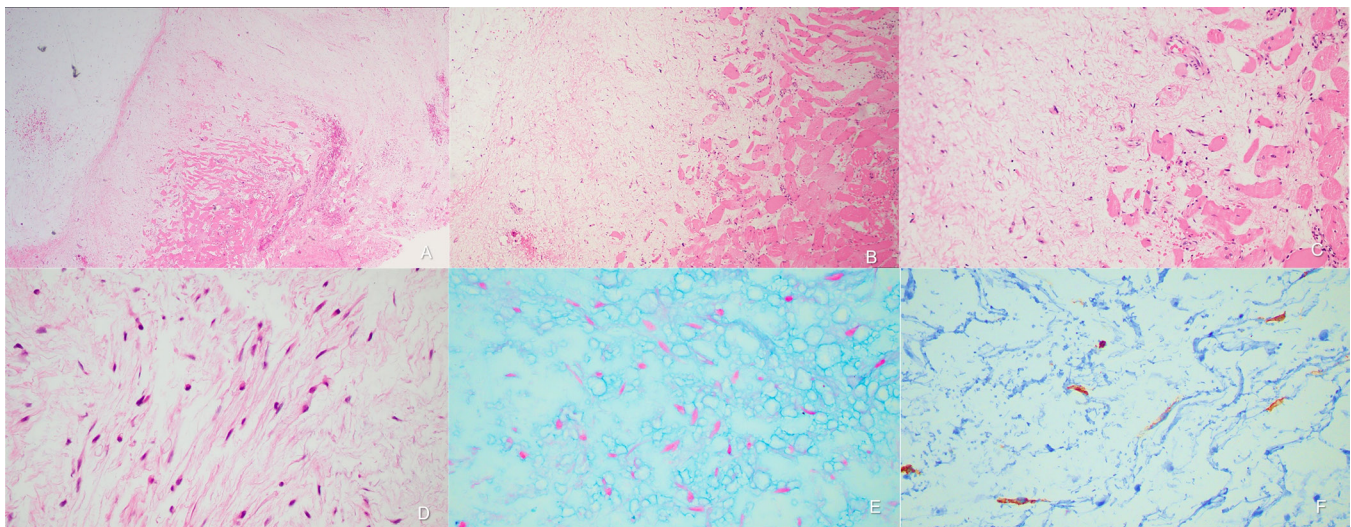


Figure 2. Histopathological findings. (A–D) Hematoxylin and eosin staining show a hypocellular lesion composed of spindle-shaped, monomorphic cells with a benign appearance, scant cytoplasm, and pale eosinophils. The nuclei are small and oval. These cells are embedded in an abundant stroma with myxoid characteristics, accompanied by a network of fine capillaries. Morphological findings were compatible with IM (magnification: A, 4 \times ; B, 10 \times ; C, 20 \times ; and D, 40 \times). (E) Alcian blue stain is positive in the stroma. (F) Immunohistochemistry for CD34 shows focally positive cells with a proliferation index of 1%, as determined by Ki67 staining.

symptomatic generally became asymptomatic after the procedure, with no recurrence of the tumor (Table).

IMs typically occur in adults between the third and sixth decades of life, with a notable predominance in women (12:1 ratio).^{14,27} While they are primarily found in long muscles such as those in the thigh, shoulders, buttocks, and upper extremities, few cases have been documented in the spine, particularly the cervical and lumbar regions. Surgical resection is the only curative treatment, and recurrence is very rare.²⁸ Despite this, there are no established guidelines for the surgical approach to these tumors.

In the patient described in the present report, a microsurgical resection was initially attempted. However, the lateral compartment of the tumor was beyond the reach of the microsurgical view. To address this challenge, an endoscopic microinspection device (120 mm \times 3.6 mm) with a 45° viewing angle was employed. The device's 45° angle allowed an expanded field of view, allowing for a detailed examination and dissection of the tumor while preserving the paraspinal musculature. The enhanced visualization capabilities provided by the endoscope were crucial in achieving a complete resection of the lesion, which was otherwise inaccessible through a small incision.

The QEVO endoscopic microinspection tool, integrated into the Kinevo digital visualization platform, has demonstrated successful applications in both cadaveric studies and clinical practice. It has proven valuable in tumor and aneurysm surgeries to detect hidden tumor remnants or assess aneurysm clip placement,

particularly in challenging anatomical regions. Separate clinical cases by Belykh et al²⁹ and Schebesch et al,³⁰ including middle cerebral artery aneurysm clipping, cerebellar cavernoma removal, and pituitary adenoma resection, have highlighted the tool's ability to enhance visualization of deep structures and improve surgical precision. Similarly, additional case series have underscored the QEVO tool's ability to navigate complex surgical exposures, such as the posterior fossa and ventricular space, where acute angles and blind spots limit standard microscopic visualization.^{31,32} The tool provides high-resolution imaging and depth perception for neurovascular structures, with a wide viewing angle that expands the surgeon's field of vision. Notably, its ergonomic design allows for precise and controlled handling under direct microscopic visualization, ensuring safe maneuvering around delicate neurovascular structures. Unlike traditional endoscopes, the QEVO microinspection device offers significant practical advantages, including its fast setup, seamless integration with the Kinevo platform, and on-demand usability without the need for additional preparation or an endoscope tower. Despite some limitations, such as its short length and reliance on the Kinevo platform, the QEVO microinspection tool remains innovative and efficient in addition to neurosurgical techniques, enhancing safety, precision, and workflow efficiency.^{29–32}

The use of the QEVO microinspection tool has been mainly used in intracranial surgeries, and its use in spinal surgeries has been less documented. Feigl et al reported a case where the tool was successfully used

Table. Reported cases of paraspinous intramuscular myxomas.

Reference	Year	Location	Age, y	Sex	Presentation	Outcome
Ponce-Gómez	2025	L3–L4	66	F	Intermittent lumbar pain with associated significant radiculopathy	2-y follow-up, asymptomatic, and no recurrence
Hipólito-Reis ⁹	2023	L3	64	F	Lumbar pain radiates to the anterior aspect of the right thigh accompanied by numbness	Asymptomatic
Patel ¹¹	2022	C4–C5	77	F	Incidental finding of a cervical mass	3-mo follow-up, asymptomatic, and no recurrence
Patel ¹¹	2022	C5–C6	72	F	5-wk history of left-sided shoulder pain radiating to the neck and upper arm in a C5 distribution, reduced manual dexterity as well as paresthesia in all 4 extremities, and loss of balance	3-mo follow-up, asymptomatic, and no recurrence
Al Awadhi ¹⁰	2021	L4–S2	76	F	Paravertebral lumbar pain, intermittent L5 radicular pain, and distal L5 paresthesia	Asymptomatic and no recurrence
Kwon ⁸	2016	L1	39	F	Severe lower back pain	Asymptomatic
Choi ⁵	2015	L4–L5	65	F	Lower back pain for 3 mo without radiating leg pain	Asymptomatic
Tataryn ¹²	2015	C3–C4	57	F	Posterior neck pain with a lump	-
Manoharan ¹³	2015	C4–C5	63	F	Posterior neck pain with radicular arm pain	1.5 y follow-up
Rachidi ⁷	2014	C	45	M	Painless posterior cervical mass	30-mo follow-up, asymptomatic, and no recurrence
Ohla ¹⁴	2013	L5–S1	57	F	Complaints of vague pelvic discomfort	3.6-y follow-up
Rashid ¹⁵	2011	L2–S3	70	F	Back pain and a mass in right paravertebral region	12-mo follow-up
Stinchcombe ¹⁶	2010	L2–S1	80	F	Lower back pain for 4 months and weight loss	-
Stinchcombe ¹⁶	2010	L2–S1	80	F	Lower back pain	-
Taggarshe ¹⁷	2010	T	52	F	Intermittent neck pain	3-mo follow-up
Falavigna ¹	2009	C2–C4	64	F	Occipital and neck pain over 5 y	1-y follow-up, asymptomatic, and no recurrence
Ishoo ¹⁸	2007	C	22	F	6-mo history of a progressively enlarging posterior neck mass, with decreased cervical mobility	2-y follow-up, asymptomatic, and no recurrence
Crankson ¹⁹	2002	C	5	F	Progressively enlarging neck mass over 7 mo	1-y follow-up, asymptomatic, and no recurrence
Guppy ²⁰	2001	L5–S1	80	F	Lower back pain for more than 20 y with radiation down the left thigh, leg, and great toe	3-mo follow-up, asymptomatic, and no recurrence
Liguoro ²¹	1999	L5	63	F	Lower back pain and sciatica	2 y follow-up
Kamoun ²²	1997	L5–S1	54	F	Lower back pain and sciatica	3 y follow-up
Shugar ²³	1987	C5–T1	68	F	Asymptomatic	12 mo follow-up
Bell ²⁴	1983	L3–L4	60	M	Clumsiness of the lower extremities and calf pain precipitated by walking	10 mo follow-up, asymptomatic, and no recurrence
Tahmouresie ²⁵	1981	T11–T12	50	M	Severe back pain and progressive gait disturbance	-
Feldman ²⁶	1979	C	62	F	-	-

Abbreviations: F, female; M, male.

for a giant hernia resection.³³ We believe that this area warrants further exploration, as the endoscopic micro-inspection tool has the potential to improve angled complex visualization in degenerative spinal diseases or spinal tumors, especially as an adjunct in microscopic procedures to enhance ergonomics and surgical precision.

The QEVO microinspection tool offers excellent haptic properties and provides a high-resolution view at a 45° angle. Additionally, the 45° view and angled instruments allow the surgeon to maintain a more comfortable position without the need to adjust the microscope. However, the tool lacks an external holder, requiring a second surgeon to dynamically hold the endoscope during the procedure. Despite this, visualization can be rapidly alternated between microscopic and endoscopic views, although it does not support 0° or 30° optics.

The successful integration of the endoscopic micro-inspection device in this procedure underscores its value in spinal surgeries. This case highlights the potential for

endoscopic technology to improve surgical techniques, offering better outcomes through better visualization, precision, and tissue preservation.

CONCLUSION

The resection of a paralumbar myxoma presents unique challenges due to the tumor's deep location. Successful management of such cases requires advanced visualization tools to ensure complete tumor removal while minimizing damage to surrounding tissues. The QEVO endoscopic microinspection tool, integrated with the Kinevo digital visualization platform, offers significant advantages in addressing these challenges. Its ability to enhance visualization in deep and complex surgical corridors, coupled with its ergonomic design and seamless operability, allows for precise resection of lesions in anatomically challenging regions.

In our case, the use of the QEVO tool facilitated exposure and inspection of concealed areas, ensuring

the complete removal of the tumor. This case emphasizes the importance of adopting innovative surgical technologies to improve visualization for safer, less invasive, and more precise surgery in rare and complex tumors like paralumbar myxomas.

ACKNOWLEDGMENTS

The authors would like to thank the pathology department for their detailed analysis and the radiology team for their assistance with imaging. We also extend our gratitude to the patient for her willingness to share her case, contributing to the advancement of medical knowledge.

REFERENCES

1. Falavigna A, Righesso O, Volquind D, Teles AR. Intramuscular myxoma of the cervical paraspinal muscle. *Eur Spine J*. 2009;18 Suppl 2(Suppl 2):245–249. doi:10.1007/s00586-009-0933-9
2. Allen PW. Myxoma is not a single entity: a review of the concept of myxoma. *Ann Diagn Pathol*. 2000;4(2):99–123. doi:10.1016/s1092-9134(00)90019-4
3. Jabbar S, Jamil OBK, Ali R, Zulfikar I, Tharwani ZH. Intramuscular myxoma of the thigh: a case report. *SAGE Open Med Case Rep*. 2023;11:2050313X231200120. doi:10.1177/2050313X231200120
4. Sağlam S, Orhan Ş, Orhan Z, Turhan Y, Arıcan M. Intramuscular myxoma in the gluteus maximus muscle after continuous intramuscular injections. *Jt Dis Relat Surg Case Rep*. 2022;1(1):31–34. doi:10.52312/jdrscr.2022.9
5. Choi DY, Kim JT, Kim J, Lee HJ. Atypical intramuscular myxoma of the lumbosacral paraspinal muscle: the first case report in asian. *J Korean Neurosurg Soc*. 2015;58(6):566–570. doi:10.3340/jkns.2015.58.6.566
6. Sukpanichyingyong S, Matsumoto S, Ae K, et al. Surgical treatment of intramuscular myxoma. *Indian J Orthop*. 2021;55(4):892–897. doi:10.1007/s43465-021-00367-9
7. Rachidi S, Sood AJ, Rumboldt T, Day TA. Intramuscular myxoma of the paraspinal muscles: a case report and systematic review of the literature. *Oncol Lett*. 2016;11(1):466–470. doi:10.3892/ol.2015.3864
8. Kwon JY, Kim IS, Hong JT, Kim JY, Sung JH, Lee SW. Intramuscular myxoma of the lumbar paravertebral muscle. *Spine J*. 2016;16(7):e451–e452. doi:10.1016/j.spinee.2016.01.011
9. Hipólito-Reis J, Roque D, Teixeira JC. Lumbar paraspinal intramuscular myxoma: a case report. *Surg Neurol Int*. 2023;14:86. doi:10.25259/SNI_141_2023
10. Al Awadhi A, Benichi S, Lot G, Rogers A. A case of intramuscular lumbar myxoma: uncertainty in the preoperative diagnosis of a spinal soft tissue tumour. *Neurochirurgie*. 2022;68(5):530–534. doi:10.1016/j.neuchi.2021.08.007
11. Patel S, Suji T, Pang G, et al. Spinal myxomas: review of a rare entity. *J Surg Case Rep*. 2022;2022(5):rjac221. doi:10.1093/jscr/rjac221
12. Tataryn Z, Tracy J, Tsang C, Wu J, Heilman CB, Wein RO. Intramuscular myxoma of the cervical paraspinal musculature: case report and review of the literature. *Am J Otolaryngol*. 2015;36(2):273–276. doi:10.1016/j.amjoto.2014.10.010
13. Manoharan SRR, Shaw AB, Arnold CA, Farhadi HF. Infiltrative intramuscular myxoma of the cervical spine: a case report. *Spine J*. 2015;15(1):e1–4. doi:10.1016/j.spinee.2014.09.008
14. Ohla V, Ciarlini P, Goldsmith JD, Kasper EM. Cellular myxoma of the lumbar spine. *Surg Neurol Int*. 2013;4:82. doi:10.4103/2152-7806.113648
15. Rashid A, Abdul-Jabar HB, Karmani S, Rezajooi K, Casey ATH. Giant paravertebral myxoma. *Eur Spine J*. 2011;20(Suppl 2):S138–S142. doi:10.1007/s00586-010-1442-6
16. Stinchcombe S. Intramuscular myxoma of the paraspinal musculature. *J Med Cases*. 2010. doi:10.4021/jmc37w
17. Taggarshe D, Raheja S, Yoo S, Mittal V. Intramuscular myxoma: a rare back mass. *Am Surg*. 2010;76(11):1303–1304. doi:10.1177/000313481007601137
18. Ishoo E. Intramuscular myxoma presenting as a rare posterior neck mass in a young child. *Case Report and Literature Review Arch Otolaryngol Head Neck Surg*. 2007;133(4):398. doi:10.1001/archotol.133.4.398
19. Crankson SJ, Namshan M, Mane K, Bamefleh H. Intramuscular myxoma: a rare neck mass in a child. *Ped Radiol*. 2002;32(2):120–122. doi:10.1007/s00247-001-0603-5
20. Guppy KH, Wagner F, Tawk R, Gallagher L. Intramuscular myxoma causing lumbar radiculopathy: case report and review of the literature. *J Neurosurg Spine*. 2001;95(2):260–263. doi:10.3171/spi.2001.95.2.0260
21. Liguoro D, Viejo-Fuertes D, Vital A, San Galli F, Dautheribes M, Guerin G. Intramuscular myxoma. A case of myxoma of the spinal erector muscle. *Neurochirurgie*. 1999;45(1):54–57.
22. Kamoun N, Zouari M, Siala M, et al. Intramuscular myxoma. apropos of two cases. *Rev Chir Orthop Reparatrice Appar Mot*. 1997;83(3):278–282.
23. Shugar JMA, Som PM, Schaeffer BT, Meyers RJ. Intramuscular head and neck myxoma: report of a case and review of the literature. *Laryngoscope*. 1987;97(1):105–107. doi:10.1288/00005537-198701000-00021
24. Bell WO, Gill A, Babiak T, Patterson RH. Epidural myxoma causing compression of the cauda equina: a case report. *Neurosurgery*. 1983;12(3):325–326. doi:10.1227/00006123-198303000-00014
25. Tahmouresie A, Farmer PM, Stokes N. Paraspinal myxoma with spinal cord compression. case report. *J Neurosurg*. 1981;54(4):542–544. doi:10.3171/jns.1981.54.4.0542
26. Feldman PS. A comparative study including ultrastructure of intramuscular myxoma and myxoid liposarcoma. *Cancer*. 1979;43(2):512–525. doi:10.1002/1097-0142(197902)43:23.0.CO;2-H
27. Murphey MD, McRae GA, Fanburg-Smith JC, Temple HT, Levine AM, Aboulafia AJ. Imaging of soft-tissue myxoma with emphasis on CT and MR and comparison of radiologic and pathologic findings. *Radiology*. 2002;225(1):215–224. doi:10.1148/radiol.2251011627
28. El Aissaoui T, Lachkar A, Abdeljaouad N, Yacoubi H. Right adductor compartment intramuscular myxoma: a rare case report. *Int J Surg Case Rep*. 2024;116:109402. doi:10.1016/j.ijscr.2024.109402
29. Belykh EG, Zhao X, Cavallo C, et al. Laboratory evaluation of a robotic operative microscope - visualization platform for neurosurgery. *Cureus*. 2018;10(7):e3072. doi:10.7759/cureus.3072

30. Schebesch K-M, Brawanski A, Tamm ER, Kühnel TS, Höhne J. QEVO® - A new digital endoscopic microinspection tool - a cadaveric study and first clinical experiences (case series). *Surg Neurol Int.* 2019;10:46. doi:10.25259/SNI-45-2019

31. Tomlinson SB, Hendricks BK, Cohen-Gadol A. Single-surgeon in vivo experience with the zeiss QEVO microinspection tool: an analysis of its use for extending the reach of operative visualization. *World Neurosurg.* 2021;147:268–272. doi:10.1016/j.wneu.2020.12.036

32. Schebesch K-M, Doenitz C, Haj A, Höhne J, Schmidt NO. Application of the endoscopic micro-inspection tool QEVO® in the surgical treatment of anterior circulation aneurysms-a technical note and case series. *Front Surg.* 2020;7:602080. doi:10.3389/fsurg.2020.602080

33. Feigl GC, Staribacher D, Kuzmin D. Minimally invasive dorsal approach in the surgery of giant thoracic disk herniation: technical note and clinical case report. *World Neurosurg.* 2022;165:154–158. doi:10.1016/j.wneu.2022.06.097

Funding: The authors received no financial support for the research, authorship, and/or publication of this article.

Declaration of Conflicting Interests: The authors report no conflicts of interest in this work.

Author Contributions: All authors contributed to the manuscript preparation and approved the final version of the manuscript.

Corresponding Author: Luis Alberto Ortega-Porcayo, Centro Médico ABC, Carlos Fernández Graef 154, Santa Fe, Contadero, Cuajimalpa de Morelos, Mexico City, 05330, Mexico; opalberto@gmail.com

Copyright © 2025 ISASS. The IJSS is an open access journal following the Creative Commons Licensing Agreement CC BY-NC-ND. To learn more or order reprints, visit <http://ijssurgery.com>.